

Role of MRI in the Clinical Exigesis of Asymptomatic Medial Collateral Ligament Injurie

Razak MDK and Meena GL*

Department of Radiodiagnosis, SP Medical College, Bikaner, Rajasthan, India

*Corresponding author: Meena GL, Senior Professor, HOD, Department of Radiodiagnosis, SP Medical College, Bikaner, Rajasthan, India, Tel: +91 9461297699 E-mail: meenabkn@yahoo.co.in

Citation: ARazak MDK, Meena GL (2018) Role of MRI in the Clinical Exigesis of Asymptomatic Medial Collateral Ligament Injurie. J Arthritis Rheumatol Res 1(1): 103

Abstract

Objective: Magnetic resonance imaging (MRI) of medial collateral ligament (MCL) injury of the elbow was often observed in asymptomatic adolescent basketball players. We aimed to clarify the clinical interpretation of “asymptomatic MCL injury observed on MRI” by comparing MRI, ultrasonography (US), and physical findings.

Methods: Sixty-four asymptomatic adolescent basketball players (mean 11.2 years) were enrolled. A 1.5T MRI was used. MCL function was evaluated by measuring the opening of the ulnohumeral joint using US. Physical findings included MCL tenderness, the moving valgus test, and the Milking test. The correlation between MRI and US, and MRI and physical findings were analyzed.

Results: Thirty-four subjects (53.1%) showed MCL injury by MRI. The mean laterality of the ulnohumeral joint opening showed no significant difference ($P=0.16$) between the group with (0.29 ± 1.06 mm) and without (0.08 ± 0.96 mm) MCL injury on MRI. There was no correlation between MRI and physical findings except for a weak correlation between subjects with positive Milking test and MCL injury on MRI (ϕ coefficient=0.3, $P=0.02$).

Conclusion: Asymptomatic MCL injury on MRI had little correlation to ligament dysfunction. It might represent the transition period to MCL thickening called “adaptation”.

Keywords: Ligament; Imaging; Magnetic; Injuries; Elbow

Introduction

In India, the screening of elbow injury in adolescent basketball players is performed by ultrasonography (US) and palpation. Several studies have been published regarding the usefulness of these screening methods for early detection of injury [1-3]. Magnetic resonance imaging (MRI) produces the highest contrast resolution image compared with other medical imaging modalities [4-7]. However, the use of MRI for screening elbow injury is not feasible because of the high cost and difficulties in scheduling subjects for examination. Additionally, during MRI scanning, subjects are required to remain still within an enclosed space, which may be a source for discomfort to the adolescents. According to this report, there were no cases of osteochondritis dissecans or avulsion fractures of the medial epicondyle among the study subjects, which are both frequently encountered in the daily practice by orthopedists. On the contrary, the frequency of injury of the medial collateral ligament (MCL) itself, which does not frequently occur in adolescent players, was unexpectedly high at 41.9% (26/63) [8]. From these results, we wondered why the subjects showed no clinical symptoms despite evidence of MCL injury on MRI. The purpose of this study was to clarify the clinical interpretation of asymptomatic MCL injury of the elbow observed on MRI among adolescent basketball players by comparing the findings of MRI with those of standard clinical orthopedic examinations including palpation and US.

Materials and Methods

The relationship between MRI findings of the medial elbow and the width of the ulnohumeral joint space measured by US or physical examination findings was verified. The present study was approved by the Ethics Committee of our institution. We obtained written informed consent from the parents of the study participants.

Subjects

Sixty-four male basketball players with a mean age of 11.2 (range 9-13) years were enrolled in this study between May 2017 and January 2018. The subjects were active basketball players, defined as players who play basketball on a regular basis (active partici-

pation in the sport with a duration of 3 hours for six days in a week), who were asymptomatic at the time of the examination. To recruit the study subjects, we placed an advertisement in a local magazine and newspaper.

Ultrasound Imaging

One orthopedist with 10 years of experience as a specialist of sports medicine and with 8 years of experience performing US examinations performed the US examinations (LOGIQ P5 e Expert, GE Healthcare UK Ltd, England). A linear array probe was used at 7.75 MHz. In a sitting position, each subject's elbow was positioned at 30° flexion and 90° supination using a custom-made standardized instrumented device (Figure 1) [9-11]. For each subject, the width of the ulnohumeral joint at the level of the anterior band was evaluated. Resting and valgus stress were measured with 30 N of compression from the lateral side of the elbow using a hand-held dynamometer. These examinations were performed on both sides. The joint width was measured by the vertical distance between the most distal point of the medial trochlea and the ulnar coronoid using the 1-line method (Cleft between articulations) (Figure 2) [11,12]. The laterality of the joint space opening by valgus stress (laterality of the cleft between articulations) was calculated by subtracting between the no stress view and the stress view [9,10]. These two parameters assessed by US represent the ligament function.




Figure 1: Custom-made standardized instrumented device. The subjects' elbows were fixed at 30° flexion and 90° supination in a sitting position

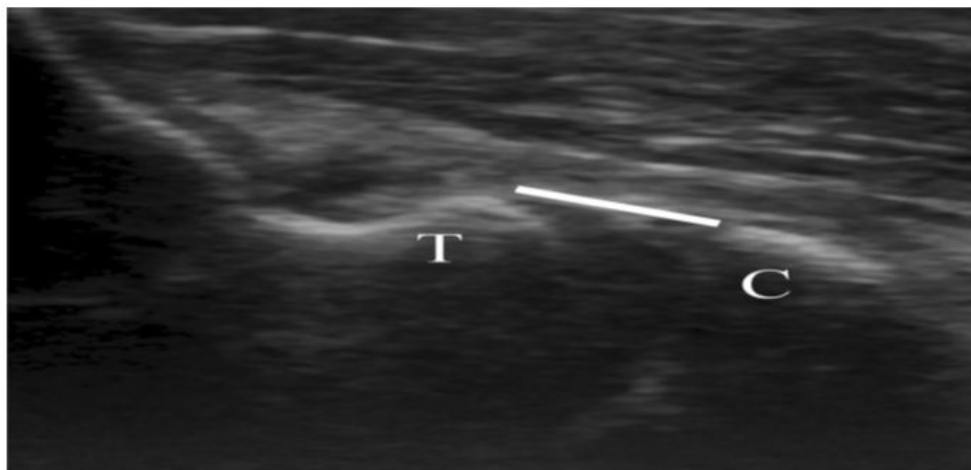


Figure 2: The joint space measured by ultrasonography. The white line represents the most distal point of the medial trochlea and measurement of the vertical distance across the joint to the ulnar coronoid using the 1-line method. C coronoid process, T trochlea

Physical Examinations

Physical examinations were performed by an orthopedic surgeon with 10 years of experience as a specialist of sports medicine. The following three examinations were performed in each subject: MCL tenderness, the moving valgus test, and the Milking test. Each examination was judged as positive or negative as previously reported [13]. Subjects with a positive result in at least one of three physical examinations were considered “positive” for MCL injury. In the moving valgus test, the subject is sitting and the involved elbow is flexed to 20°–30°. The examiner stands with the distal hand around the subject's wrist medially and the proximal hand over the patient's elbow joint laterally. In this position, with the subject's wrist stabilized, the examiner applies a valgus stress to the

elbow with the proximal hand. When the subject feels pain on the medial aspect of the elbow, it is considered a positive finding. In the Milking test, the subject is seated with the forearm fully supinated. The thumb is grasped and a valgus stress is applied to the elbow as the joint is passively flexed greater than 90°. Excessive opening of the elbow joint with valgus stress or pain on the medial aspect of elbow is considered as positive finding.

Magnetic Resonance Imaging

A 1.5T MRI (PHILIPS BRILLIANCE) extremity-dedicated MRI C-SCAN (Esaote Inc., Ferrara, Italy) was used in the present study. Scanning parameters were selected in order to accurately diagnose MCL injury [7,8]. In Sequence 1 (dominant side), gradient echo coronal images were obtained with the following parameters: TR, 500 ms; TE, 18 ms; slice thickness, 3 mm; gapless; matrix size, 256×192 mm; field of view (FOV), 180×180 mm; flip angle (FA), 75°; and scan time, 1 min 39 s. In Sequence 2 (dominant side), coronal images were obtained with the short TI inversion recovery technique using the following parameters: TR, 1000 ms; TE, 25 ms; inversion time, 80 ms; slice thickness, 3 mm; matrix size, 256×192; FOV, 180×180 mm; FA, 90°; and scan time, 3 min 35 s (Figure 3). In Sequence 3 (dominant side), gradient echo sagittal images were obtained using the following parameters: slice thickness, 4.5 mm; gapless; and the other parameters were the same as those in Sequence 1. After we scanned the abovementioned 3 sequences, we also scanned the elbow of the contra-dominant side to acquire a normal reference image as Sequence 4. The scanning parameters for Sequence 4 were the same as those in Sequence 1. These scan parameters are referred to in previously reported MRI screenings of the elbow using low-field extremity-dedicated MRI [8].

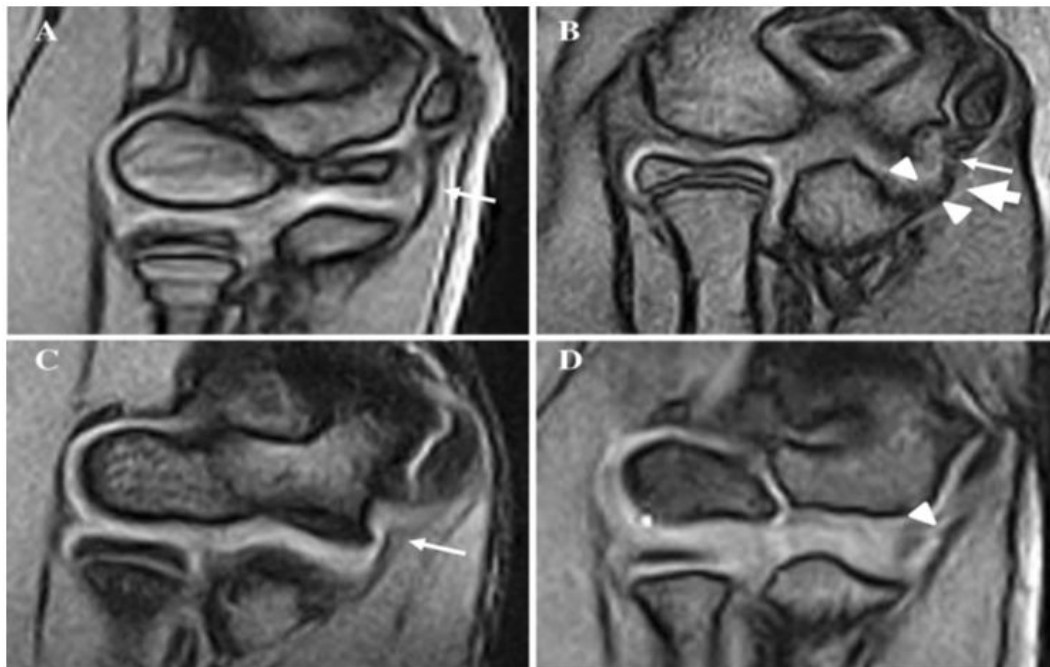


Figure 3: Magnetic resonance imaging (MRI) findings of the medial collateral ligament (MCL) (Sequence 1). (A) The subject was a 11-year old pitcher. Intact MRI of the MCL (arrow). (B) The subject was a 12-year-old pitcher. Criterion 1 (change in the size of the medial collateral ligament) (arrow head), Criterion 2 (morphological change of the entire medial collateral ligament) (arrow), and Criterion 4 (signal intensity change of the medial collateral ligament) (thin arrow) appeared. (C) The subject was a 13-year-old pitcher. Criterion 4 (signal intensity change of the medial collateral ligament) (thin arrow) appeared. (D) The subject was a 13-year-old infielder. Criterion 3 (morphological change of the margin of the medial collateral ligament) (arrow head) appeared

Diagnosis of MCL Injury by MRI

Image interpretation was performed independently during these elbow exams by a radiologist specializing in musculoskeletal imaging with 16 years' experience and one orthopedist specializing in sports medicine with 10 years' experience, using six evaluation criteria with a three level grading system. In this study, all MRI imaging were assessed by two interpreters who made comparisons with the contra-lateral elbows (Sequence 4). The six evaluation criteria were the following: (1) change in the size (short axis) of the MCL (enlargement or swelling) on Sequence 1; (2) morphological change of the entire MCL (bowing or elongation) on Sequence 1; (3) morphological change of the margin of the MCL (fluffing or spiculations) on Sequence 1; (4) signal intensity change of the MCL (high intensity in the MCL) on Sequence 1; (5) signal intensity change of the MCL (high intensity in the MCL) on Sequence 2; and (6) signal intensity change around the MCL (high intensity around the MCL) on Sequence 2. The grading system was: (I) apparently positive finding; (II) equivocal finding (impossible to judge whether true positive); (III) apparently negative finding. The final diagnosis of each finding was defined positive only when both interpreters judged the result to be positive (I). All the other judgment patterns (II or III) were regarded as negative. When at least one criterion was positive, we assessed the subject as having an MCL injury (Figure 3). These evaluation criteria are also referred previous study [8].

Statistical Analysis

The width of the ulnohumeral joint space (cleft between articulations) was compared between subjects with MCL tear on MRI and subjects without MCL tear by using a *t* test. The differences of the bilateral valgus stress joint space opening (laterality of the cleft between articulations) were also compared between subjects with an MCL tear on MRI and subjects without an MCL tear by using a *t* test. Categorical data including MRI findings and physical findings were analyzed with the χ^2 test and Fisher exact test. The relationship between MRI findings and physical findings was evaluated using the ϕ coefficient value. The results were considered statistically significant if the *P* value was <0.05 and the correlation was evaluated by Guilford's rule of thumb [14]. All analyses were performed using SPSS version 22 (IBM Corp., Armonk, NY, USA). Moreover, as the diagnosis of MCL injuries were based on the six subjective criteria including change in size, morphology and signal intensity change of the ligament, the inter-interpreter reliability was assessed by all six criterion using kappa analysis.

Blind Interpretation Tests

After we completed all analyses, we investigated the possibility of interpretation bias of this study method by blind interpretation tests. At first, two (one radiologist and one orthopedist as described above) interpreters performed blind interpretation. A radio technologist displayed the MRI scan of the elbow randomly with no other information including name, age, or side of dominant or contra-dominant elbow on the operator console. All left elbow images were displayed reversed just like the right elbow image. The radio technologist displayed all these 124 MRI scans of the dominant and contra-dominant elbows one after the other for the two interpreters to evaluate. The interpreters separately evaluated all of these images using the six criteria for each image. This interpretation was regarded as 'blind interpretation.' The method performed in the original evaluation was regarded as '(laterality) comparative interpretation.' We analyzed the statistical difference induced by the blind interpretation and comparative interpretation in each interpreter by kappa analysis. Namely, we analyzed the repeatability between blind interpretation and comparative interpretation in the same interpreter only on the dominant elbow (64 images). Next, we also analyzed whether there were any significant differences between the number of positive findings and that of negative findings between the dominant and contra-dominant elbow using the six criteria with the blind interpretation method using the χ^2 test in each interpreter.

Results

All 64 subjects (100%) successfully completed the screening MRI examination with no case showing motion artifacts that prevented proper diagnosis. Thirty-four subjects (53.1%) were diagnosed as having an MCL injury by MRI. Seventeen (26.6%), 6 (9.4%), 10 (10.9%), 21 (32.8%), 1 (0.02%), and 6 (9.4%) subjects fulfilled Criterion 1, Criterion 2, Criterion 3, Criterion 4, Criterion 5, and Criterion 6, respectively. Some subjects fulfilled more than one criterion. The results of the number of positive subjects, assessment of the inter-interpreter reliability, and the reproducibility of each interpreter for each criterion are summarized in (Table 1). The mean \pm SD width of the cleft between the articulations was 0.68 \pm 0.93 mm on the dominant side, and 0.56 \pm 0.66 mm on the contra-dominant side, with no statistically significant difference (*P*=0.36). The mean \pm SD laterality of the cleft between articulations was 0.29 \pm 1.06 mm in the subjects with MCL injury on MRI, and 0.08 \pm 0.96 mm in the subjects without MCL injury on MRI, however the difference was not significant (*P*=0.16). Thirteen out of 64 subjects (20.3%) showed positive physical findings. Among the subjects with positive physical findings, a weak correlation was found between a positive Milking test and MCL injury on MRI (ϕ coefficient=0.3, *P*=0.02), while MCL injury on MRI was found to have no apparent correlation with a positive MCL tenderness (ϕ coefficient=0.2, *P*=0.13) and moving valgus test (ϕ coefficient=0.16, *P*=0.22). The correlations between the physical examination findings and detailed MRI findings (6 criteria) were also evaluated (Table 2). The Milking test showed a weak correlation with Criterion 1 (ϕ coefficient=0.27, *P*=0.048) and Criterion 4 (ϕ coefficient=0.39, *P*=0.004). MCL tenderness also showed a weak correlation with Criterion 2 (ϕ coefficient=0.26), Criterion 4 (ϕ coefficient=0.23), and Criterion 6 (ϕ coefficient=0.26); however, these results were not statistically significant.

MCL injury based on MRI	Actual number judged by positive by tv.ointerpreters Number of subjects	Inter-interpreter agreement	
		Agreement rate (%)	Kappa coefficient
1. Change in the size of the MCL	17	95.3	0.89
2. Morphology and change of the entire MCL	6	95.3	0.77
3. Morphology and change of the margin of the MCL	7	90.6	0.64
4. Signal intensity change of the MCL on sequence	21	92.1	0.83
5. Signal intensity change of the MCL on Sequence		98.4	0.66
6. Signal intensity change around the MCL	6	93.8	0.71

Table 1: The number of positive MRI findings, inter-interpreter agreement and reproducibility of each interpreter with agreement rate and kappa coefficient for each finding of the below joint

Interpreter 1 was a radiologist specialized in musculoskeletal imaging with 16 years' experience. Interpreter 2 was an orthopedic surgeon specialized in sports medicine with 10 years' experience. MCL Medial Collateral Ligament. MRI magnetic resonance imaging

As for the blind interpretation tests, the percentages of repeatability and kappa values between the blind interpretation and

comparative interpretation for interpreter 1 (radiologist) were 98.4% (0.96 of kappa coefficient), 93.8% (0.74), 93.8% (0.74), 96.9% (0.93), 100% (1.00), and 96.9% (0.84) for criteria 1, 2, 3, 4, 5, and 6 respectively. Those for interpreter 2 (orthopedist), the values were 93.8% (0.88), 95.3% (0.88), 89.0% (0.62), 93.8% (0.87), 98.4% (0.66), and 100% (1.00), respectively. Most criterion of interpreter 1 and 2 showed a higher number of positive findings in the dominant elbow than that in the contra-dominant elbow with statistical significance.

MCL injury based on MRI	MCL tenderness		Moving valgus test		Milking test	
	P value	Φ coefficient	P value	Φ coefficient	P value	Φ coefficient
	0.13	0.2	0.22	0.16	0.02*	0.3
1. Change in the size of the MCL	0.19	0.17	0.11	0.22	0.048*	0.27*
2. Morphological change of the entire MCL	0.09*	0.26*	0.6	-0.094	0.38	-0.13
3. Morphological change of the margin of the MCL	0.49	-0.11	0.45	0.09	0.5	0.15
4. Signal intensity change of the MCL on sequence	0.08*	0.23*	0.19	0.17	0.04*	0.39*
5. Signal intensity change of the MCL on sequence		N/A		N/A		N/A
6. Signal intensity change around the MCL	0.09*	0.26*	0.4	0.11		0.18

Table 2: The relationship between MRI findings and physical findings evaluated by the Φ coefficient value. Results were considered statistically significant if the P value was <0.05, and the correlation was evaluated by Gulford's rule of thumb. * weak correlation 0.2 Φ coefficient 0.4

Discussion

Many studies have reported on the diagnostic usefulness of musculoskeletal (MSK) territories evaluated by low magnetic field extremity-dedicated MRI machine for diagnosing small joint injuries. It has been well-discussed in the shoulder, knee and even a very small joint such as a digit [15-18, 19,20]. Although no studies have reported on a direct comparison study in an elbow joint between high field and low field, Ghazinoor *et al.* reported that elbow images on extremity-dedicated low magnetic field MRI were also of great diagnostic value in their review article about low-field MSK MRI [21]. In general, signal-to-noise ratio (SNR) of MRI depends on the strength of its magnetic field. On the contrary, the solenoid coil used in the vertical magnetic field produces approximately triple coil sensitivity compared to the birdcage or saddle-type coil used in the horizontal magnetic field [22]. Moreover, miniaturization of solenoid coil can be also possible to elevate the filling factor markedly because its coil size fits closely with the elbow joint. In addition, C-scan comprised the quadrature detection coil. Although we used the low field scanner, these factors could produce sufficiently high SNRs and image qualities for diagnosis. Actually, a previous report of elbow screening using 0.2 T extremity-dedicated MRI showed high agreement rates of six diagnostic criteria ranging from 72.6 to 96.8%, with kappa coefficients ranging from 0.73 to 0.91 for MCL injury of the elbow in adolescent basketball players by interpretation of two diagnostic radiology specialists [8]. Although one radiologist and one orthopedist performed the interpretations in this study, this study also showed sufficiently high agreement rate in the same six diagnostic criteria ranging from 90.6 to 98.4%, with kappa coefficients ranging from 0.64 to 0.89 (Table 1). Unlike the previous report, in this study, interpretations were performed using MRI images of the contradominant elbow (Sequence 4). Namely, two interpreters had the same absolute comparison image for each subject, and they only had to identify the difference from the contra-dominant side to find the abnormalities. On the contrary, the results of comparison between blind interpretation and comparative interpretation the latter of which has been performed for actual diagnosis by MRI showed sufficiently high repeatability and kappa value (0.74–1 in interpreter 1 and 0.61–1 in interpreter 2). Moreover, blind interpretation tended to result in a higher number of positive findings in the dominant elbow compared with the contra-dominant elbow with statistical significance ($P < 0.01$) in most criteria in both interpreters. We consider that blind interpretation tests suggested that there was little or no interpretation bias, namely over diagnosis, in this study even if subjects had no clinical symptom. In the present study, when comparing the subjects with no abnormal MRI findings and those with asymptomatic MCL injury diagnosed on MRI, there were no statistically significant differences in ligament function including the cleft between articulations and the laterality of the cleft between articulations assessed by US. This means that most adolescent basketball players who have an asymptomatic MCL injury of the elbow on MRI also have normal ligament function. Asymptomatic MCL injury of the elbow might be caused by overuse, which is a slight but repetitive type of injury [4, 23-27]. Therefore, it is possible that subjects show no apparent clinical symptoms and normal ligament function because the extent of each single stress is very minor. However, although each single stress is very minor, repetitive stimulation can cause structural changes in the MCL. In this situation, subjects might not notice this gradual damage to their elbow, and thus, remain asymptomatic for a long period of time. For these reasons, we consider that MRI findings of MCL injury of the elbow can be present despite no apparent clinical symptoms and normal ligament function in active adolescent basketball players.

Conclusion

In adolescent basketball players, MCL injury of the elbow on MRI was not correlated with ligament dysfunction estimated by US. Furthermore, there was a weak correlation between the MRI findings and physical examination. Based on these findings, we hypothesized that asymptomatic MCL injury of the elbow observed on MRI might represent a broad spectrum of injuries charac-

terized by a transition period in which changes related to adaptation occur, followed by a pre-injury period before symptomatic injury. Improving the current knowledge of asymptomatic MCL injuries in adolescent basketball players may help in the prevention of severe basketball elbow injury. To validate our hypothesis, further longer-term follow-up with MRI is needed.

References

1. Matsuura T, Suzue N, Kashiwaguchi S, Arisawa K, Yasui N (2013) Elbow injuries in youth basketball players without prior elbow pain: a 1-year prospective study. *Orthop J Sports Med* 1: 2325967113509948.
2. Harada M, Takahara M, Mura N, Sasaki J, Ito T, et al. (2010) Risk factors for elbow injuries among young basketball players. *J Shoulder Elbow Surg* 19: 502-7.
3. Nagamoto H, Yamamoto N, Kurokawa D, Takahashi H, Muraki T, et al. (2015) Evaluation of the thickness of the medial ulnar collateral ligament in junior high and high school basketball players. *J Med Ultrason* 42: 395-400.
4. Del Grande F, Aro M, Farahani SJ, Wilckens J, Cosgarea A, et al. (2015) Three-Tesla MR imaging of the elbow in nonsymptomatic professional basketball pitchers. *Skelet Radiol* 44: 115-23.
5. Mulligan SA, Schwartz ML, Broussard MF, Andrews JR (2000) Heterotopic calcification and tears of the ulnar collateral ligament: radiographic and MR imaging findings. *AJR Am J Roentgenol* 175: 1099-102.
6. Hurd WJ, Eby S, Kaufman KR, Murthy NS (2011) Magnetic resonance imaging of the throwing elbow in the uninjured, high schoolaged basketball pitcher. *Am J Sports Med* 39: 722-8.
7. Ouellette H, Bredella M, Labis J, Palmer WE, Torriani M (2008) MR imaging of the elbow in basketball pitchers. *Skelet Radiol* 37: 115-21.
8. Okamoto Y, Maehara K, Kanahori T, Hiyama T, Kawamura T, et al. (2016) Incidence of elbow injuries in adolescent basketball players: screening by a low field magnetic resonance imaging system specialized for small joints. *Jpn J Radiol* 34: 300-6.
9. Bruce JR, Hess R, Joyner P, Andrews JR (2004) How much valgus instability can be expected with ulnar collateral ligament (UCL) injuries? A review of 273 basketball players with UCL injuries. *J Shoulder Elbow Surg* 23: 1521-6.
10. Ciccotti MG, Atanda A, Nazarian LN, Dodson CC, Holmes L, et al. (2004) Stress sonography of the ulnar collateral ligament of the elbow in professional basketball pitchers: a 10-year study. *Am J Sports Med* 42: 544-51.
11. Nazarian LN, McShane JM, Ciccotti MG, O'Kane PL, Harwood MI (2003) Dynamic US of the anterior band of the ulnar collateral ligament of the elbow in asymptomatic major league basketball pitchers. *Radiology* 227: 149-54.
12. Marshall NE, Keller RA, Van Holsbeeck M, Moutzouros V (2015) Ulnar collateral ligament and elbow adaptations in high school basketball pitchers. *Sports Health* 7: 484-8.
13. Creighton RA, Bach BR, Bush-Joseph CA (2006) Evaluation of the medial elbow in the throwing athlete. *Am J Orthop (Belle Mead NJ)* 35: 266-9.
14. Guilford JP (1956) *Fundamental statistics in psychology and education*. McGraw-Hill, New York, USA.
15. Shellock FG, Bert JM, Fritts HM, Gundry CR, Easton R, et al. (2001) Evaluation of the rotator cuff and glenoid labrum using a 0.2-Tesla extremity magnetic resonance (MR) system: MR results compared to surgical findings. *J Magn Reson Imaging* 14: 763-70.
16. Zlatkin MB, Hoffman C, Shellock FG (2004) Assessment of the rotator cuff and glenoid labrum using an extremity MR system: MR results compared to surgical findings from a multi-center study. *J Magn Reson Imaging* 19: 623-31.
17. Cevikol C, Karaali K, Esen G, Apaydin A, Ozenci M, et al. (2004) MR imaging of meniscal tears at low-field (0.35 T) and high-field (1.5 T) MR units. *Tani Girisim Radyol* 10: 316-9.
18. Cotten A, Delfaut E, Demondion X, Lapègue F, Boukhelifa M, et al. (2000) MR imaging of the knee at 0.2 and 1.5 T: correlation with surgery. *AJR Am J Roentgenol* 174: 1093-7.
19. Suzuki T, Ito S, Handa S, Kose K, Okamoto Y, et al. (2010) New low-field extremity MRI, compactScan: comparison with whole-body 1.5 T conventional MRI. *Mod Rheumatol* 20: 331-6.
20. Suzuki T, Ito S, Handa S, Kose K, Okamoto Y, et al. (2009) A new low-field extremity magnetic resonance imaging and proposed compact MRI score: evaluation of anti-tumor necrosis factor biologics on rheumatoid arthritis. *Mod Rheumatol* 19: 358-65.
21. Ghazinoor S, Crues JV, Crowley C (2007) Low-field musculoskeletal MRI. *J Magn Reson Imaging* 25: 234-44.
22. Hoult DI, Richards RE (1976) The signal-to-noise ratio of the nuclear magnetic resonance experiment. *J Magn Reson* 24: 71-85.
23. Atanda A, Buckley PS, Hammoud S, Cohen SB, Nazarian LN, et al. (2015) Early anatomic changes of the ulnar collateral ligament identified by stress ultrasound of the elbow in young professional basketball pitchers. *Am J Sports Med* 43: 2943-9.
24. Chen FS, Rokito AS, Jobe FW (2001) Medial elbow problems in the overhead-throwing athlete. *J Am Acad Orthop Surg* 9: 99-113.
25. Wilson FD, Andrews JR, Blackburn TA, McCluskey G (1983) Valgus extension overload in the pitching elbow. *Am J Sports Med* 11: 83-8.
26. Schreiber JJ, Potter HG, Warren RF, Hotchkiss RN, Daluiski A (2014) Magnetic resonance imaging findings in acute elbow dislocation: insight into mechanism. *J Hand Surg Am* 9: 119-205.
27. Ellenbecker TS, Mattalino AJ, Elam EA, Caplinger RA (1998) Medial elbow joint laxity in professional basketball pitchers. A bilateral comparison using stress radiography. *Am J Sports Med* 26: 420-4.
28. Schein A, Matcuk G, Patel D, Gottsegen CJ, Hartshorn T, et al. (2012) Structure and function, injury, pathology, and treatment of the medial collateral ligament of the knee. *Emerg Radiol* 19: 489-98.
29. De Maeseneer M, Shahabpour M, Pouders C (2010) MRI spectrum of medial collateral ligament injuries and pitfalls in diagnosis. *JBR-BTR* 93: 97-103.
30. Mirowitz SA, Shu HH (1994) MR imaging evaluation of knee collateral ligaments and related injuries: comparison of T1-weighted, T2-weighted, and fat-saturated T2-weighted sequences-correlation with clinical findings. *J Magn Reson Imaging* 4: 725-32.
31. Yoshioka T, Kanamori A, Washio T, Aoto K, Uemura K, et al. (2013) The effects of plasma rich in growth factors (PRGFEndoret) on healing of medial collateral ligament of the knee. *Knee Surg Sports Traumatol Arthrosc* 21: 1763-9.
32. Frank C, McDonald D, Shrive N (1997) Collagen fibril diameters in the rabbit medial collateral ligament scar: a longer term assessment. *Connect Tissue Res* 36: 261-9.

33. Kooima CL, Anderson K, Craig JV, Teeter DM, van Holsbeeck M (2004) Evidence of subclinical medial collateral ligament injury and posteromedial impingement in professional basketball players. Am J Sports Med 32: 1602-6.

Submit your next manuscript to Annex Publishers and benefit from:

- ▶ Easy online submission process
- ▶ Rapid peer review process
- ▶ Online article availability soon after acceptance for Publication
- ▶ Open access: articles available free online
- ▶ More accessibility of the articles to the readers/researchers within the field
- ▶ Better discount on subsequent article submission

Submit your manuscript at
<http://www.annexpublishers.com/paper-submission.php>