

# Primary Adenoid Cystic Carcinoma of the Mandibular Bone, an Extremely Rare Case Report

Lyoubi H\*, Lekhbal A, Wydadi O, Lyoubi M, Abada RA, Rouadi S, Roubal M and Mahtar M

ENT and Head and Neck Surgery, Hospital, Ibn Rochd Teaching Hospital, Casablanca, Morocco

\***Corresponding author:** Lyoubi H, ENT and Head and Neck Surgery, Hospital, Ibn Rochd Teaching Hospital, Casablanca, Morocco, Tel: 00212666275716, E-mail: Hicham.lyoubi23@gmail.com

**Citation:** Lyoubi H, Lekhbal A, Wydadi O, Lyoubi M, Abada RA, et al. (2020) Primary Adenoid Cystic Carcinoma of the Mandibular Bone, an Extremely Rare Case Report. J Case Rep Stud 8(2): 205

**Received Date:** March 20, 2020 **Accepted Date:** August 26, 2020 **Published Date:** August 28, 2020

## Abstract

Adenoid cystic carcinoma (ACC) is a rare epithelial neoplasm, that may affect the salivary glands. It comprises 30% of epithelial minor salivary gland tumors. We present the case of a 56-year-old non-smoking woman with no significant medical history. The MRI finds a lesional process involving the right hemi mandible, the right buccal floor, which extends towards the region of the masticators and infiltrates the submandibular gland. A bone biopsy of the mandible under general anesthesia was performed, showing an adenoid cystic carcinoma. After announcing the diagnosis to the patient, she refused any treatment.

**Keywords:** Adenoid Cystic Carcinoma; Mandible; Magnetic Resonance Imaging

**List of abbreviations:** ACC: Adenoid Cystic Carcinoma; MRI: Magnetic Resonance Imaging

## Introduction

Adenoid cystic carcinoma (ACC) is a rare epithelial neoplasm, that may affect the salivary glands. It comprises 30% of epithelial minor salivary gland tumors [1].

Primary central salivary gland carcinomas of the mandible are uncommon, and its origin is still controversial.

The present case report is to describe an unusual case of primary ACC of the right mandible without any medical history. The radiological findings shows a lesional process involving the right hemi mandible, the right buccal floor. The biopsy was performed under general anesthesia confirms an adenoid cystic carcinoma. The patient refused any treatment.

## Case report

We present the case of a 56-year-old non-smoking woman with no significant medical history.

The onset of the disease dates back to a year by the appearance of right angular mandibular pain gradually increasing in intensity, and resistant to medical treatment, the patient's condition was complicated by a right juguale swelling with trismus initially treated as facial cellulitis without improvement.

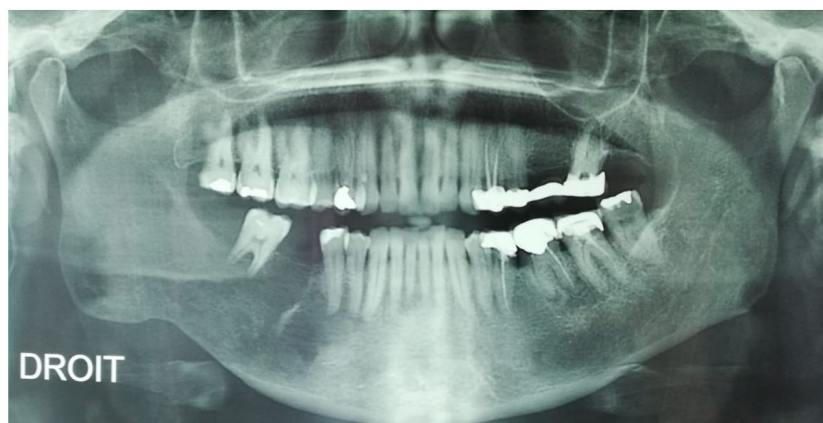On the radiological assessment, the dental panoramic X-ray finds an aspect of osteolysis of tooth 46 (Figure 1).

The CT scann shows an osteolysis and infiltration of the right soft tissues of the mandible with small collection of the right para pharyngeal region measuring 21 mm (Figure 2).

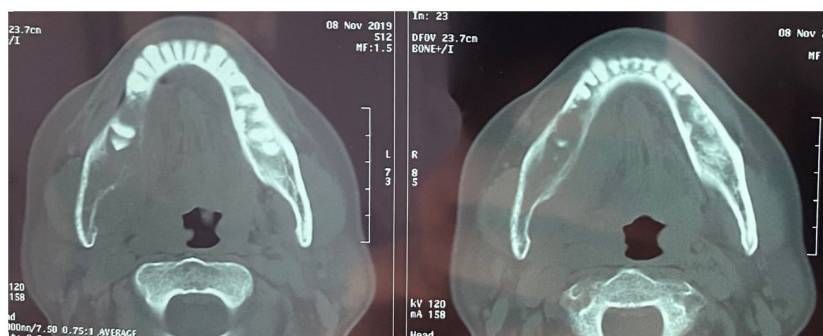The MRI finds a lesional process involving the right hemi mandible, the right buccal floor, measuring 61.2 x 37 mm and which extends towards the region of the masticators and infiltrates the submandibular gland, as well as vertebral osteolytic lesions of the C4 -C5-C6 (Figure 3).

A bone biopsy of the mandible under general anesthesia was performed, showing an adenoid cystic carcinoma.

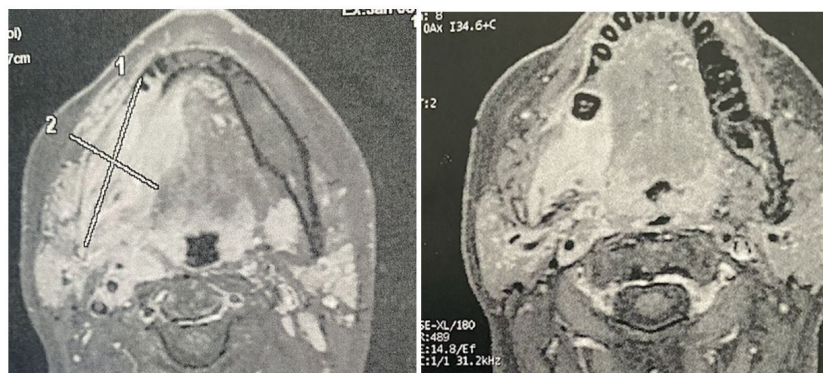
After announcing the diagnosis to the patient as well as the various therapeutic modalities, as surgery as well as radiotherapy, the patient refused treatment.



**Figure 1:** Panoramic X-ray showing osteolysis of the right mandible



**Figure 2:** CT scan showing an infiltration of the right mandible



**Figure 3:** MRI aspect of the bone process of the right mandible

## Discussion

ACC is a relatively uncommon tumor comprising about 1% of all head and neck malignancies and approximately 10% of all salivary gland tumors [2-4].

The palate is the most frequently affected site, followed by the tongue, buccal mucosa, lip, and floor of the mouth [5].

ACC is a slow-growing but highly invasive tumor, with high rates of recurrence and perineural spread [1,6,7].

Pathogenesis of central salivary gland tumors is unknown, but it is considered they originate from epithelial linings of cysts, particularly dentigerous cysts, or more probably from ectopic salivary gland tissue [8].

This lesion rarely affects the jaws [8].

ACC can occur in all age groups with high frequencies in the fifth and sixth decades of life, and a gender predilection was noted as an inconsistent feature in the literature [9].

ACC usually presents as a slowly growing, firm, unilobular mass, and pain is a common finding, occasionally occurring early in the course of the disease [6,10].

Clinically and radiographically they may mimic odontogenic cysts and tumors, and a final diagnosis can be obtained only after histological examination [11].

CT and MRI are important to delineate the extent, local invasion, and perineural spread of the tumor [12,13].

Strict diagnostic criteria have been established to confirm the central origin of salivary gland tumors involving the mandible:

1. Radiographic evidence of osteolysis;
2. Presence of intact cortical plates;
3. Absence of primary lesions within the salivary glands; and
4. Histological confirmation [11,14].

## Conclusion

We have described a rare case of a primary bone ACC of the mandible, this case was extremely rare in terms of the site of origin and invasion pattern.

CT and MRI are important to delineate the extent, local invasion, and perineural spread of the tumor.

## Acknowledgement

We like to acknowledge the patient and his relatives for accepting their case to be published. The study was funded by the authors themselves.

## Conflicts of Interests

The authors declare no conflicts of interests.

## References

1. Fujita M, Yanagi Y, Cortes ARG, Arita ES, Onoda T, et al. (2018) A case of sublingual adenoid cystic carcinoma involving the mandible presenting as a "skip lesion". *Oral Radiology* 34: 281-7.
2. Coca-Pelaz A, Rodrigo JP, Bradley PJ, Vander Poorten V, Triantafyllou A, et al. (2015) Adenoid cystic carcinoma of the head and neck-an update. *Oral Oncol* 51: 652-61.
3. Agarwal JP, Jain S, Gupta T, Tiwari M, Laskar SG, et al. (2008) Intraoral adenoid cystic carcinoma: prognostic factors and outcome. *Oral Oncol* 44: 986-93.
4. Samant S, van den Brekel MW, Kies MS, Wan J, Robbins KT, et al. (2012) Concurrent chemoradiation for adenoid cystic carcinoma of the head and neck. *Head Neck* 34: 1263-8.
5. Barnes L, Eveson JW, Reichart P, Sidransky D (2005) *Pathology and Genetics of Head and Neck Tumours*. World Health Organization classification of tumours, IARC Publications.
6. Gondivkar SM, Gadgil AR, Chole R, Parikh RV (2011) Adenoid cystic carcinoma: a rare clinical entity and literature review. *Oral Oncol* 47: 231-6.
7. Pushpanjali M, Sujata DN, Subramanyam SB, Jyothsna M (2014) Adenoid cystic carcinoma: an unusual presentation. *J Oral Maxillofac Pathol* 18: 286-90.
8. Brookstone MS, Huvos AG (1992) Central salivary gland tumors of the maxilla and mandible: a clinicopathologic study of 11 cases with an analysis of the literature. *J Oral Maxillofac Surg* 50: 229-36.
9. Jaso J, Malhotra R (2011) Adenoid cystic carcinoma. *Arch Pathol Lab Med* 135: 511-5.
10. Kumar VS, Prathi VS, Manne RK, Beeraka S, Natarajan K (2013) Adenoid cystic carcinoma of sublingual salivary gland obstructing the submandibular salivary gland duct. *J Clin Imaging Sci* 3: 10.
11. Martinez-Madrigal F, Pineda-Daboin K, Casiraghi O, Luna MA, et al. (2000) Salivary gland tumors of the mandible. *Ann Diagn Pathol* 4: 347-53.
12. Burke CJ, Thomas RH, Howlett D (2011) Imaging the major salivary glands. *Br J Oral Maxillofac Surg* 49: 261-9.
13. Ren ZH, Chickooree D, Liu JB, Wu HJ (2014) Primary intraosseous ACC of mandible of possible salivary origin: a rare clinical entity. *Int J Surg Case Rep* 5: 222-5.
14. Al-Sukhun J, Lindqvist C, Hietanen J, Leivo I, Penttilä H (2006) Central adenoid cystic carcinoma of the mandible: case report and literature review of 16 cases. *Oral Surg Oral Med Oral Pathol Oral Radiol Endod* 101: 304-8.

Submit your next manuscript to Annex Publishers and benefit from:

- ▶ Easy online submission process
- ▶ Rapid peer review process
- ▶ Online article availability soon after acceptance for Publication
- ▶ Open access: articles available free online
- ▶ More accessibility of the articles to the readers/researchers within the field
- ▶ Better discount on subsequent article submission

Submit your manuscript at

<http://www.annepublishers.com/paper-submission.php>