

Juvenile Ossifying Fibroma - WHO Type

Rathore AS¹, Ahuja P¹ and Chhina S²

¹Department of Oral and Maxillofacial pathology, I.T.S Dental College, Hospital & Research Centre, Greater Noida, India

²Department of Periodontics, I.T.S Dental College, Hospital & Research Centre, Greater Noida, India

***Corresponding author:** Rathore AS, Professor, Department of Oral and Maxillofacial pathology, I.T.S Dental College, Hospital & Research Centre, Greater Noida, (U.P)-201308, India, Tel: 91-120-2331082, Fax: 91-120-2331083, E-mail: drathoreajit@yahoo.com

Citation: Rathore AS, Ahuja P, Chhina S (2014) Juvenile Ossifying Fibroma - WHO Type. J Case Rep Stud 2(2): 202. doi: 10.15744/2348-9820.1.502

Received Date: April 18, 2014 **Accepted Date:** April 28, 2014 **Published Date:** April 30, 2014

Abstract

Juvenile ossifying fibroma is an uncommon clinical entity, its aggressive local behaviour and high recurrence rate mean that it is important to make an early diagnosis, apply the appropriate treatment and, especially, follow the patient up over the long term. In the current article we report a case of juvenile ossifying fibroma-WHO type in 12yr old patient which was clinical and histopathologically challenging as it was asymptomatic and at an unusual location.

Keywords: Juvenile ossifying fibroma; Fibro-osseous lesions; Ossifying fibroma

Introduction

Juvenile ossifying fibroma (JOF) term is used for a rare actively growing lesion that mainly affects individuals' younger than 15 years of the age [1]. This lesion behaves in an aggressive fashion, reaching massive proportions with extensive cortical expansion. Over time, lesions with this morphology have been variously described as juvenile ossifying fibroma [2], active juvenile ossifying fibroma [3], aggressive ossifying fibroma [4], reticular desmo-osteoblastoma [5] or active fibrous dysplasia [6]. This lesion most commonly involves the paranasal sinuses and periorbital bones, where it may cause exophthalmos, proptosis, sinusitis and nasal symptoms. This rare tumor behaves in a more aggressive fashion than does ossifying fibroma, may be mistaken as low grade osteosarcoma, which may alter the treatment.

Juvenile ossifying fibroma is a well defined clinical and histological entity that has been separated from other central fibro osseous lesions, including the cemento ossifying fibroma [4]. It is described in WHO classification [1] as "an actively growing lesion consists of a cell rich fibrous stroma, containing bands of cellular osteoid without osteoblastic rimming together with trabeculae of more typical woven bone. Small foci of giant cells may also be present, and in some parts there may be abundant osteoclasts related to woven bone. Usually no fibrous capsule can be demonstrated, but like the ossifying fibroma (and unlike fibrous dysplasia), the JOF is well demarcated from the surrounding bone".

In the jaw, JOF is considered to develop from undifferentiated cells of the periodontal ligament, usually in the premolar and molar region. The differential diagnosis with other fibro-osseous lesions of the jaw, such as cemento-ossifying fibroma, should be made [7].

Case report

A 12 year old female patient reported for the orthodontic treatment with no other complaints. Panoramic radiographic films were performed in accordance with standard procedure. A radiolucent lesion was identified in the mandibular anterior region and was presumed to be central giant cell granuloma. With this working diagnosis, the lesion was curetted and submitted for microscopic evaluation. The panoramic radiograph revealed a large radiolucent lesion in mandibular anterior region extending from right lateral incisor to left first premolar and extending to the lower border, with well-defined, smooth, corticated margins with no bony expansion (Figure 1).

Histological examination of hematoxylin and eosin stained slides (Figure 2) demonstrated a bony trabeculae of varying size in fibrocellular stroma. Trabeculae consist of lamellar and predominantly woven bone with osteoblastic rimming and few osteoid rims. Acellular to poorly cellular mineralized cementum like spheroids were also seen in plenty. Large areas of irregular calcified strands which in some areas coalesce to form aggregates were seen in hyalinised stromal areas (Figure 3). Cellular osteoid strands were also seen in loose fibroblastic stroma. Stromal degeneration and cystic spaces were also seen.

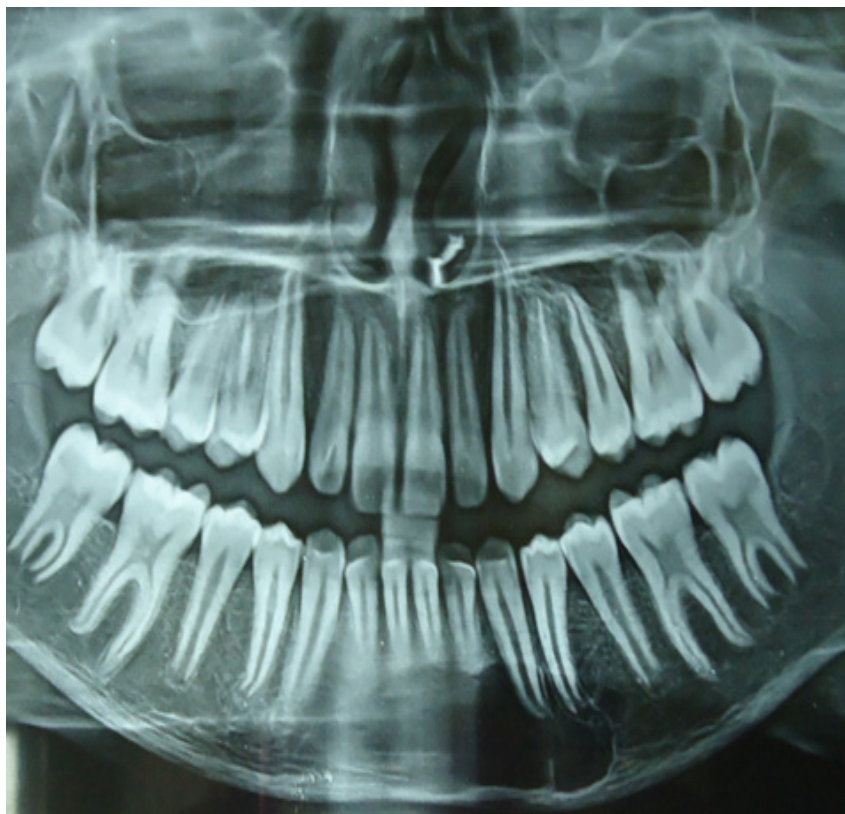

Figure 1: Pre- operative panoramic view showing a well defined unilocular radiolucency in the anterior of mandible extending from right lateral incisor to left first premolar and extending to the lower border, with well-defined, smooth, corticated margins with no bony expansion.

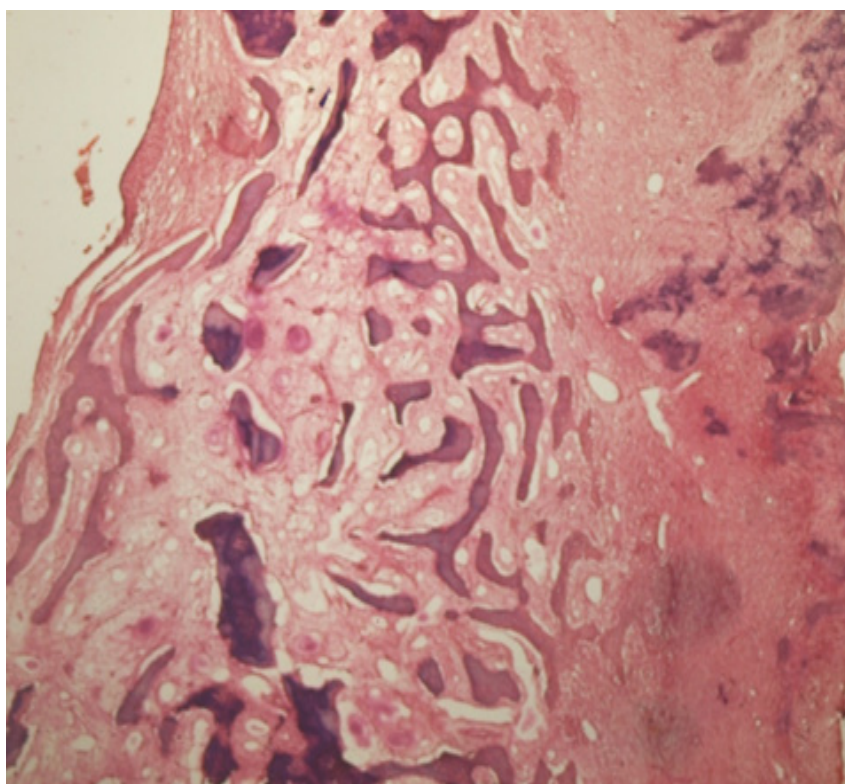


Figure2: Photomicrograph showing bony trabeculae of varying size in fibrocellular stroma. Large areas of irregular calcified strands which in some areas coalesce to form aggregates are seen in hyalinised stromal areas (H& E, x 100).

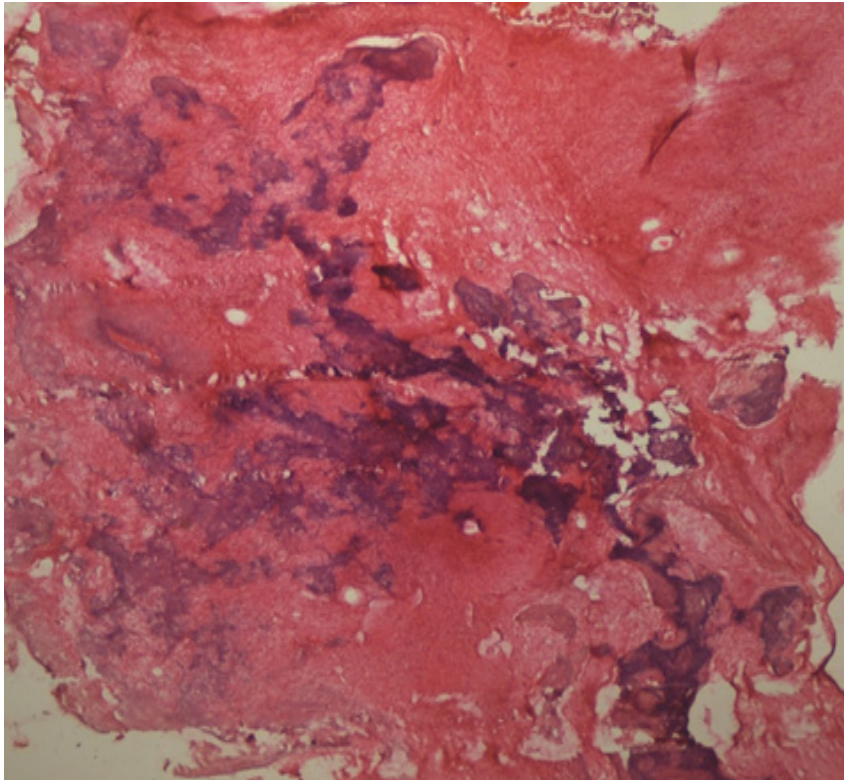


Figure 3: Photomicrograph showing Large areas of irregular calcified strands which in some areas coalesce to form aggregates are seen in hyalinised stromal areas (H&E, x 100).

Discussion

The JOF, as the name suggests, has its higher incidence in children and young adults [2,3]. Among the many classification systems for this lesion, the classification by Slootweg et al. [4] had divided JOF into two distinct groups, the JOF-WHO type and JOF-PO (psammoma-like ossicles) type, based primarily on the difference in the age of occurrence: the mean age of occurrence of JOF-WHO is 11.8 years and that of JOF-PO is 22.6 years [4]. El-Mofty [5] recent classification identified two categories, trabecular JOF (TJOF) and psammomatoid JOF (PJOF), based on histologic criteria. However, the two categories also have a distinct predilection for specific age-groups: the average age of occurrence of TJOF is 8½–12 years, whereas that of PJOF is 16–33 years [5].

Although JOF can occur anywhere in the skeleton, its highest incidence is in the facial bones, most commonly the maxilla [2,6]. One clinical feature that helps differentiate TJOF from PJOF is the site of involvement, with PJOF occurring mainly in the paranasal sinuses and TJOF occurring mainly in the maxilla [5]. Mandibular and extracranial involvement are rare [2].

Gender predilection has been a matter of controversy, with some authors claiming no predilection for either gender, whereas Johnson et al. found a higher incidence in females [2] and El-Mofty reported a male predilection [5].

JOF clinically manifests as an asymptomatic bony-hard swelling, the duration and extent of which may vary depending on the site and aggressiveness of the lesion. It can expand the involved bones, causing facial asymmetry. Depending on the site, symptoms such as pain, paresthesia, malocclusion, sinusitis, proptosis, etc., can also occur due to the swelling [6,8].

Radiographically it can be radiolucent, mixed, or radiopaque, like any fibroosseous lesion depending on the degree of calcification [4], with root displacement commonly and resorption rarely [4,6,8]. The lesion can cause expansion as well as perforation [5]. A 'ground-glass' appearance on radiographs has been reported which can be mistaken for fibrous dysplasia [5]. It usually has a concentric or centrifugal growth pattern, which can lead to an erroneous clinical diagnosis of cemento-ossifying fibroma [6,9].

The microscopic features of the lesion are distinctive and include a cell-rich fibrous stroma containing bands of cellular osteoid without osteoblastic lining, osteoid strands, and trabeculae of woven bone [4,5,9]. JOF-PO (psammoma-like ossicles) type is slightly more cellular than JOF-WHO type. Due to the resemblance of the psammoma-like ossicles seen in JOF-PO type to the cementicles in cemento-ossifying fibroma, it has been argued that JOF-PO a type of cemento-ossifying fibroma [5]. However, the marked cellularity of JOF-PO is in sharp contrast to the usually stroma-rich appearance of the latter group of lesions.

The aggressive nature of this entity, along with the reported high rates of recurrence (30–58%), [5,6] suggests that JOF should be treated like a locally aggressive neoplasm. Surgical resection, rather than conservative curettage, is therefore the preferred line of treatment [3,6].

Conclusion

Juvenile ossifying fibroma is an aggressive lesion which needs to be differentiated clinically and histologically from other fibro-osseous lesion so that appropriate treatment can be given in accordance with the age of the patient/ keeping in mind the young age of patient. It is very important to have minimum 5 year follow up.

References

1. Kramer IRH, Pindborg JJ, Shear M (1992) Histological typing of odontogenic tumors. International Histological Classification of Tumours, 2nd edn, World Health Organization. Springer-Verla, Berlin, Germany.
2. Johnson LC, Yousefi M, Vinh TN, Heffner DK, Hyams VJ, et al. (1991) Juvenile active ossifying fibroma: Its nature, dynamics and origin. *Acta Otolaryngol Suppl* 488: 1–40.
3. Zama M, Gallo S, Santecchia L, Bertozzi E, De Stefano C (2004) Juvenile active ossifying fibroma with massive involvement of the mandible. *Plast Reconstr Surg* 113: 970–4.
4. Slootweg PJ, Panders AK, Koopmans R, Nikkels PG (1994) Juvenile ossifying fibroma: An analysis of 33 cases with emphasis on histopathological aspects. *J Oral Pathol Med* 23: 385–8.
5. El-Mofty S (2002) Psammomatoid and trabecular juvenile ossifying fibroma of the craniofacial skeleton: Two distinct clinicopathologic entities. *Oral Surg Oral Med Oral Pathol Oral Radiol Endod* 93: 296–304.
6. Noffke CE (1998) Juvenile ossifying fibroma of the mandible: An 8 year radiological follow-up. *Dentomaxillofac Radiol* 27: 363–6.
7. Offiah C, Hall E (2005) Case of the month. The rapidly enlarging chin mass. *Br J Radiol* 78: 175–6.
8. Williams HK, Mangham C, Speight PM (2000) Juvenile ossifying fibroma: An analysis of eight cases and a comparison with other fibro-osseous lesions. *J Oral Pathol Med* 29: 13–8.
9. Knox GW, Roth M, Saleh H, Stiles W (1996) A unique temporal bone lesion resembling juvenile active ossifying myxoma. *Am J Otol* 17: 297–300.

Submit your manuscript to Annex Publishers and benefit from:

- ▶ Convenient online submission
- ▶ Rigorous peer review
- ▶ Immediate publication on acceptance
- ▶ Open access: articles freely available online
- ▶ High visibility within the field
- ▶ Better discount for your subsequent articles

Submit your manuscript at

<http://www.annepublishers.com/paper-submission.php>