

## Hemiagenesis of the Left Thyroid Lobe

Hoang TD<sup>1</sup>, Shwayhat AF<sup>1</sup> and Shakir MKM<sup>2</sup>

<sup>1</sup>Division of Endocrinology, Naval Medical Center San Diego, United States

<sup>2</sup>Division of Endocrinology, Walter Reed National Military Medical Center, Maryland, United States

\*Corresponding author: Hoang TD, Division of Endocrinology, Naval Medical Center San Diego, United States, E-mail: Thanh.Hoang@med.navy.mil

Citation: Hoang TD, Shwayhat AF, Shakir MKM (2015) Hemiagenesis of the Left Thyroid Lobe. J Case Rep Stud 3(1): 105. doi: 10.15744/2348-9820.2.405

Received Date: November 25, 2014 Accepted Date: February 03, 2015 Published Date: February 05, 2015

### Abstract

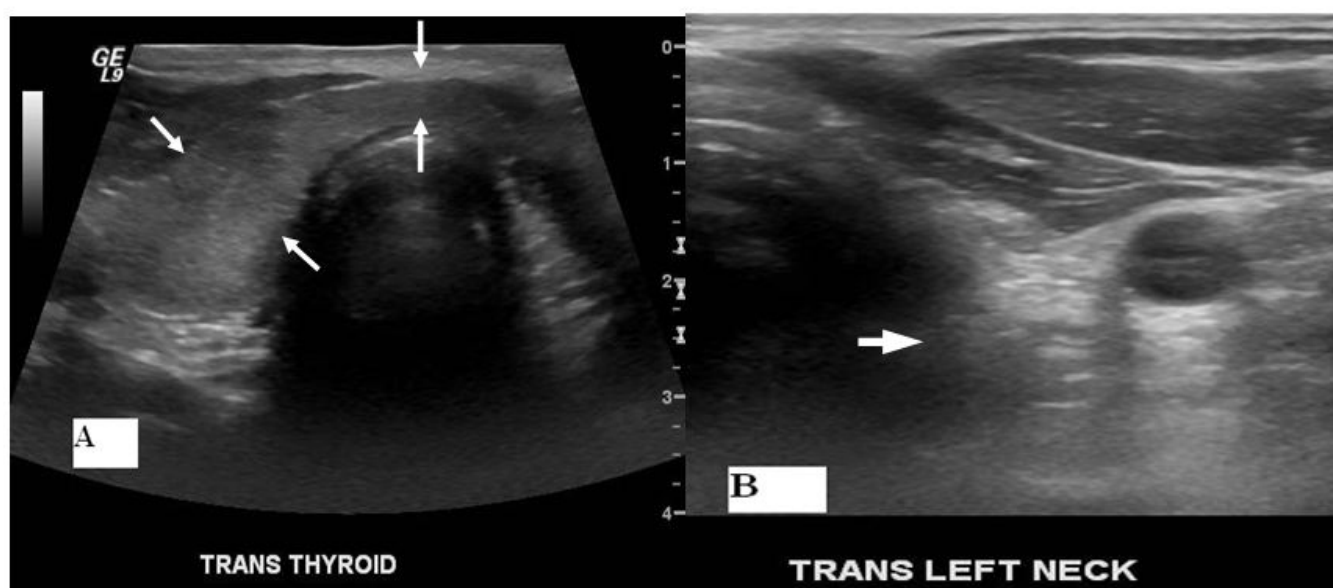
Thyroid hemiagenesis is a rare abnormality in which one thyroid lobe fails to develop. A careful clinical assessment, including thyroid function tests, thyroid ultrasonography and scintigraphy, plays an important role in diagnosis of thyroid hemiagenesis. We report a case of a 35 year-old man with an incidental finding of a left thyroid lobe hemiagenesis.

### Introduction

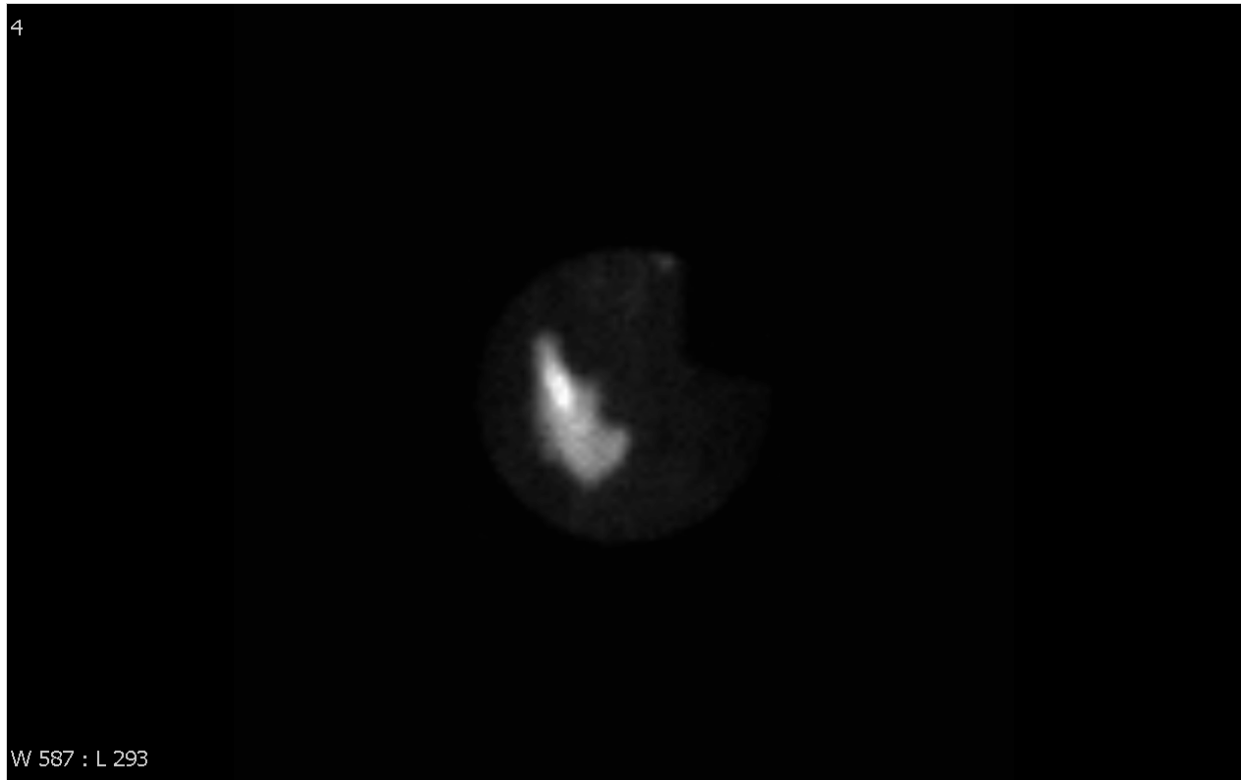
Thyroid hemiagenesis is a rare congenital abnormality in which one thyroid lobe with or without an isthmus fails to develop. Various thyroid diseases ranging from autoimmune thyroid disorders to thyroid cancer have been reported [1-12]. We report a case of hemiagenesis of the left thyroid lobe in a young man incidentally found during a routine physical examination.

### Case Presentation

A 35 year-old man was referred to endocrinology clinic for evaluation of a right thyroid nodule. He reported no hyper or hypothyroid symptoms. He did not take any iodine supplements and had no history of neck irradiation or surgery. There was no family history of thyroid disorders including thyroid cancer. Physical examination: HR 68 bpm, BP 131/77, no orbitopathy. Thyroid examination revealed a diffusely enlarged right thyroid lobe of 30 grams with no palpable nodules or cervical lymph nodes. The left thyroid lobe was not palpable and there was no surgical scar present. Deep tendon reflexes were normal. Laboratory results showed serum TSH 1.61 mcIU/mL (nl 0.55-4.78), free T4 1.24 ng/dL (nl 0.89-1.76), thyroid peroxidase antibodies 0 IU/ml (nl 0-29), thyroglobulin antibodies 0 IU/ml (nl 0-80). Thyroid ultrasound (Figure 1) revealed a normal right thyroid lobe (4.9 x 2.1 x 1.6 cm), a normal isthmus (0.3 cm in thickness), and dense connective tissue in the left thyroid bed with no thyroid tissue. Thyroid scintigraphy revealed a "Hockey Stick sign" (Figure 2). These findings are consistent with hemiagenesis of the left thyroid lobe.



**Figure 1:** A) Thyroid ultrasound, transverse view, shows a normal right thyroid lobe, 4.9 x 2.1 x 1.6 cm. The isthmus is normal in thickness, 0.3 cm (arrows) B) There is no thyroid tissue seen in the left thyroid bed. Left thyroid lobe is replaced by dense connective tissue (arrow)



**Figure 2:** Thyroid scintigraphy with Tc-99m pertechnetate shows the right thyroid lobe and isthmus in normal shape and position. There is an absence of radiotracer in the expected location of the left lobe (Hockey stick sign)

## Discussion

Hemiagenesis of the thyroid gland is a rare congenital abnormality in which one of the thyroid lobes, usually the left, with or without isthmus, fails to develop [1-3]. The prevalence of this disorder is approximately 0.05 – 0.16 %, more frequently found in women than in men, with hemiagenesis involving the left lobe in most of the patients [1-3,13-16]. Nearly 300 case reports have been described in the literature [1]. The exact pathogenesis of the agenesis is not known, although it is thought to result from failure of cells to migrate laterally during embryonic development. A genetic basis has been suggested because of the high occurrence rate of hemiagenesis among monozygotic twins, among sisters, or together with other thyroid malformations within one family [3,17]. Thyroid hemiagenesis usually does not cause clinical symptoms unless there is a thyroid hormone imbalance or possible thyroid disease. Compensatory hypertrophy of the remaining lobe occurs in most patients due to thyroid tissue overstimulation by TSH [3] and this was observed in our patient. Thyroid hemiagenesis can be associated with various thyroidal diseases, including benign adenoma, multinodular goiter, chronic thyroiditis, Grave's disease, thyroid carcinoma, or toxic adenoma [1-12]. Extrathyroidal lesions, such as parathyroid adenoma or hyperplasia, cervical thymic cysts, ectopic sublingual thyroid gland and thyroglossal duct cyst have also been reported [3,18-21]. On physical examination, thyroid hemiagenesis can be suspected in any patient with absence of palpable thyroid tissue and confirmed with thyroid scintigraphy or ultrasound. Thyroid scintigraphy can demonstrate absent thyroid tissue and also ectopic thyroid tissue. The characteristic "Hockey Stick sign" is usually observed in patients with thyroid hemiagenesis, as described in our case. Other conditions may mimic thyroid hemiagenesis (for nonvisualization of one thyroid lobe) such as a contralateral autonomous solitary thyroid nodule suppressing normal extranodular tissue; focal or unilateral subacute thyroiditis; primary or metastatic carcinoma; post-inflammatory atrophy of thyroid tissue in Hashimoto's disease, or infiltrative disorders [3]. Therefore, a proper clinical assessment, including thyroid function studies, thyroid ultrasound and scintigraphy are essential to establish the diagnosis. Computed tomography and magnetic resonance imaging can be used to confirm unilateral thyroid disease and true hemiagenesis, however, these techniques are expensive and time-consuming. It has been suggested that levothyroxine therapy can be used for subclinical hypothyroidism in patients with hemiagenesis [1,22].

In summary, we described a case of hemiagenesis of the left thyroid lobe in a young, biochemically euthyroid man. Ultrasonography and thyroid scintigraphy confirmed the diagnosis.

In conclusion, patients with thyroid hemiagenesis should have careful, long-term follow-up because of higher risk of developing thyroid pathologies.

## Disclaimer

The views expressed in this article are those of the authors and do not necessarily reflect the official policy or position of the Department of the Navy, Department of Defense, or the U.S. Government.

We certify that all individuals who qualify as authors have been listed; that each has participated in the conception and design of this work, the analysis of data, the writing of the document, and the approval of the submission of this version; that the document represents valid work; that if we used information derived from another source, we obtained all necessary approvals to use it and made appropriate acknowledgements in the document; and that each takes public responsibility for it.

## References

1. Ruchala M, Szczepanek E, Szaflarski W, Moczko J, Czarnywojtek A, et al. (2010) Increased risk of thyroid pathology in patients with thyroid hemiagenesis: results of a large cohort case-control study. *Eur J Endocrinol* 162: 153-60.
2. Berker D, Ozuguz U, Isik S, Aydin Y, Ates Tutuncu Y, et al. (2010) A report of ten patients with thyroid hemiagenesis: ultrasound screening in patients with thyroid disease. *Swiss Med Wkly* 140: 118-21.
3. Erhamamci S, Reyhan M, Avci E (2013) Thyroid Hemiagenesis with Hashimoto's Disease: A Case Report and Review of the Literature. *IJMMS* 1: 39-41.
4. Pizzini AM, Papi G, Corrado S, Carani C, Roti E (2005) Thyroid hemiagenesis and incidentally discovered papillary thyroid cancer: case report and review of the literature. *J Endocrinol Invest* 28: 66-71.
5. Shibutani Y, Inoue D, Koshiyama H, Mori T (1995) Thyroid hemiagenesis with subacute thyroiditis. *Thyroid* 5: 133-5.
6. Baldini M, Orsatti A, Cantalamessa L (2005) A singular case of Graves' disease in congenital thyroid hemiagenesis. *Horm Res* 63: 107-10.
7. Kocakusak A, Akinci M, Arikani S, Sunar H, Yucel AF, et al. (2004) Left thyroid lobe hemiagenesis with hyperthyroidism: report of a case. *Surg Today* 34: 437-9.
8. Karabay N, Comlekci A, Canda MS, Bayraktar F, Degirmenci B (2003) Thyroid Hemiagenesis with Multinodular Goiter: A Case Report and Review of the Literature. *Endocr J* 50: 409-13.
9. Ozgen AG, Saygili F, Kabalak T (2004) Thyroid hemiagenesis associated with Graves' disease and Graves' ophthalmopathy: Case report. *Thyroid* 14 : 75-7.
10. Sharma R, Mondal A, Popli M, Sahoo M, Malhotra N, et al. (2001) Hemiagenesis of the Thyroid Associated with Chronic Lymphocytic Thyroiditis. *Clin Nucl Med* 26: 506-8.
11. Mortimer PS, Tomlinson IW, Rosenthal FD (1981) Hemiaplasia of the thyroid with thyrotoxicosis. *J Clin Endocrinol Metab* 52: 152-5.
12. Burman KD, Adler RA, Wartofsky L (1975) Hemiagenesis of the thyroid gland. *Am J Med* 58: 143-6.
13. Gursoy A, Anil C, Unal AD, Demirer AN, Tutuncu NB, et al. (2008) Clinical and epidemiological characteristics of thyroid hemiagenesis: ultrasound screening in patients with thyroid disease and normal population. *Endocr* 33: 338-41.
14. Korpala-Szczyrska M, Kosiak W, Swieton D (2008) Prevalence of thyroid hemiagenesis in an asymptomatic schoolchildren population. *Thyroid* 18: 637-9.
15. Maiorana R, Carta A, Floriddia G, Leonardi D, Buscema M, et al. (2003) Thyroid hemiagenesis: prevalence in normal children and effect on thyroid function. *J Clin Endocrinol Metab* 88: 1534-6.
16. Shabana W, Delange F, Freson M, Osteaux M, De Schepper J (2000) Prevalence of thyroid hemiagenesis: ultrasound screening in normal children. *Eur J Pediatr* 159: 456-8.
17. Büyükdereli G, Guney IB, Kibar M, Kinaci C (2005) Thyroid hemiagenesis: a report of three cases and review of the literature. *Ann Nucl Med* 19: 147-50.
18. Woods RH, LouryM (1992) Thyroid hemiagenesis in a patient with parathyroid adenoma. *Otolaryng Head Neck Surg* 107: 469-71.
19. Duh QY, Ciulla TA, Clark OH (1994) Primary parathyroid hyperplasia associated with thyroid hemiagenesis and agenesis of the isthmus. *Surgery* 115: 257-63.
20. Hsu CY, Wang SJ (1994) Thyroid hemiagenesis accompanying an ectopic sublingual thyroid. *Clin Nucl Med* 19: 546.
21. Tsang SK, Maher J (1998) Thyroid hemiagenesis accompanying a thyroglossal duct cyst: a case report. *Clin Nucl Med* 23: 229-32.
22. Ruchala M, Szczepanek E, Szaflarski W, Moczko J, Czarnywojtek A (2010) A single thyroid lobe is usually sufficient to maintain euthyroidism albeit with significantly higher than usual TSH and FT3 levels. *Clin Thyroidology* 22: 10-12.

Submit your manuscript to Annex Publishers and benefit from:

- ▶ Convenient online submission
- ▶ Rigorous peer review
- ▶ Immediate publication on acceptance
- ▶ Open access: articles freely available online
- ▶ High visibility within the field
- ▶ Better discount for your subsequent articles

Submit your manuscript at

<http://www.annepublishers.com/paper-submission.php>