

Phase II Trial of Lower Dose Bevacizumab and Irinotecan in Relapsed High Grade Gliomas

Kairouz VF¹, Kamar FG², Dimassi H³ and Comair YG^{3,4}

¹Department of Medicine, University at Buffalo (SUNY), Buffalo, New York, USA

²Clemenceau Medical Center- Johns Hopkins International, Beirut Lebanon

³Lebanese American University, Medical School, Byblos, Lebanon

⁴University Medical Center Rizk Hospital – Lebanese American University Beirut Lebanon

*Corresponding author: Kamar FG, MD, City Center Bldg Suite 3, A. Avenue Nouvelle, 1076 Jounieh, Lebanon, E-mail: kamars@idm.net.lb

Citation: Kairouz VF, Kamar FG, Dimassi H, Comair YG (2014) Phase II Trial of Lower Dose Bevacizumab and Irinotecan in Relapsed High Grade Gliomas. *J Cancer Sci Clin Oncol* 2(1): 101. doi: 10.15744/2394-6520.1.201

Received Date: December 02, 2014 **Accepted Date:** March 04, 2015 **Published Date:** March 09, 2015

Abstract

Background: Relapsed high-grade gliomas (HGG) respond poorly to known chemotherapeutic agents with a median survival of 3 to 6 months. Several phase II trials of Bevacizumab for salvage therapy, reported excellent response rates. The optimal dose of Bevacizumab in GBM has not been defined to date. We performed a prospective phase II trial of bevacizumab using 5 mg/kg every 2 weeks.

Methods: This phase II study accrued 62 patients with recurrent Glioblastoma Multiforme (GBM) and high-grade glioma (HGG) between November 2006 and December 2009. All patients received 5 mg/kg of bevacizumab and 125 mg/m² of CPT11 every 2 weeks, after failing concurrent chemoradiation followed by adjuvant temozolomide. Patients were evaluated clinically and radiologically every 8 weeks with contrast enhanced MRI scans until progression of disease.

Results: All patients progressed, relapsed, and died. A total of 39 patients (63%) had documented responses (CR+PR), 8 patients (13%) had stable disease (SD) and 15 patients (24%) progressed (PD). The average number of treatments received was 12 (6 cycles), ranging between 2 to 40 treatments (1-20 cycles). The 6 months progression free survival was 46%; 6 months overall survival was 62%, median overall survival was 8.6 months; median progression-free survival was 6.2 months.

Conclusion: Bevacizumab given at 5 mg/kg at relapse is safe and yields responses similar to higher doses. There was a trend towards better progression free survival at the first relapse but there was no difference in the overall survival.

Keywords: High Grade Gliomas; Bevacizumab; Vascular Endothelial Growth Factor; Progression Free Survival; Overall Survival

Background and rationale

Glioblastoma multiforme is the most common malignant primary CNS tumor with an incidence of 5 / 100,000 per year. It only accounts for 1% of adult cancer but results in 2% of deaths from cancer [1].

The standard of care for newly diagnosed GBM following surgery is concurrent chemoradiation using a 3D conformational radiation technique delivering a total dose of 60 Gy in daily fractions of 1.8 Gy over approximately 6 weeks or 42 days and protracted temozolomide at a dose of 75 mg/m² daily for the entire period of radiation therapy. This is followed by 6 or more cycles of adjuvant temozolomide given at 150-200 mg/m² daily 5 days every 28 days [2,3].

Unfortunately most patients will relapse. Relapsed high grade gliomas (HGG) respond poorly to current chemotherapy with a median survival of 3 to 6 months [4,5]. Despite recent advances in diagnosis and treatments combining surgery, radiation and chemotherapy, median survival from diagnosis is approximately 14 months [2] and median survival from the time of recurrence is approximately 4 months [5-10] prior to the introduction of antiangiogenic therapy. These increased to an overall median survival of approximately 20 months, when adding Bevacizumab for recurrent disease.

Vascular endothelial growth factors receptors (VEGFR) are highly expressed in high-grade gliomas. Many trials were designed with early antiangiogenic drugs and reported minor activity of such drugs and often no improvement in survival.

Bevacizumab a humanized monoclonal IgG1 antibody against VEGF was designed in early 2000 and was rapidly incorporated in many combined chemotherapy regimens for diverse malignancies mainly colorectal cancer. The use of bevacizumab showed survival benefit with acceptable toxicities in metastatic colorectal cancer [11]. It has also prolonged the time to progression of the metastatic renal cancer [4]. It continues to be extensively investigated in several types of disseminated cancers, presently.

The highly vascular nature of high grade gliomas made of bevacizumab an attractive alternative to salvage therapy. VEGF levels of expression were linked to higher grade and rapid progression [12,13]. The suppression of angiogenesis, as demonstrated by the xenograft study in immunodeficient mice, inhibits malignant cell proliferation [14].

CPT11 (irinotecan) is a topoisomerase 1 inhibitor that showed, when combined with bevacizumab, significant activity against gastrointestinal malignancies, particularly colorectal carcinoma [15]. Several trials of CPT11 as single agent in HGG failed to report any activity or minor additive activity in combination regimen [12].

Bevacizumab and CPT11 combination was first reported in a small series of patients with recurrent GBM in May 2005 [16]. Since then, several phase II studies have reported unprecedented response rates in excess of 60% with few side effects. Almost all studies were reported using 10 mg/kg of Bevacizumab every 2 weeks or 15 mg/kg of Bevacizumab every three weeks in one [12,13,17]. Only one article reported the use of 5 mg in a smaller series of patients [18] at the time we were reporting our preliminary data.

More recently, phase III studies incorporated Bevacizumab upfront with concurrent temozolomide and radiation therapy, yielding unprecedented disease free survivals and trends towards improved overall survivals [19,20].

This study was designed and completed before the aforementioned trials and copied on the initial presentation reported by Stark-Vance thus using only 5 mg/kg of bevacizumab and homogenously 125 mg /m² of CPT11 every 2 weeks [16].

Patients and methods

Patients selection

A total of 62 patients, 18 years and older with recurrent or progressive high grade gliomas confirmed histologically were enrolled between Nov 2006 & Dec 2009. Patients diagnosed with initially anaplastic gliomas were included after progression to higher grade, which was documented radiologically and pathologically when possible.

At least six weeks interval after prior intracranial surgery and/or four weeks interval after last chemo-radiation therapy were required. All patients had to have an absolute neutrophil count more than 1,500/ μ L, a hematocrit more than 29%, and a platelet count more than 100,000/ μ L.

Other exclusion criteria were the following: Creatinine > 1.5 mg/dL, bilirubin > 1.5 mg/dL, and serum AST > 1.5. Patients were also excluded if intracranial hemorrhage was suspected on the baseline MRI, or if previously treated with bevacizumab. All patients signed informed consent to an ethics committee approved trial.

Our target accrual was 62 patients. All comers with a Karnofsky Performance Status (KPS) of \geq 50% regardless of prior relapses and second line regimen were enrolled from November 2006 until December 2009.

All Subjects were initially treated by surgical resection or biopsy, concurrent chemoradiation and adjuvant temozolomide until progression.

Endpoints

The Primary endpoints were response rate (RR) and 6 months progression free survival (6M-PFS). The secondary endpoints were toxicities, tolerability, overall progression free survival (PFS), and survival outcome/overall survival (OS) at the completion of the study.

Treatment

Both bevacizumab and CPT11 (Irinotecan) were administered in combination to all 62 patients every 2 weeks of 28 days cycle. Doses were as follows: Bevacizumab 5 mg/kg and CPT11 125 mg/m².

Bevacizumab was administered over 90 minutes for the first dose, and over 60 minutes for the second dose if no adverse reactions were noted, all following doses were given in 30 minutes. All patients had to have hematologic recovery as documented by an absolute neutrophil count more than 1,000 and platelets more than 100,000 before subsequent infusions.

Dose reductions were allowed for CPT11 when related side effects were reported at grade III or more. All patients were changed to non-enzyme inducing antiepileptic drugs (NEIAEDs) prior to receiving CPT11.

Patients' evaluation

Detailed history, complete physical with vital signs check, KPS verification, and neurological examination along with laboratory tests including complete blood count, prothrombin time and partial thromboplastin time determinations, serum chemistry profile, urine test for protein-to-creatinine ratio, and a pregnancy test for any woman of child-bearing potential were assessed at every forth chemotherapy treatment, or sooner if any suspicion of disease progression or potential toxicity/side effects. The toxicities were graded according to the National Cancer Institute Common Toxicity Criteria, version 3.0. Contrast enhanced brain MRI scans were also obtained following two cycles (4 chemotherapy treatments) or earlier if progression was suspected clinically.

Response criteria

The responses were assessed clinically and radiologically by two investigators independently and agreed on all discrepancies. The regular neurological assessments were noted and steroids requirement documented, and compared to the MRI findings.

The T1 enhanced images were used to evaluate responses according to the Macdonald's criteria [21] which use the largest cross-sectional area of the post contrast images and also take into account the taper in dexamethasone dose, clinical and neurological improvement. Our study was initiated before RANO criteria were published²². The non-contrast T1, T2, and fluid-attenuated inversion recovery (FLAIR) sequences were used to evaluate non-enhancing progression.

Complete response (CR) was defined as a disappearance of all enhancing tumor, partial response (PR) when contrast images showed > 50% decrease in tumor size in comparison with baseline scans. An increase of tumor enhancement of > 25% and the appearance of new lesions defined progressive disease (PD). Any other situation was determined as stable disease (SD). Clinical correlation and decrease in steroids requirement were mandatory for inclusion in the group of responders.

Statistical considerations

The data reported by Stark-Vance in 2005 [16] and Yung et al [5] showing that the treatment of GBM patients in first relapse with temozolomide produced a 6-month progression-free survival (6M-PFS) rate of 21% constituted the basis on which this phase II was initiated. A subset analysis comparing patients enrolled following several lines of therapy (Group1) and patients enrolled at first relapse (Group2) was performed.

Using Kaplan Meier method, 6M-PFS, PFS, 6M-OS, and OS were estimated from date to treatment initiation until date of relapse, last follow up or death respectively. Early discontinuation of treatment was decided at the occurrence of a grade 2 or higher CNS hemorrhage or grade 4 and higher non-hematologic toxicity caused by the treatment. An unexpected toxicity rate of 15% or less would not be cause for stopping the trial, whereas a rate of 40% or greater would signal that the trial should be stopped.

Results

Our interim analysis and updated results demonstrating high response rates similar to other investigators were previously presented in international meetings.²³ We are herein presenting our final results.

Patients' characteristics

Our study included a total of 62 patients, whose characteristics are listed in Table 1. Of 62 participants, 58% (36/62) were males (60% and 56% in each group respectively). The overall median age was 44 and ranged between 18 and 67. The median KPS was 70% (range from 50% to 100%) for group 1 and 90% (range from 70 to 100%) for group 2. The total median KPS was 80%.

	Group 1	Group 2	Total
No. of patients	30	32	62
Age			
Median (range)	42 (18-67)	45 (17-67)	44
Gender			
Male	18	18	36
Female	12	14	26
KPS			
Median	70-80%	80-100%	80%
<70%	12 (40%)	0	12 (19%)
70-80%	7 (23%)	14 (44%)	21 (34%)
90-100%	11 (37%)	18 (56%)	29 (47%)
Histologic diagnosis			
GBM	21 (70%)	21 (66%)	42 (68%)
AA	7 (23%)	11 (34%)	18 (29%)
AOD	2 (7%)		2 (3%)

Table 1: Patients' characteristics

Response rate and survival

The response assessment was based on data from clinical and radiological follow-up (Table 2).

A total of 62 patients were evaluable and all relapsed or progressed. Of 62 patients, 39 (63%) had documented responses (CR+PR), equally reported for each of the subgroups; 8 patients (13%) had stable disease (SD) and 15 patients (24%) progressed (PD). Five patients (8%) had complete clinical and radiological response. T2-weighted and fluid attenuated inversion recovery abnormalities improved in all responders. Moreover, all responders had their steroids tapered then discontinued and noticed significant neurological improvement.

The average number of treatments received was 12 (6 cycles), ranging between 2 to 40 treatments (1-20 cycles).

Responses	Group 1 (30)	%	Group 2 (32)	%	Total (62)	%
CR	2	7	3	9.5	5	8
PR	17	56.5	17	53.5	34	55
SD	6	20	2	6	8	13
PD	5	16.5	10	31	15	24
Outcome						
Outcome	Group 1		Group 2		Total	
Median PFS (months)	5.2 M		7.2M		6.5 M	
Median OS (months)	9.2 M		9.5 M		9.5 M	
6M-PFS (%)	33.4%		56.3%		45%	
6M-OS (%)	66.7%		65.6%		66%	

Table 2: Response and outcome

PFS and OS

For the total of 62 patients, the 6 months progression free survival (6M-PFS) was 45% (Figure 1), the 6 months overall survival (6M-OS) was 66% (Figure 1), the median progression-free survival (PFS) was 6.5 months (Figure 2), and the median overall survival (OS) was 9.5 months (Figure 2). The clinical and the radiographic responses correlated well (Figure 3). (Table 2).

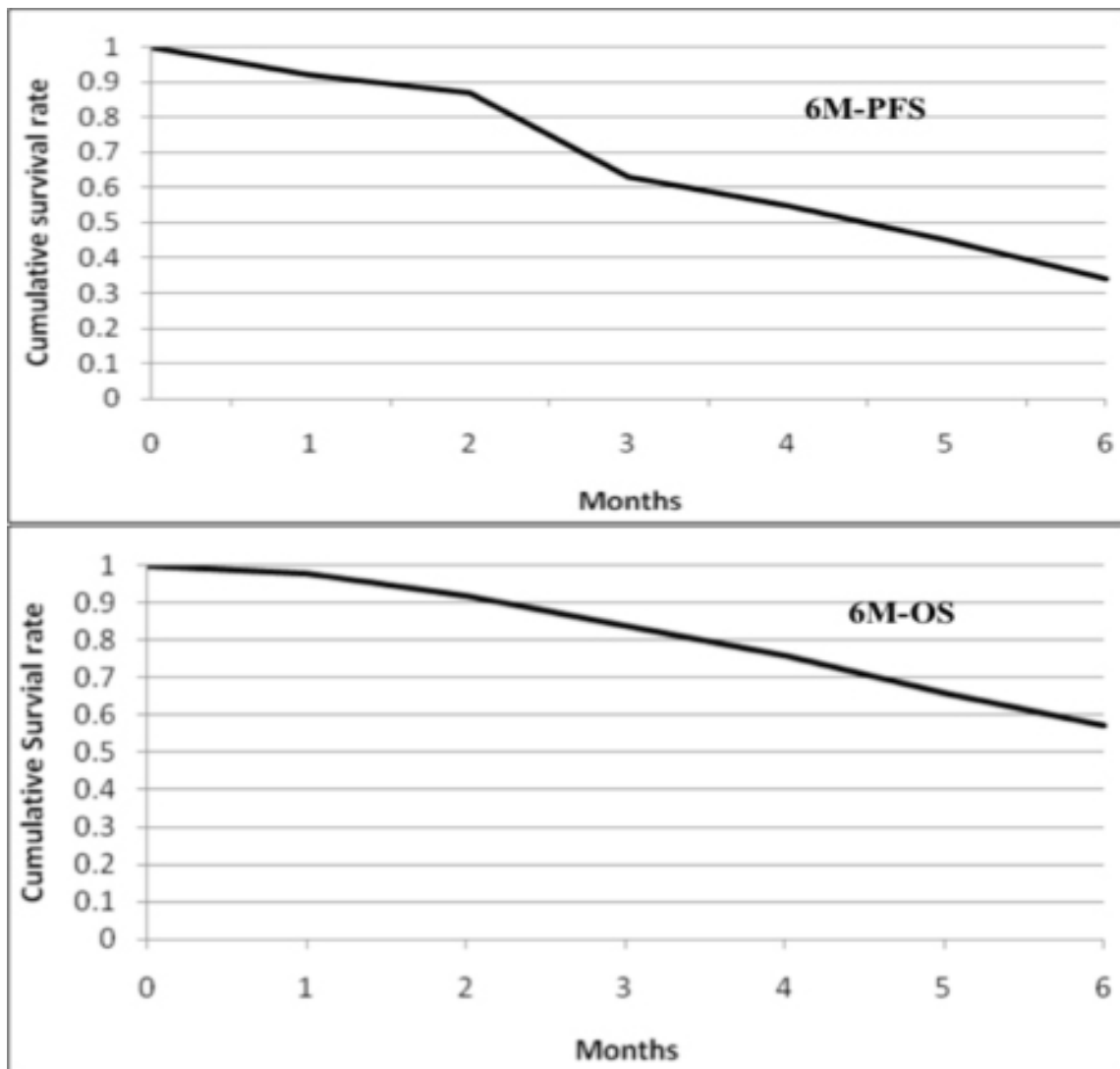


Figure 1: Kaplan-Meir curves showing 6M-PFS and 6M-OS of 62 patients with recurrent High grade gliomas

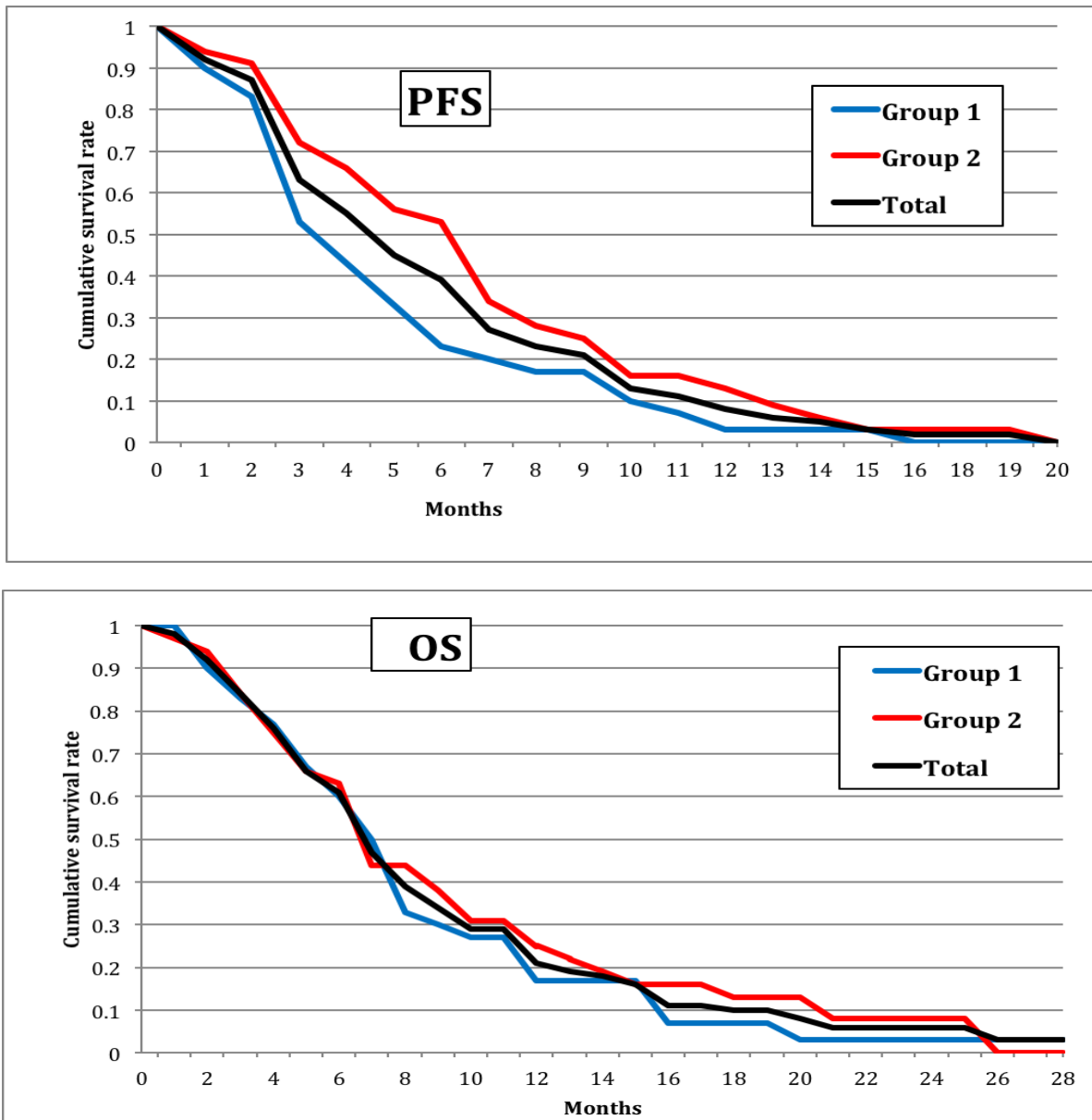


Figure 2: Kaplan Meier curves showing the PFS and the OS of group 1 (blue), group 2 (red) and the total of 62 patients

Toxicity

We designed this protocol using lower doses of bevacizumab, as published in the initial series [16], to minimize the potential toxicities and side effects. Treatments were well tolerated and toxicities reported as follow (Table 3); 12 patients (19%) had grade 3-4 thrombocytopenia, 22 (35%) had grade 1-2 anemia, and 4 (6.5%) had grade 3-4 neutropenia. We report low percentage of non-hematological complications with 1% incidence of each DVT, PE, and intracranial hemorrhage.

	Grade 1-2	Grade 3-4
Hematological		
Neutropenia	4 (6.5%)	4 (6.5%)
Thrombocytopenia	6 (9.5%)	12 (19%)
Anemia	22 (35%)	0
Non-hematological		
Deep Venous Thrombosis	1	(1%)
Pulmonary Embolism	1	(1%)
Brain Hemorrhage	1	(1%)
Delayed Wound Healing	1	(1.5%)

Table 3: Adverse reactions

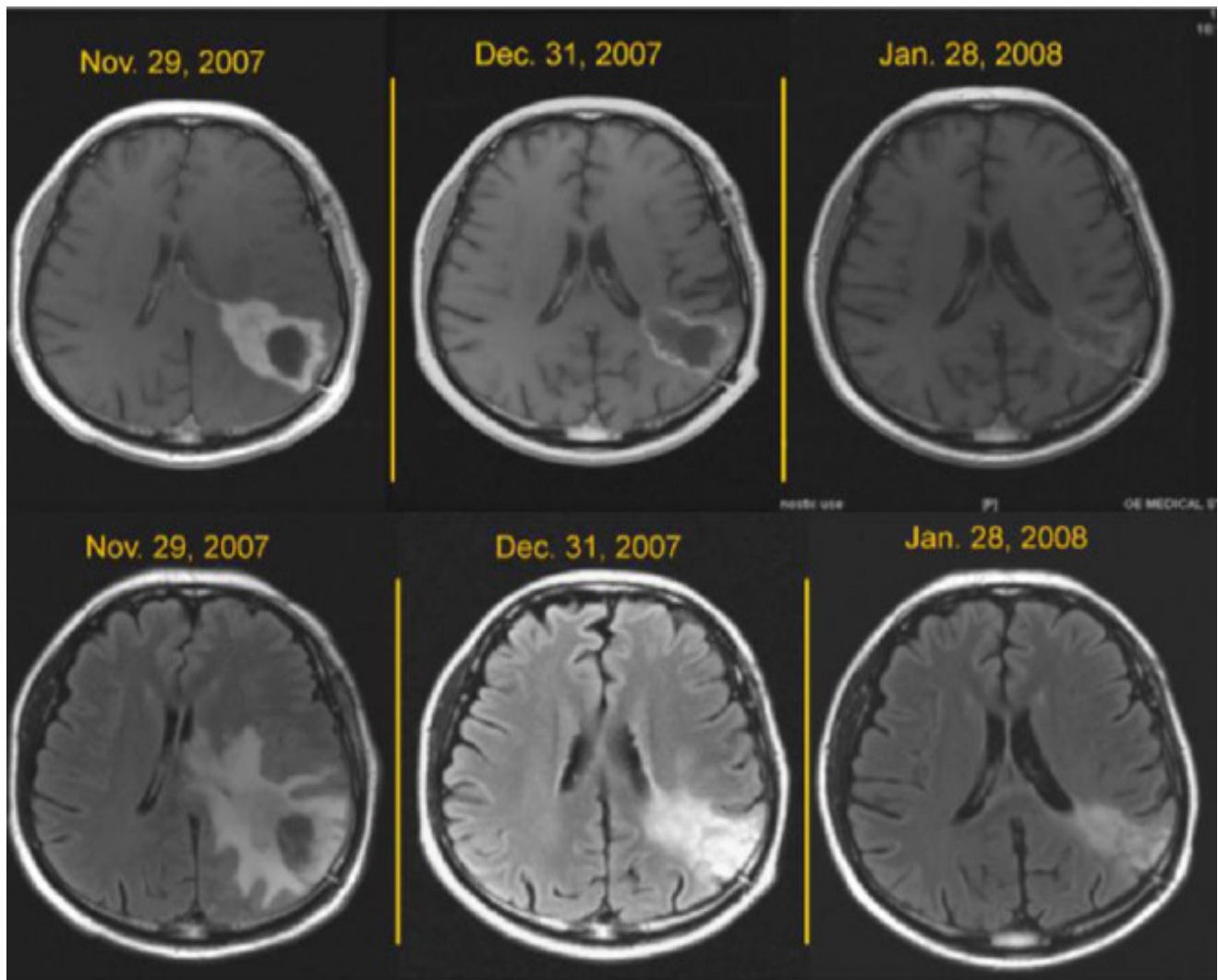


Figure 3: Post contrast Axial T1 images (upper) and FLAIR images (lower) before and after treatment with bevacizumab and CPT11. Note the progressive regression of size, contrast enhancement, and signal's abnormal intensity with consecutive treatments

Discussion

The prognosis of HGG after relapse is often dismal with median of survival less than 25 weeks for GBM. The radiographic response to chemotherapy is less than 15% and 6M-PFS is limited to 21% in case of GBM [10-12].

Vrendenburgh et al [17] conducted in 2007 the first phase II trial comparing the efficacy of bevacizumab alone or in combination with CPT11 in HGG, and reported a significant antitumor response. Later, another trial showed that bevacizumab combined to chemotherapy resulted in significant improvement in disease free survival and overall survival in recurrent high grade Gliomas despite the failure of one or more agents. Kreisl et al [13] demonstrated that single-agent bevacizumab in patients with recurring HGG had considerable effects on antiglioma activity, vascular permeability and cerebral edema.

Our study accrued 62 patients with recurrent high-grade glioma (HGG). Patients were evaluated clinically and radiologically every 8 weeks with contrast enhanced MRI scans until progression of disease. All patients received 5 mg/kg of bevacizumab and 125 mg/m² of CPT11 every 2 weeks, after failing concurrent chemoradiation followed by adjuvant temozolomide.

All primary endpoints were reached and analyzed. The response rate and the 6 months progression free survival of the total 62 patients were similar to the previously reported trials [17,24].

The results of the subset analysis comparing patients enrolled following several lines of therapy (Group1) and patients enrolled at first relapse (Group2) were similar. The mean KPS was superior in the group 2. A trend towards improved PFS was noted for patients in the group 2 (Figure 2). However, this difference had no a statistical significance. The OS results were identical and no statistical difference was found between the two groups (Figure 2).

Our study was designed following the same doses reported in the initial presentation [16] thus using only 5 mg/kg of bevacizumab and homogeneously 125 mg /m² of CPT11 every 2 weeks. Despite lower dosage, the overall response rate (63%), PFS (6.5M), and 6M-PFS rate (45%) were comparable to previously reported series using 10 mg/kg of bevacizumab [17,24].

Although this study was not meant to be a comparative trial of efficacy of different bevacizumab dosing in high-grade glioma, our results do support the fact that lower doses (5mg / kg in this case) may be as efficient as higher doses commonly used. The economic impact on the cost of health care is tremendous, with approximate 50% savings on the treatment costs.

Moreover complications related to bevacizumab therapy were lower and did not lead to any treatment related death. Direct toxicity and delayed side effects from CPT 11 were low. When compared to previously reported series, the possible explanation being the lower dosing allowed by the switching of all patients to NEIAED prior to initiation of therapy.

While our study results concur with prior published results of salvage bevacizumab based regimen for recurrent glioblastoma multiforme, a multi-institutional phase III study with 5mg/kg of bevacizumab in recurrent GBM, enrolling more patients, will strengthen these findings.

Conclusion

The bevacizumab-based regimen for relapsed GBM demonstrates superior activity compared to historical treatments. It is safe and improves overall quality of life in this patients' category.

Bevacizumab given at 5 mg/kg at relapse is safe and yields survival data similar to higher doses (e.g. 10mg/kg or 15 mg/kg). The use of lower dose will have major economic impact by reducing up to 50% the burden of the treatment costs.

References

- Kohler BA, Ward E, McCarthy BJ, Schymura MJ, Ries LA, et al. (2011) Annual report to the nation on the status of cancer, 1975-2007, featuring tumors of the brain and other nervous system. *J Natl Cancer Inst* 103: 714-36.
- Stupp R, Mason WP, van den Bent MJ, Weller M, Fisher B, et al. (2005) Radiotherapy plus concomitant and adjuvant temozolomide for glioblastoma. *N Engl J Med* 352: 987-96.
- Keime-Guibert F, Chinot O, Taillandier L, Cartalat-Carel S, Frenay M, et al. (2007) Radiotherapy for glioblastoma in the elderly. *N Engl J Med* 356: 1527-35.
- Yang JC, Haworth L, Sherry RM, Hwu P, Schwartzentruber DJ, et al. (2003) A randomized trial of bevacizumab, an anti-vascular endothelial growth factor antibody, for metastatic renal cancer. *N Engl J Med* 349: 427-34.
- Yung WK, Albright RE, Olson J, Fredericks R, Fink K, et al. (2000) A phase II study of temozolomide vs. procarbazine in patients with glioblastoma multiforme at first relapse. *Br J Cancer* 83: 588-93.
- Cloughesy TF, Filka E, Kuhn J, Nelson G, Kabbinavar F, et al. (2003) Two studies evaluating irinotecan treatment for recurrent malignant glioma using an every-3-week regimen. *Cancer* 97: 2381-6.
- Friedman HS, Petros WP, Friedman AH, Schaaf LJ, Kerby T, et al. (1999) Irinotecan therapy in adults with recurrent or progressive malignant glioma. *J Clin Oncol* 17: 1516-25.
- Prados MD, Lamborn K, Yung WK, Jaeckle K, Robins HI, et al. (2006) A phase 2 trial of irinotecan (CPT-11) in patients with recurrent malignant glioma: a North American Brain Tumor Consortium study. *Neuro Oncol* 8: 189-93.
- Raymond E, Fabbro M, Boige V, Rixe O, Frenay M, et al. (2003) Multicentre phase II study and pharmacokinetic analysis of irinotecan in chemotherapy-naïve patients with glioblastoma. *Ann Oncol* 14: 603-14.
- Wong ET, Hess KR, Gleason MJ, Jaeckle KA, Kyritsis AP, et al. (1999) Outcomes and prognostic factors in recurrent glioma patients enrolled onto phase II clinical trials. *J Clin Oncol* 17: 2572-8.
- Hurwitz H, Fehrenbacher L, Novotny W, Cartwright T, Hainsworth J, et al. (2004) Bevacizumab plus irinotecan, fluorouracil, and leucovorin for metastatic colorectal cancer. *N Engl J Med* 350: 2335-42.
- Friedman HS, Prados MD, Wen PY, Mikkelsen T, Schiff D, et al. (2009) Bevacizumab alone and in combination with irinotecan in recurrent glioblastoma. *J Clin Oncol* 27: 4733-40.
- Kreisl TN, Kim L, Moore K, Duic P, Royce C, et al. (2009) Phase II trial of single-agent bevacizumab followed by bevacizumab plus irinotecan at tumor progression in recurrent glioblastoma. *J Clin Oncol* 27: 740-5.
- Chaudhry IH, O'Donovan DG, Brenchley PE, Reid H, Roberts IS (2001) Vascular endothelial growth factor expression correlates with tumour grade and vascularity in gliomas. *Histopathology* 39: 409-15.
- Saltz LB, Cox JV, Blanke C, Rosen LS, Fehrenbacher L, et al (2000) Irinotecan plus fluorouracil and leucovorin for metastatic colorectal cancer. *Irinotecan Study Group. N Engl J Med* 343: 905-14.
- Stark-Vance V (2005) Bevacizumab and CPT-11 in the treatment of relapsed malignant glioma World Federation of Neuro-Oncology Meeting May.
- Vredenburgh JJ, Desjardins A, Herndon JE, Dowell JM, Reardon DA, et al. (2007) Phase II trial of bevacizumab and irinotecan in recurrent malignant glioma. *Clin Cancer Res* 13: 1253-9.
- Bokstein F, Shpigel S, Blumenthal DT (2008) Treatment with bevacizumab and irinotecan for recurrent high-grade glial tumors. *Cancer* 112: 2267-73.
- Chinot OL, de La Motte Rouge T, Moore N, Zeaiter A, Das A, et al. (2011) AVAGlio: Phase 3 trial of bevacizumab plus temozolomide and radiotherapy in newly diagnosed glioblastoma multiforme. *Adv Ther* 28: 334-40.
- Weller M, Yung WK (2013) Angiogenesis inhibition for glioblastoma at the edge: beyond AVAGlio and RTOG 0825. *Neuro Oncol* 15: 971.
- Macdonald DR, Cascino TL, Schold SC, Cairncross JG (1990) Response criteria for phase II studies of supratentorial malignant glioma. *J Clin Oncol* 8: 1277-80.
- van den Bent MJ, Wefel JS, Schiff D, Taphoorn MJ, Jaeckle K, et al. (2011) Response assessment in neuro-oncology (a report of the RANO group): assessment of outcome in trials of diffuse low-grade gliomas. *Lancet Oncol* 12: 583-93.
- Kairouz (2010) Updated Results of a Phase II Trial of Bevacizumab and Irinotecan in Relapsed High Grade Gliomas. *Neuro-Oncology* 12: iii47.
- Norden AD, Young GS, Setayesh K, Muzikansky A, Klufas R, et al. (2008) Bevacizumab for recurrent malignant gliomas: efficacy, toxicity, and patterns of recurrence. *Neurology* 70: 779-87.

Submit your next manuscript to Annex Publishers and benefit from:

- ▶ Easy online submission process
- ▶ Rapid peer review process
- ▶ Online article availability soon after acceptance for Publication
- ▶ Open access: articles available free online
- ▶ More accessibility of the articles to the readers/researchers within the field
- ▶ Better discount on subsequent article submission

Submit your manuscript at
<http://www.annexpublishers.com/paper-submission.php>