

Blastic Plasmacytoid Dendritic Cell Neoplasm Presenting as a Harbinger of Acute Myeloid Leukemia

Pakran J¹, Alfalasi AJ¹ and Seliem RM²

¹Department of Dermatology, Rashid Hospital, Dubai Health Authority, Dubai, UAE

²Department of Pathology and Genetics, Rashid Hospital, Dubai Health Authority, Dubai, UAE

*Corresponding author: Pakran J, Dermatology Center, Rashid Hospital, Dubai Health Authority Dubai, UAE, Tel: 00971528678291, E-mail: jaheershanijas@gmail.com

Citation: Pakran J, Alfalasi AJ, Seliem RM (2021) Blastic Plasmacytoid Dendritic Cell Neoplasm Presenting as a Harbinger of Acute Myeloid Leukemia. J Dermatol Dermatopathol 1(1): 103

Received Date: February 11, 2021 **Accepted Date:** February 22, 2021 **Published Date:** February 24, 2021

Abstract

A 51 year old female was referred to our dermatology clinic for a rapidly growing lump on head of 6 weeks duration. On examination we observed a 15 cm diameter erythematous crusted tumor on the forehead with significant bilateral cervical lymphadenopathy. An excision biopsy of the tumor revealed a malignant high grade diffuse undifferentiated infiltrating neoplasm involving the skin and subcutaneous tissue. The cells had prominent nucleoli, moderate cytoplasm, and finely dispersed chromatin. Immunohistochemistry was positive for CD4, CD56, CD45, CD68, BCL2, and CD43 with very high proliferation fraction by Ki67 (80%). We reached a diagnosis of Blastic Plasmacytoid Dendritic Cell Neoplasm (BPDCN). Initial blood work up, flow cytometry and bone marrow aspiration biopsy were normal. Lymph Node biopsy was delayed due to atrial fibrillation episode and approximately 1 month later she developed rapidly growing tumors on side of her face causing her difficulty in swallowing. At this time the repeat investigations revealed that the blood picture had changed and there were blast cells in peripheral smear and bone marrow studies showed features of acute myeloid leukemia. She was finally diagnosed as a case of BPDCN with AML. After first cycle of chemotherapy she died from septic complications. This case highlights the clinical presentation and rapid progression of BPDCN, and its frequent association with other myeloid malignancies.

Keywords: Blastic plasmacytoid dendritic cell neoplasm

Introduction

Blastic plasmacytoid dendritic cell neoplasm (BPDCN) is a rare clinically aggressive hemato-dermic aggressive tumor classified under myeloid neoplasms with a median overall survival of less than a year in untreated cases. BPDCN is associated 10-20% cases with hematologic dyscrasias [1]. Our case highlights the clinical presentation and rapid progression of BPDCN, and its frequent association with other myeloid malignancies.

Case Synopsis

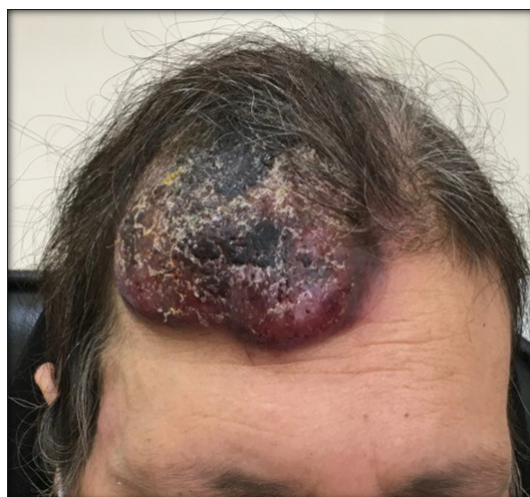

Figure 1: Large plum colored well defined tumor on forehead of patient, with hemorrhagic crusting on surface

A 51 year old female presented to dermatology clinic with a fast growing lump on her head of 6 weeks duration. She was chronic smoker and had past history of essential hypertension since 15 years, recurrent episodes of atrial fibrillations, and chronic HCV infection genotype 4 with no evidence of advance fibrosis of 3 years duration. She had history of thyroidectomy for goiter and blood transfusion 12 years back. She was on thyroxine 150 mcg, amlodipine 5 mg and Sofosbuvir-Velpatasvir combination daily. On examination she was found to have a firm 15 cm diameter red purple tumor on forehead with hemorrhagic crusting on surface (Figure 1). The lesion was warm, non-compressible and non-tender to touch. There was an additional pink plaque on right temple of 2cm diameter. There was significant regional lymphadenopathy in cervical area and hepatosplenomegaly on examination. A differential diagnosis of B cell lymphoma, angiosarcoma, and metastasis from internal malignancy were considered.

MRI of head showed a purely subcutaneous mass. Excision skin biopsy was done which showed (Figure 2b) sheets of highly atypical blastoid appearing cells with prominent nucleoli, moderate cytoplasm, and finely dispersed chromatin massively involving the skin and subcutaneous tissue with presence of marked ulcerations, necrosis and hemorrhage. Grenz zone was noted in some areas (Figure 2a). The neoplastic cells were positive for CD4, CD56, BCL2, CD43 and CD45, and focally expressing CD68, CD7 and CD10 and shows a very high proliferation fraction by Ki67 (80%). The neoplastic cells were negative for PAX5, CD19, CD138, lysozyme and BCL6. The immunostains morphology were consistent with BPDCN. We proceeded with staging and pretreatment evaluation. Her initial full blood count (FBC), LDH and complete metabolic panel (CMP) were normal.

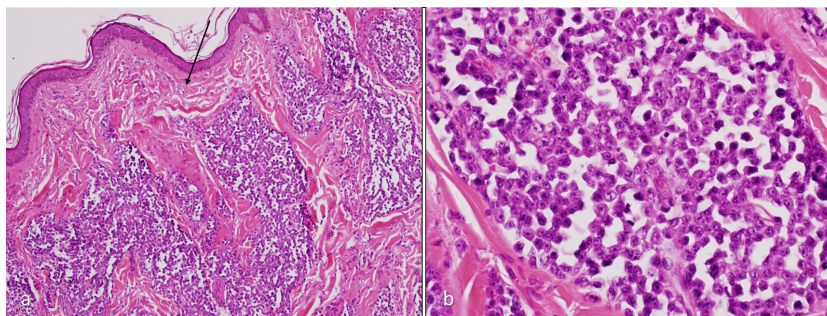


Figure 2: Skin biopsy shows infiltrating neoplastic cells massively involving the skin and subcutaneous tissue with presence of marked ulcerations, necrosis and hemorrhage (A) Grenz zone was noted in some areas (arrow); (B) Higher magnification shows highly atypical blastoid appearing cells with prominent nucleoli, moderate cytoplasm, and finely dispersed chromatin

Bone marrow trephine biopsy revealed large paratrabeular sheets of macrophages and immunohistochemistry showed diffuse positivity for CD45 with marked increase in CD68 expressing cells. There are scattered cells showing CD20, CD3, CD4 and CD8 expression representing the normal B and T cells and their subsets in the bone marrow. Specifically, the macrophages did not show CD4 or CD56 expression. There was no increase in CD34 expressing immature cells. CD43 staining was suboptimal and non-contributory. There was no increase in the Ki67 staining cells, i.e. <1%.

Imaging studies with CT showed diffuse bilateral ground-glass changes with right pleural effusion and cardiomegaly, hepatosplenomegaly, right supraclavicular enlarged lymph nodal mass, few slightly enlarged retro peritoneal mass and osteolytic lesions in the medial end of the left clavicle, and in the D12 vertebral body which possibly represented metastasis. Thus a stage of modified Ann Arbor stage III E was made.

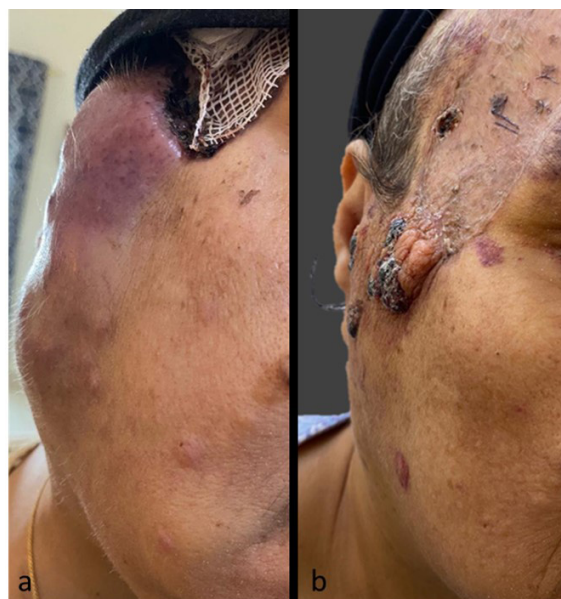

Figure 3: Large pink to erythematous nodules covering right parotid area (A) Regression of these lesions after 7 days of dexamethasone therapy with some yellowish xanthomatoid changes (B)

One month later, patient developed rapidly growing tumors on right side of her face which interfered with mastication (Figure 3a). She was given injection dexamethasone 8mg daily for 7 days and her tumor regressed significantly with residual yellowish xanthomatoid plaques (Figure 3b). However on tapering the steroids, the lesions recurred. Her lymph node biopsy had to be postponed due to fast atrial fibrillation. At this time her repeat FBC showed alarming leukocytosis ($35.9 \times 10^3/\mu\text{l}$), thrombocytopenia (19,000/ μl) and LDH of 1,771 U/L.

Blood film repeated showed 16% blast cells. Flow cytometry confirmed lineage of the blasts that showed a myeloid phenotype and were positive for MPO, CD33, HLADR, CD11b (heterogeneous), and CD11c. In addition, the blasts expressed bright CD4, CD56 and CD5. In addition, the blasts express CD81, CD71, and CD58. CD123 is expressed by 60% of the blasts while CD38 expression was seen in a 20%. Other myeloid and monocytic markers like CD14, CD15, CD16, CD36, CD64, CD13 and CD24 were not expressed. CD41, CD61, T cell and B cell markers, and immature markers were all negative. Thus we reached a diagnosis of Acute Myeloid Leukemia (AML) with aberrant expression of CD4, CD56 and CD5 associated with BPDCN.

She received 1 cycle of FLAG (Fludarabine, cytarabine and filgrastim) chemotherapy regimen and her skin lesions showed shrinkage. But at week 2 of chemotherapy she developed neutropenia with severe septic shock and finally succumbed to the disease on day 5 of ICU admission.

Case Discussion

Blastic plasmacytoid dendritic cell neoplasm (previous name blastic NK/T cell lymphoma/leukemia) is a disorder of immature plasmacytoid dendritic cells. It is believed to have a bimodal incidence pattern, with higher incidences at younger than 20 years and older than 60 years of age [2]. BPDCN has high frequency of cutaneous/mucosal (64%–100%), bone marrow/peripheral blood (60%–90%), and lymph node (40%–50%) involvement [1]. The clinical presentation is often biphasic with an initial phase limited to skin and later involving the bone-marrow leading to leukemic phase and/or multi-organ spread [1]. In fact 10% cases are associated with chronic myeloid leukemia, myelodysplastic syndromes, or acute myeloid leukemia. Due to high incidence of skin lesions which is often the presenting sign of BPDCN, dermatologists need to know its clinical features. Skin lesions in BPDCN can be bruise like lesions (erythematous-hemorrhagic, infiltrated macules), brownish to violaceous infiltrated patches, plaques, or tumors which can be solitary, localized or generalized in distribution [3]. This bruise like appearance is said to be in favor of diagnosis as bone marrow involvement often result in cytopenias (particularly thrombocytopenia, 78% of patients) [1]. Our case had red purple vascular appearance at diagnosis even in the absence of thrombocytopenia initially.

Histopathology with immunohistochemistry (IHC) is key to a diagnosis of BPDCN. The skin lesions in BPDCN exhibit a nodular-diffuse growth pattern in the dermis often with grenz zone, and intra-tumoral hemorrhage. The neoplastic cells form dense monomorphous atypical blastic cells reminiscent of either lymphoblasts or myeloblasts. The neoplastic cells are medium- to large-sized with scant cytoplasm, prominent single or multiple nucleoli with irregular nuclear contours, and immature, fine chromatin. Our case progressed from stage III E to IV E within one month duration showing the aggressive nature of this disease. In the absence of initial blast cells the large paratrabecular sheets of macrophages in bone marrow seen in our case could be a harbinger of impending acute myeloid leukemia.

BPDCN is characterized by the expression of CD4, CD43, CD45RA, and CD56 in the absence of lineage-specific markers for either myeloid, T-lymphocytes, B-lymphocytes, or NK cells. In our case the neoplastic cells were positive for CD4, CD45, CD43, CD56, BCL2 and, partially expressing CD7 and CD10. Ubiquitous CD123 (interleukin-3 receptor subunit α) overexpression is characteristic of BPDCN and was positive in our case. We got negative results for PAX5, CD19, CD138, lysozyme and BCL6 reaffirming our diagnosis. CD5, CD7, CD68, and CD33 may be expressed in some cases and the bone marrow of our case had focal CD68 expression even before the leukemic phase.

BPDCN has to be differentiated from mature plasmacytoid dendritic cell proliferations (MPDCPs) that can occur in the setting of other myeloid neoplasms like AML, chronic myeloid leukemia and myelodysplastic syndrome, by the expression of CD56 and TCF4 (E2-2) transcription factor in BPDCN, but not in normal pDC (Plasmacytoid dendritic cell). In our case CD56 was diffusely positive. Myeloid sarcoma, is another condition that can be indistinguishable from BPDCN based on morphology, however the expression of lysozyme, CD68, or CD163 helps in differentiation. Our case had negative staining for lysozyme. Another differential diagnosis is CD56+ AML, extranodal NK/T cell lymphoma, and classic cutaneous T cell lymphoma having cutaneous metastasis. In such cases the expression of CD303 essentially confirms the pDC origin and excludes any non-pDC hematopoietic lesions but this stain was unavailable at our facility.

BPDCN treatment with standard chemotherapies frequently yield poor results. Venugopal S *et al.* [2], have proposed a treatment algorithm for BPDCN with initial consideration for targeted therapy (Tagraxofusp which is a CD123 targeted diphtheria immunotoxin or other newer investigational agents). When tagraxofusp is not an option, acute lymphoblastic leukemia (ALL)-inspired intensive chemotherapy regimen with CNS prophylaxis is preferred to AML regimen to induce remission due to beneficial effect of L-asparaginase in the former for BPDCN cases. This should be preferable followed by HSCT for consolidation and potential cure [2]. For elderly patients with co-morbidities like our patient only low-intensity therapies are feasible. In fact our patients response to dexamethasone 8mg daily was impressive during the early skin phase of disease but due to development of AML, she was shifted to AML based chemotherapy which unfortunately was not well tolerated and she developed neutropenic sepsis and eventually to demise.

Conclusion

BPDCN is a rare myeloid malignancy with cutaneous manifestation that should be under radar of dermatologist for possible association with other myeloid malignancies.

Conflict of interest

The authors have no relevant financial relationships to disclose

References

1. Sapienza MR, Pileri A, Derenzini E, Melle F, Motta G, et al. (2019) Blastic Plasmacytoid Dendritic Cell Neoplasm: State of the Art and Prospects. *Cancers (Basel)* 11: 595.
2. Venugopal S, Zhou S, El Jamal SM, Lane AA, Mascarenhas J (2019) Blastic Plasmacytoid Dendritic Cell Neoplasm-Current Insights. *Clin Lymphoma Myeloma Leuk* 19: 545-54.
3. Cota C, Vale E, Viana I, Requena L, Ferrara G, et al. (2010) Cutaneous manifestations of blastic plasmacytoid dendritic cell neoplasm-morphologic and phenotypic variability in a series of 33 patients. *Am J Surg Pathol* 34: 75-87.

Submit your next manuscript to Annex Publishers and benefit from:

- › Easy online submission process
- › Rapid peer review process
- › Online article availability soon after acceptance for Publication
- › Open access: articles available free online
- › More accessibility of the articles to the readers/researchers within the field
- › Better discount on subsequent article submission

Submit your manuscript at

<http://www.annepublishers.com/paper-submission.php>