

Melanotan®-Induced Hyperpigmentation of Oral Soft Tissues

Phoa KH¹ and de Baat C^{2,3}

¹Department of Maxillofacial Surgery and Maxillofacial Prosthodontics, Leiden University Medical Center, Leiden, the Netherlands

²Fresh Unieke Mondzorg, Woerden, the Netherlands

³Department of Oral Function and Prosthetic Dentistry, Radboud university medical center, Nijmegen, the Netherlands

***Corresponding author:** Phoa KH, Department of Maxillofacial Surgery and Maxillofacial Prosthodontics, Leiden University Medical Center, Albinusdreef 2, 2333 ZA Leiden, the Netherlands, Tel: +71 (0) 5269111, E-mail: k.h.phoa@lumc.nl

Citation: Phoa KH, de Baat C (2018) Melanotan®-Induced Hyperpigmentation of Oral Soft Tissues. J Dent Oral Care Med 4(1): 104. doi: 10.15744/2454-3276.4.104

Received Date: April 11, 2018 **Accepted Date:** May 26, 2018 **Published Date:** May 28, 2018

Summary

A 39-years-old Caucasian man presented with the complaint of gingiva bleeding during tooth brushing. Additionally, generalised intrinsic blue-brown discoloration or hyperpigmentation of the gingiva was noticed. Upon request to report each alteration of life style and food and drink consumption during the last months, the patient reported weekly subcutaneous self-injections with Melanotan® during the last six months in order to realize a cosmetically attractive brown skin color. Melanotan I®, with the generic name afamelanotide, is thought to mimic the effects of endogenous α -melanocyte stimulating hormone, leading to increased cutaneous pigmentation. It was suspected that this drug also has the adverse effect of up-regulation of brown-black eumelanin synthesis in the oral soft tissues. Several cutaneous adverse effects of afamelanotide have been reported in the scientific literature, but no previous reports could be found on discoloration of the oral soft tissues.

Keywords: Discoloration; Oral Soft Tissues; Hyperpigmentation

Case presentation

A 39-years-old Caucasian man presented with the complaint of gingiva bleeding during tooth brushing. His medical history revealed laparoscopic surgery because of ureteropelvic junction stenosis (UPJ-stenosis), 20 years previously. Furthermore, he used the drug hydrochlorothiazide/losartan for treatment of hypertension.

Intraoral examination revealed presence of food residues and oral biofilm on all teeth and oral soft tissues, oedematous gingiva, gingiva bleeding at probing, score 3 on the *Mühlemann* and *Son* gingival bleeding index and score 3 on the *Silness* and *Löe* plaque index. Following this examination, the primary diagnosis was generalised gingivitis due to insufficient removal of food residues and oral biofilm. Additionally, generalised intrinsic blue-brown discoloration or hyperpigmentation of the gingiva was noticed.

Subsequently, a dental hygienist removed the food residues and oral biofilm and provided information and instructions on daily oral hygiene self-care. A photograph was taken of the discoloured oral soft tissues (Figure 1). The patient received an appointment for evaluation of the oral soft tissues after seven days.

Seven days post oral hygiene treatment and normal daily oral hygiene self-care during seven days, the gingiva appeared to be healthy. However, the intrinsic blue-brown discoloration or hyperpigmentation of the oral soft tissues was still present. Because of the generalised aspect, racial pigmentation and pharmacological adverse effect were potential aetiologies. Meanwhile, the dentist had found an oral photograph of the patient which was taken thirteen years previously following a fracture of a frontal fixed dental prosthesis. The photograph showed the in Caucasian persons usual pink coloured oral soft tissues (Figure 2). Furthermore, the patient confirmed that his (grant) parents were all Caucasians. Consequently, racial pigmentation as diagnosis could be abandoned. Pharmacological adverse effect was the remaining option. However, discoloration of the oral soft tissues due to hydrochlorothiazide/losartan has never been reported in the scientific literature. Upon request to report each alteration of life style and food and drink consumption during the last months, the patient reported weekly subcutaneous self-injections with Melanotan® during the last six months in order to realize a cosmetically attractive brown skin color.

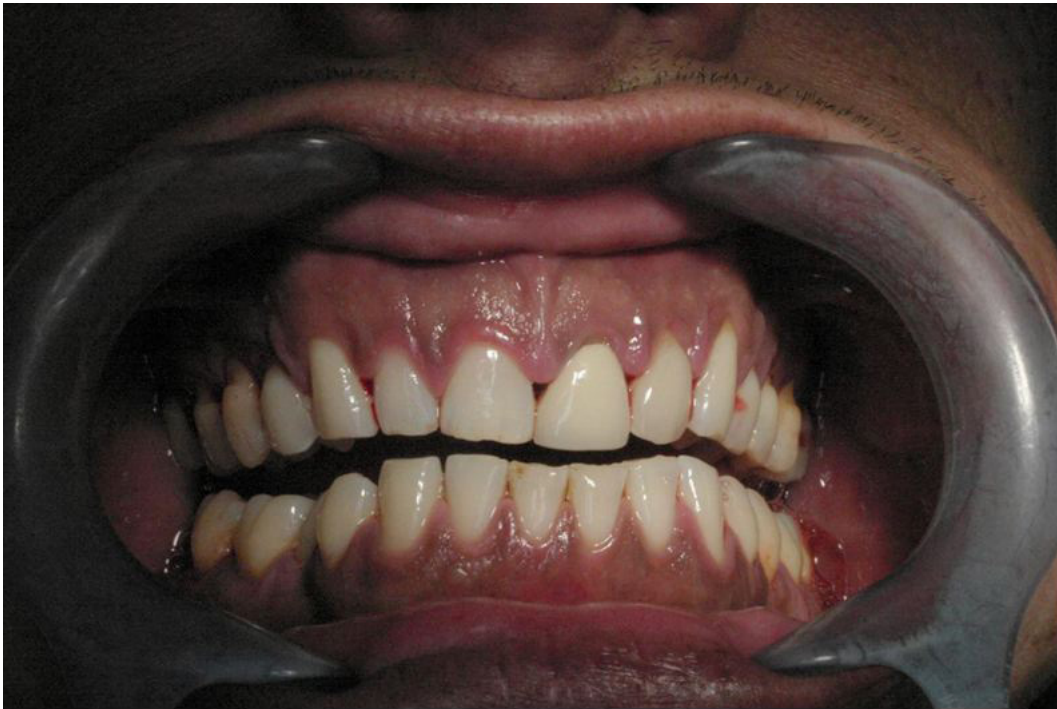

Figure 1: Discoloured oral soft tissues after professional removal of food residues and oral biofilm

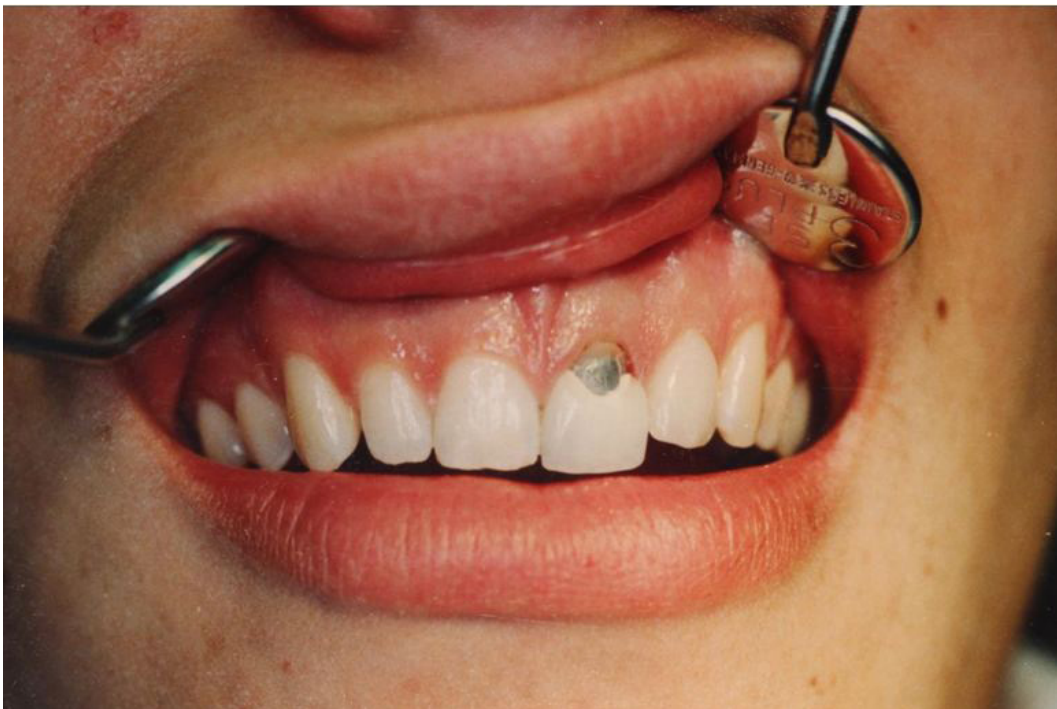


Figure 2: Usual pink coloured oral soft tissues, thirteen years previously. Photograph taken following a fracture of a frontal fixed dental prosthesis

Study of the Literature

Melanotan[®], with the generic name afamelanotide, is not registered as a drug in European countries. However, it is illegally on sale on the internet and in various shops and beauty salons [1]. Melanotan I[®] is thought to mimic the effects of endogenous α -melanocyte stimulating hormone (α -MSH) on the melanocortin 1 receptor which is expressed on melanocytes. This results in up-regulation of brown-black eumelanin synthesis, leading to increased cutaneous pigmentation. Promising therapeutic results were published in dermatologic disorders, such as polymorphic light eruption, erythropoietic protoporphyria, solar urticaria, Hailey-Hailey disease, and vitiligo. Melanotan II[®] is thought to exert a comparable action [2-5].

In the scientific literature, several adverse effects of Melanotan[®] have been reported, such as cutaneous hyperpigmentation, melanocytic naevus, and even melanoma [5-11].

No reports could be found on discoloration of the oral soft tissues due to the use of Melanotan®.

Discussion

It was suspected that the use of Melanotan® also has the adverse effect of up-regulation of brown-black eumelanin synthesis in the oral soft tissues. This seems the first report in the scientific literature of discoloration of the oral soft tissues as an adverse effect of afamelanotide.

The patient was informed about the probable cause of the discoloration of his oral soft tissues and about the risks of using Melanotan®. However, he was very satisfied with his brown skin, did not care about the discoloration of his oral soft tissues, and seemed prepared to take the risk of serious cutaneous and soft tissue adverse effects.

Conclusion

This case serves to highlight the importance of a thorough history of prescribed medications as well as over-the-counter drugs and to highlight the potential adverse effects of Melanotan®.

References

1. Evans-Brown M, Dawson RT, Chandler M, Mc Veigh J (2009) Use of melanotan I and II in the general population. *BMJ* 338: b566.
2. Breindahl T, Evans-Brown M, Hindersson P, McVeigh J, Bellis M, et al. (2015) Identification and characterization by LC-UV-MS/MS of melanotan II skin-tanning products sold illegally on the Internet. *Drug Test Analysis* 7: 166-72.
3. Minder EI, Barman-Aksoezan J, Schneider-Yin X (2017) Pharmacokinetics and pharmacodynamics of afamelanotide and its clinical use in treating dermatologic disorders. *Clin Pharmacokinet* 56: 815-23.
4. Langendonk JG, Balwani M, Anderson KE, Bonkovsky HL, Anstey AV, et al. (2015) Afamelanotide for erythropoietic protoporphyria. *N Engl J Med* 373: 48-59.
5. Kim ES, Garnock-Jones KP (2016) Afamelanotide: A review in erythropoietic protoporphyria. *Am J Clin Dermatol* 17: 179-85.
6. Ferrándiz-Pulido C, Fernández-Figueras MT, Quer A, Ferrándiz C (2011) An eruptive pigmented lesion after melanotan injection. *Clin Exp Dermatol* 36: 801-2.
7. Paurobally D, Jason F, Dezfoulian B, Nikkels AF (2011) Melanotan-associated melanoma. *Br J Dermatol* 164: 1403-5.
8. Ong S, Bowling J (2012) Melanotan-associated melanoma in situ. *Australas J Dermatol* 53: 301-2.
9. Hjulter KF, Lorentzen HF (2014) Melanoma associated with the use of melanotan-II. *Dermatology* 228: 34-6.
10. O'Leary RE, Diehl J, Levins PC (2014) Update on tanning: More risks, fewer benefits. *J Am Acad Dermatol* 70: 562-8.
11. Habbema L, Halk AB, Neumann M, Bergman W (2017) Risk of unregulated use of alpha-melanocyte-stimulating hormone analogues: a review. *Int J Dermatol* 56: 975-80.

Submit your next manuscript to Annex Publishers and benefit from:

- ▶ Easy online submission process
- ▶ Rapid peer review process
- ▶ Online article availability soon after acceptance for Publication
- ▶ Open access: articles available free online
- ▶ More accessibility of the articles to the readers/researchers within the field
- ▶ Better discount on subsequent article submission

Submit your manuscript at

<http://www.annexpublishers.com/paper-submission.php>