

A Case with Vitreomacular Traction Developing Complications after Intravitreal Perfluoropropane Injection

Hsin-Yu Weng¹, Chung-Yi Wu³ and Jia-Kang Wang^{*1,2,3,4,5}

¹Department of Ophthalmology, Far Eastern Memorial Hospital, New Taipei City, Taiwan

²Department of electrical engineering, Yuan Ze University, Taoyuan City, Taiwan

³Department of Medicine, National Yang Ming University, Taipei City, Taiwan

⁴Department of Healthcare Administration and Department of Nursing, Oriental Institute of Technology, New Taipei City, Taiwan

⁵Department of Medicine, National Taiwan University, Taipei City, Taiwan

***Corresponding author:** Jia-Kang Wang, Department of Ophthalmology, Far Eastern Memorial Hospital, Taipei, Taiwan, #21, Sec 2, Nan-Ya South Road, Pan-Chiao District, New Taipei City, 220, Taiwan, Tel: 886-2-89667000, E-mail: jiakangw2158@gmail.com

Citation: Hsin-Yu Weng, Chung-Yi Wu, Jia-Kang Wang (2018) A Case with Vitreomacular Traction Developing Complications after Intravitreal Perfluoropropane Injection. *J Ophthalmol Eye Care* 1(1): 104

Received Date: June 24, 2018 **Accepted Date:** September 3, 2018 **Published Date:** September 7, 2018

Abstract

Purpose: To present a case with vitreomacular traction (VMT) developing complications after intravitreal perfluoropropane injection.

Case Report: A sixty-year-old woman with no remarkable systemic disease came to our clinic due to blurred vision of right eye for one month. The best corrected visual acuity (BCVA) was 0.2 in the right eye, while intraocular pressure, anterior segment, and optic disc of right eye were all normal. Optical coherence tomography (OCT) was arranged, which showed VMT in right eye. Because the patient cannot afford the pharmacologic vitreolysis (ocriplasmin intravitreal injection), she agreed with intravitreal injection of 0.3 mL perfluoropropane (C₃F₈) and face-down posturing for one week. She came back to the clinic one week later for follow up, while full-thickness macular hole (FTMH) and localized inferior tractional retinal detachment without accompanying retinal breaks was noted. BCVA dropped to 0.05. Therefore, 23-gauge pars plana vitrectomy (PPV) and peeling of the internal limiting membrane (ILM) with diluted indocyanine green staining were performed, along with inferior retinotomy, fluid-air exchange for removing subretinal fluid. The retinotomy was treated with endolaser, followed by 10% C₃F₈ injection for tamponade, and face-down posturing was suggested for one week. After two months, closure of the FTMH was noted under OCT, with improved BCVA to 0.5. Fundus showed re-attached retina and inferior retinal scar.

Conclusion: Intravitreal perfluoropropane injection is an alternative choice of intervention for VMT, but surgeons must be aware of development of possible complications.

Keywords: Vitreomacular Traction Syndrome; Intravitreal Injection; Perfluoropropane; Vitrectomy; Internal limiting Membrane Peeling; Retinal Detachment

Introduction

Posterior vitreous detachment (PVD) is an insidious vitreous aging process, which is asymptomatic in many cases for years until complete separation of vitreous from the macula and the optic papilla. Vitreomacular adhesion (VMA) represents a normal stage of PVD when vitreous is still attached to perifoveal area but no anatomic changes in foveal contour, while vitreomacular traction (VMT) is an anomalous PVD stage when foveal surface is distorted by vitreous traction but no full-thickness interruption of all retinal layers is presented. Full-thickness macular hole (FTMH) is defined by all macular layers interruption from the internal limiting membrane (ILM) to the retinal pigment epithelium (RPE). Possible treatment options include pharmacologic vitreolysis, intravitreal gas bubble injection, and pars plana vitrectomy (PPV). Here, we present a case with VMT undergoing intravitreal perfluoropropane injection, who later developed FTMH.

Case report

A sixty-year-old woman with no remarkable systemic disease came to our clinic due to blurred vision of right eye for one month. Visual acuity was measured by the Snellen chart. The best corrected visual acuity (BCVA) was 0.2 in the right eye, while intraocular

pressure, anterior segment, and optic disc of right eye were all normal. Optical coherence tomography (OCT) was arranged, which showed VMT in right eye (Figure 1). Because the patient cannot afford the pharmacologic vitreolysis (ocriplasmin intravitreal injection), she agreed with intravitreal injection of 0.3 mL perfluoropropane (C3F8) and face-down posturing for one week. She came back to the clinic one week later for follow up, while full-thickness macular hole (FTMH) (Figure 2) and localized inferior tractional retinal detachment without accompanying retinal breaks was noted. BCVA dropped to 0.05. Therefore, 23-gauge pars plana vitrectomy (PPV) and peeling of the internal limiting membrane (ILM) with diluted indocyanine green staining were performed (Figure 3), along with inferior retinotomy, fluid-air exchange for removing subretinal fluid. The retinotomy was treated with endolaser, followed by 10% C3F8 injection for tamponade, and face-down posturing was suggested for six weeks. After two months, closure of the FTMH was noted under OCT (Figure 4), with improved BCVA to 0.5. Fundus showed re-attached retina and inferior retinal scar (Figure 5).

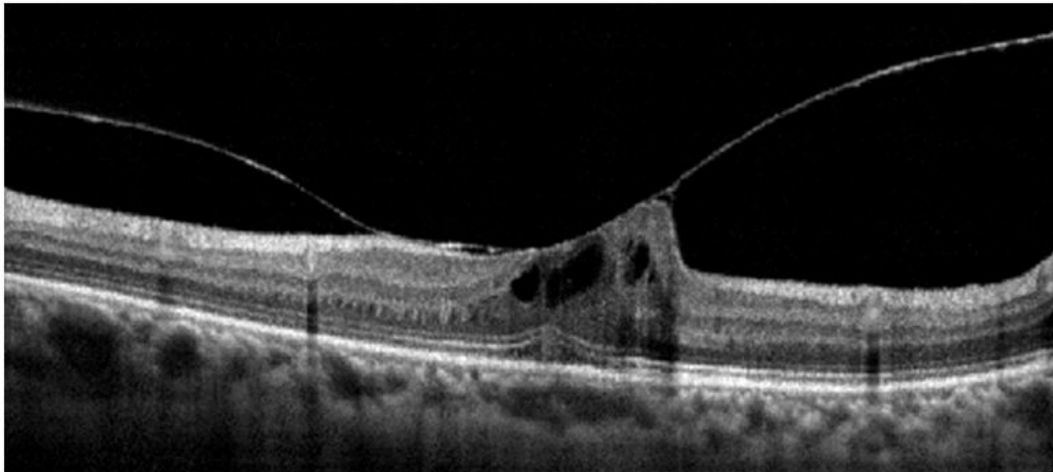


Figure 1: Optical coherence tomography showing vitreomacular traction

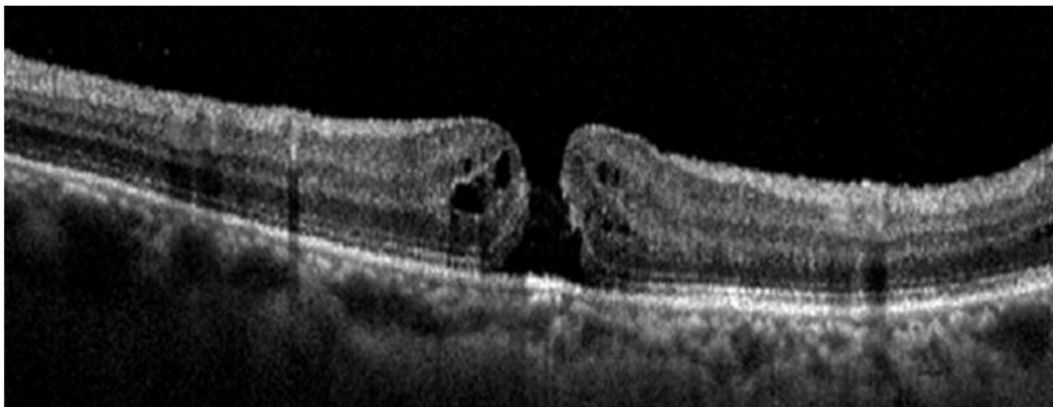


Figure 2: Optical coherence tomography showing a full-thickness macular hole following intravitreal injection of perfluoropropane and face-down posturing for treatment of vitreomacular traction.

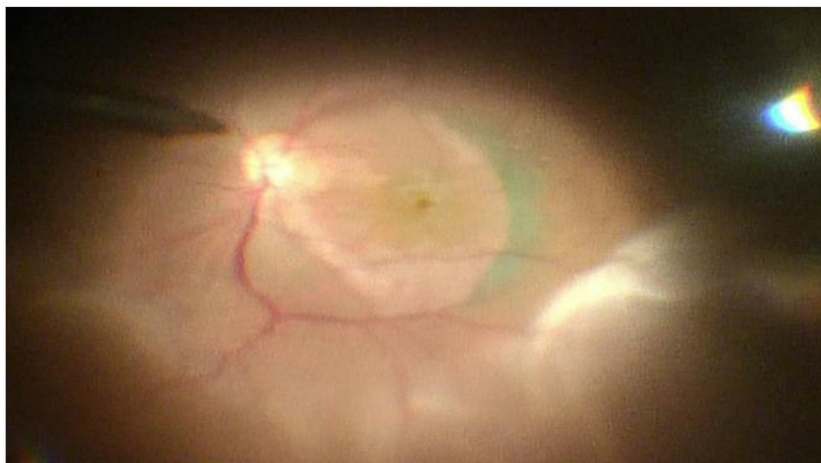


Figure 3: Intraoperative findings showing inferior retinal detachment and internal limiting membrane peeling around the full-thickness macular hole with diluted indocyanine green staining during vitrectomy.

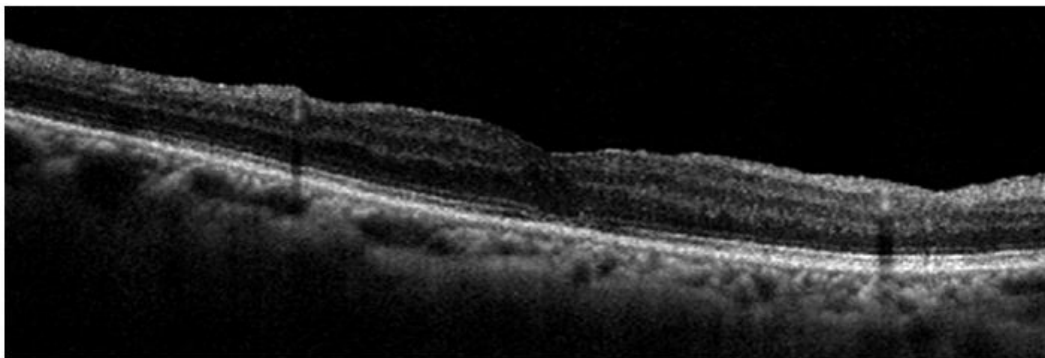


Figure 4: Closure of the full-thickness macular hole without submacular fluid after the surgery

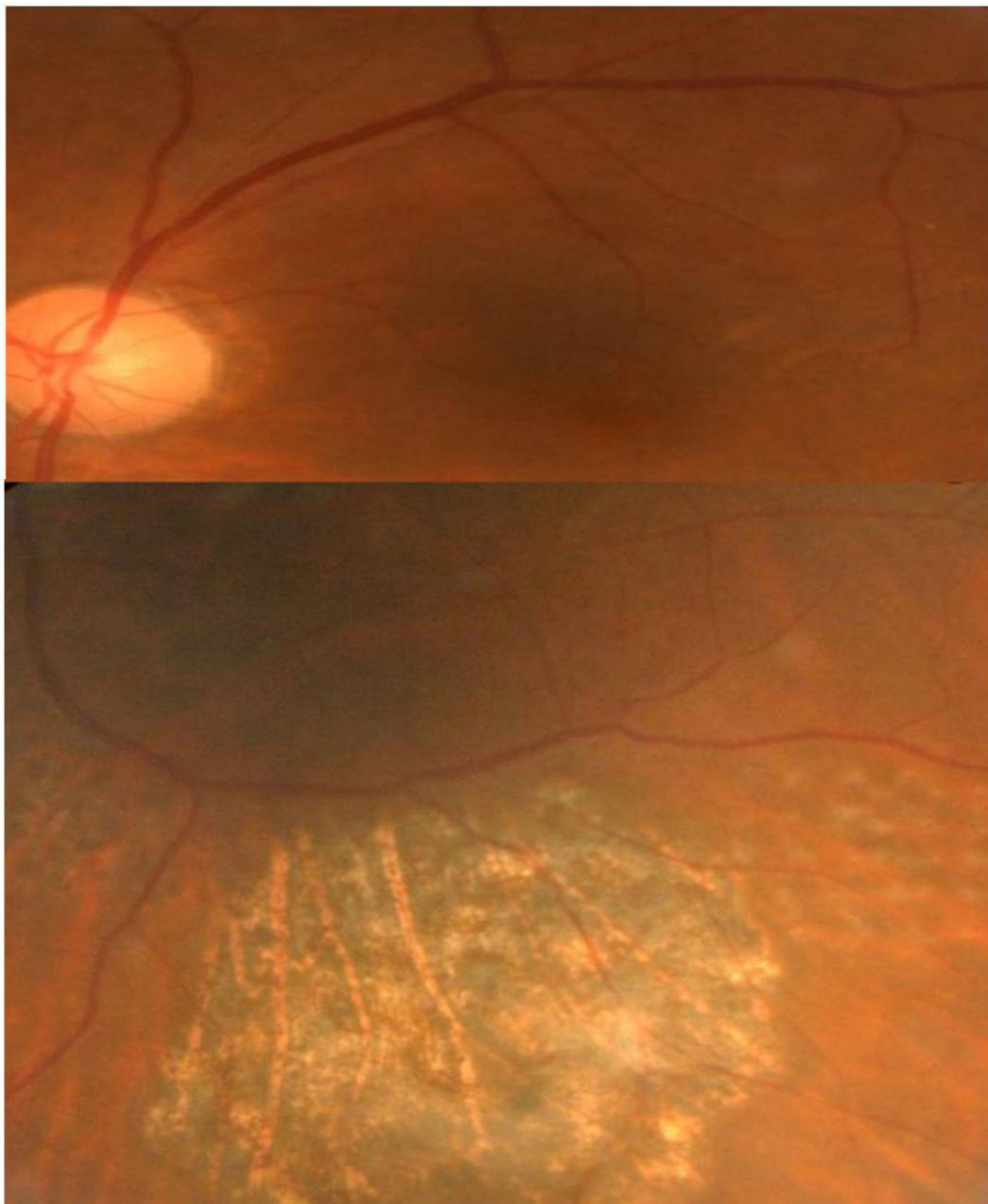


Figure 5: Fundus showing re-attached retina and inferior retinal scar as previous retinotomy during vitrectomy

Discussion

According to previous studies, a period of observation for at least three months was suggested, but VMT only resolve spontaneously and develop complete PVD in about 10% of cases, while around 25% of them will progress and develop macular hole, accompanied by deteriorating visual acuity [1]. The standard intervention is PPV,

which remove the residual adhesion between vitreous and macula completely [2]. The meta-analysis revealed 9.2% lost visual acuity, 11.7% were unchanged, and 64.3% improved of 392 eyes with VMT after vitrectomy [2]. Mean logMAR visual acuity improved from 0.67 to 0.42 following the surgeries. However, patients undergoing surgery possess risks of intraoperative and postoperative complications, such as cataract, epiretinal membrane, endophthalmitis, and retinal detachment. Thus, surgical intervention was limited for those with symptomatic VMT [1,3].

Ocriplasmin, a recombinant form of human serine protease plasmin, is a pharmacologic vitreolysis agent that lysis laminin and fibronectin, both of which are important components of vitreomacular interface. The efficacy and safety of ocriplasmin had been evaluated in two phase 3 clinical trials [3]. The results showed that the rate of VMA or VMT resolution, total PVD, and nonsurgical closure of FTMH are all higher in ocriplasmin-treated patient comparing to the placebo group. Besides, in patients meeting four positive predictive criteria (younger than 65 years old, no epiretinal membrane presented at baseline, size of vitreous attachment area < 1500 μ m, and phakic lens status), higher response rate of 75% was noted. The pharmacologic vitreolysis needs only single injection of ocriplasmin and the treatment benefits was observed across all treatment subgroups analyzed in the later studies [3-6]. Important safety-related problems were not observed, with most adverse events (floaters and photopsia) were related to development of complete PVD [3,5,6].

Pharmacologic vitreolysis with ocriplasmin costs about 6,600 US dollars in Taiwan and is not paid by the national health insurance. Therefore, our case chose intravitreal perfluoropropane injection. According to a case series of fifteen eyes with VMT, 40% of VMT were released in one month, another 20% of them had resolution within six months after intravitreal perfluoropropane injection [7]. There were no associated adverse events reported in two case series [7,8]. However, the patient developed FTMH and tractional retinal detachment possibly due to excessive tractional force of intravitreal gas in this report. Therefore, surgeons performing this procedure must be aware of the complications.

The patient then underwent PPV with ILM peeling, which is the current standard procedure for treating FTMH, with closure rates of 90% to 100% were reported [4]. ILM peeling is a traumatic procedure that may injure underlying retinal nerve fiber layer, causing temporary swelling of arcuate nerve fiber layer. However, it is a transient feature that does not affect visual recovery. Previous studies had compared FTMH patients undergoing PPV with and without ILM peeling, which showed that no significant difference in distance visual acuity improvement at six months between two groups, while earlier visual improvement and higher primary closure percentage in the ILM peeling group were noted [4]. Therefore, ILM peeling offers more favorable cost-effectiveness comparing with not peeling ILM in FTMH surgery. Our patient also had FTMH closure and subsided retinal detachment after PPV, ILM peeling, and long-acting gas tamponade.

In conclusion, pharmacologic vitreolysis with ocriplasmin for vitreomacular traction is a safe option with proven efficacy, while vitrectomy with internal limiting membrane peeling would be surgical treatment of choice if resolution is not achieved within one month. Intravitreal perfluoropropane injection is an alternative choice of intervention for VMT, but surgeons must be aware of development of possible complications.

References

1. Amoaku W, Cackett P, Tyagi A, Mahmood U, Nosek J, Mennie G, Rumney N. Redesigning services for the management of vitreomacular traction and macular hole. *Eye (Lond)* 2014 Jul;28 Suppl 1:S1-10.
2. Jackson TL, Nicod E, Angelis A, Grimaccia F, Prevost AT, Simpson AR, Kanavos P. Pars plana vitrectomy for vitreomacular traction syndrome: a systematic review and metaanalysis of safety and efficacy. *Retina* 2013 Nov-Dec;33(10):2012-7.
3. Haller JA, Stalmans P, Benz MS, Gandorfer A, Pakola SJ, Girach A, Kampik A, Jaffe GJ, Toth CA. Efficacy of intravitreal ocriplasmin for treatment of vitreomacular adhesion: subgroup analyses from two randomized trials. *Ophthalmology*. 2015 Jan;122(1):117-22
4. García-Layana A, García-Arumí J, Ruiz-Moreno JM, Arias-Barquet L, Cabrera-López F, Figueroa MS. A review of current management of vitreomacular traction and macular hole. *J Ophthalmol* 2015;2015:809640.
5. Jackson TL, Nicod E, Simpson A, Angelis A, Grimaccia F, Kanavos P. Symptomatic vitreomacular adhesion. *Retina*. 2013 Sep;33(8):1503-11.
6. Yan F, Xia FJ, Jiang F, Yu HG. Visual and morphological outcomes of vitreomacular traction syndrome in retinitis pigmentosa treated by vitrectomy. *Int J Ophthalmol* 2018;11(8):1411-1415.
7. Rodrigues IA, Stangos AN, McHugh DA, Jackson TL. Intravitreal injection of expansile perfluoropropane (C3F8) for the treatment of vitreomacular traction. *Am J Ophthalmol* 2013 Feb;155(2):270-276.
8. Sun P, Tandias RM, Yu G, Arroyo JG. Spectral domain optical coherence tomography findings and outcome after treatment for vitreomacular traction. *Retina* 2018 Mar 27. [Epub ahead of print]

Submit your next manuscript to Annex Publishers and benefit from:

- ▶ Easy online submission process
- ▶ Rapid peer review process
- ▶ Online article availability soon after acceptance for Publication
- ▶ Open access: articles available free online
- ▶ More accessibility of the articles to the readers/researchers within the field
- ▶ Better discount on subsequent article submission

Submit your manuscript at
<http://www.annepublishers.com/paper-submission.php>