

Treatment of Acute Corneal Hydrops with Full-thickness Penetrating Subtotal Keratoplasty (PKP): Clinical Case

Zolotorevskiy AV*, Dementiev DD, Loskutov IA, Larionov EV, Zolotorevskiy KA and Shipunova AV

Eyebank ILab, Moscow, Russia

*Corresponding author: Zolotorevskiy AV, Eyebank ILab, Moscow, Russia, Tel: +7 916 324 04 05, E-mail: avz148@yandex.ru

Citation: Zolotorevskiy AV, Dementiev DD, Loskutov IA, Larionov EV, Zolotorevskiy KA, et al. (2019) Treatment of Acute Corneal Hydrops with Full-thickness Penetrating Subtotal Keratoplasty (PKP): Clinical Case. J Ophthalmol Eye Care 2(1): 104

Abstract

The article is devoted to the description of the successful treatment of acute keratoconus by the method of full-thickness penetrating subtotal keratoplasty (PKP). The diagnosis of acute hydrops was made on the basis of clinical and functional methods, including optical coherence tomography (OCT). The removed part of the pathologically changed cornea was subjected to light microscopy. These studies revealed the morphological changes in virtually all layers of the cornea. Comparison of the data of OCT and morphological studies showed that indications for PKP in this particular patient were adequately selected. The article cites contemporary literary information about the epidemiology of this rare disease, its pathogenesis, which is based on the rupture of the Descemet's membrane and the impregnation of the stroma of the cornea with intraocular moisture. The existing methods of treatment of the hydrops are aimed at the removal of inflammation of the cornea with the subsequent restoration of the integrity of the endothelial descemet reservoir and drainage of stromal cysts to optimize the conditions for healing the cornea. In this particular case, PKP was performed in connection with the substantial thinning of the patient's cornea and the risk of its rupture. As the donor material during the operation, the "the bio-material for the restoration of the cornea" of the Eye Bank "iLAB" was used.

Keywords: Keratokonus; Cornea; Keratoplasty; Hydrops; Eye Bank

Introduction

Patient B referred to the clinic complaining about a sudden reduction of visual acuity of his left eye and overall impaired vision of his right eye.

According to the patient, OU could not see clearly for the past 5-6 years with the left eye keratoconus 1-2 stage (Amsler) and the right keratoconus 2 stages (Amsler) that was diagnosed 3 years ago. No therapy was received; refraction corrected with Soft contact lenses (SCL) and glasses.

The patient further reported of a sudden drop in visual acuity of the right eye for no apparent reason 7 weeks ago, the eyeball reddened with painful sensation in the region of the right orb. The patient referred for treatment to a local eye surgery clinic.

Upon admission: OD – moderate mixed injection, conjunctival hyperemia, cornea hydropic in every layer and practically throughout the entire surface, optical section considerably incassate. Anterior chamber intact, fluid clear with deeper media hidden (Figure 1).

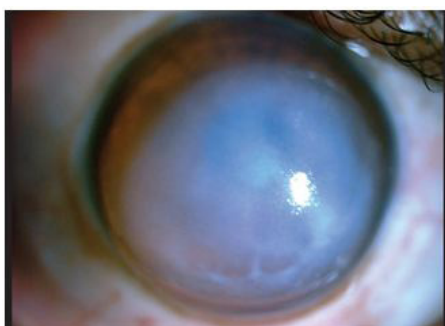

Figure 1: Photograph of right eye front surface of Patient D

OS – steady, media transparent, fundus without irregularities. UCVA OD – 0.01-0.02, OS - 0.5 with sph -1.0 cyl -2.5 ax 160=0.9; IOP OD (palpably) – normal, OS – 19. Ultrasonic corneal pachymetry (CWF) at the center: OD – 923 nm, OS – 480 nm. OTC OS – no structural peculiarities. Cornea in the right eye is increased across the entire surface. The corneal stroma, mostly at the center, has wide paracentral cysts (cavities) of irregular shape filled with acoustically transparent homogeneous fluid with a thinning of 170-100 nm above the cysts zone (Figure 2).

Diagnosis: OD acute keratoconus, OS keratoconus 1-2 stage.

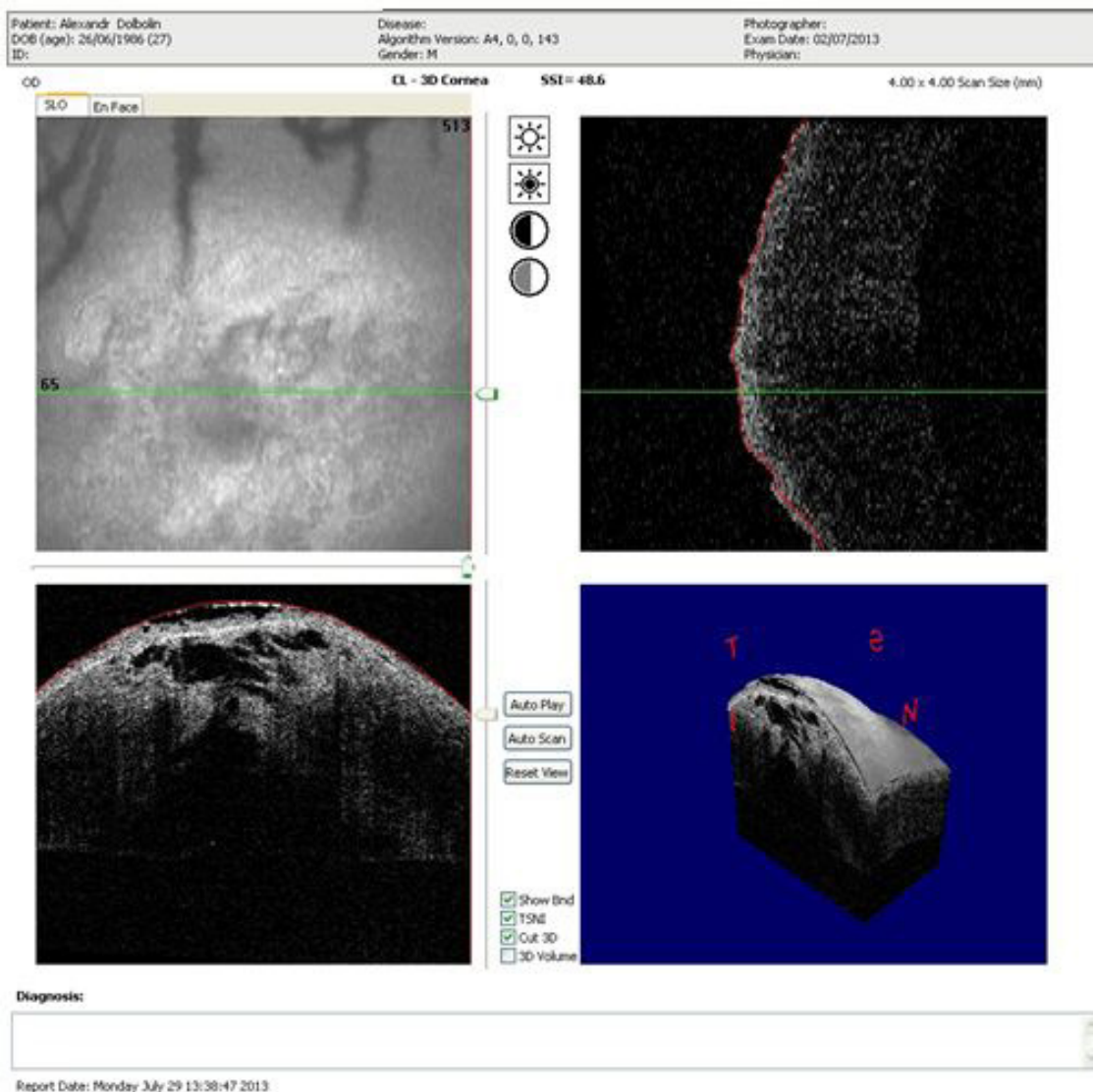


Figure 2: OCT results (Name of equipment and software used)

Methods

Outlined functional data show wide cavities in the corneal stroma, with front corneal surface of the central optical zone deformed, paracentral segments hydropic, increased, stromal structure aberrant.

Considering the significant thinning in the right eye cornea (up to 100 nm) and the high risk of perforation in the zone of the stromal cysts, it has been decided to perform a cut-through subtotal PKP.

The surgery was carried out on 2013-07-05 by an eye surgeon, Loskutov, I.A., using “the bio-material for the restoration of the cornea” produced by “iLAB” as a grafting tissue. No irregularities were observed during both the surgical operation and the immediate postoperative period. BCVA of the operated eye after a month–0.2. The patient continued to receive conservative therapy.

Histomorphological study of the patient’s corneal tissue sampling showed that the cornea is extremely hydropic, with morphological aberrations present at every layer (Figure 3,4 and 5).

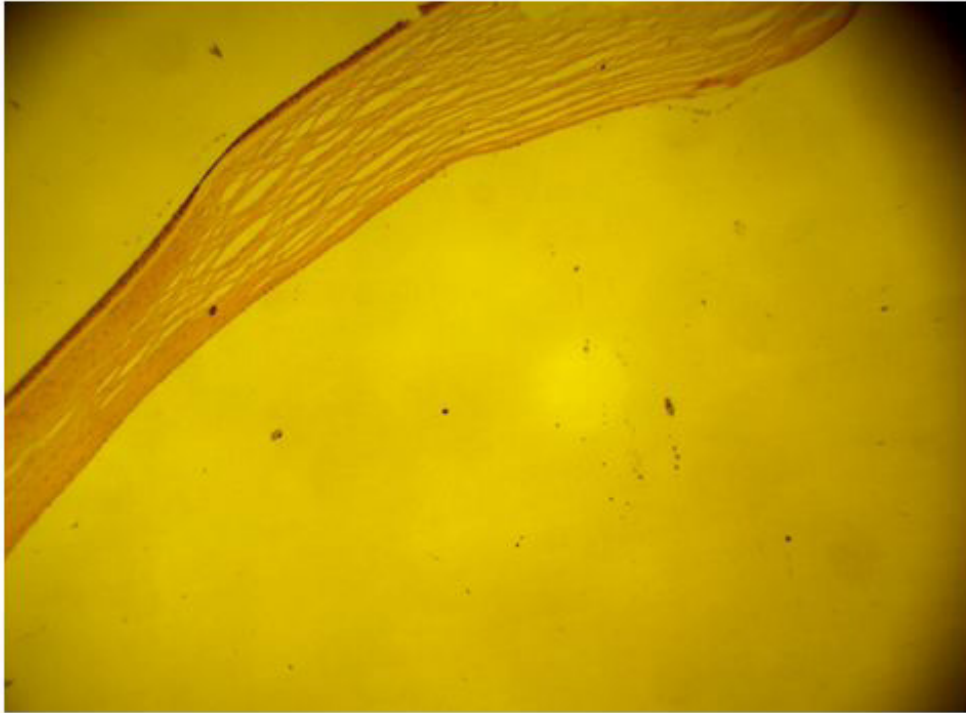


Figure 3: Histomorphological picture of a corneal section, patient D, 27 y.o. corneal stroma is highly thinned near the optical zone. The Bowman's membrane is largely deformed. Magnified 100 times. H&E stain.

The keratoconic aberrations become more visible as we zoom in.




Figure 4: Histomorphological picture of a corneal section, Patient D, 27 y.o. epithelial tissues thinned, its cells deformed. The Bowman's membrane is extremely deformed. Magnified 140 times. H&E stain.

Epithelium has few layers, particularly near the optical zone, with multiple diseased and dead cells at different layers. The Bowman's membrane is deformed throughout, inhomogeneous in thickness and density.

Collagen layers of corneal stroma are defibrated. Figure 4 Shows a section of a largely hydropic stroma with a clear defibration of

collagen fascicles. Cyst-like strips are formed in proximity to the intact tissues. Stromal fibroblasts are deformed, in some layers apoptotic. Posterior layers of the cornea show keratoconus-specific aberrations.




Figure 5: Histomorphological picture of a corneal section, patient D, 27 y.o. endothelial tissues is mostly fragmented, detached throughout. The Descemet membrane is extremely aberrant, partially missing. Magnified 240 times. H&E stain

Posterior layers of the cornea adjacent to the Descemet membrane show total structural damage. The endothelium in the undamaged sections of the membrane is fragmented, mostly absent. Surgically removed corneal disk of Patient D, 27 y.o., is completely inoperative, both morphologically and functionally.

Therefore, morphological studies show that the surgical treatment was performed opportunistically and in a timely manner: a conservative relief of the degenerative process in the patient's cornea diagnosed with keratoconus would not restore the transparency of the tissue due to irreversible aberrations in every layer of the cornea.

Acute keratoconus, acute hydrops are rare complications associated with keratoconus. It is believed that only 3% of all keratoconus patients develop this condition, and as a rule, it is the eye with the higher visual functions that is affected. It has been shown, that neither gender nor age contributes to the rate of development of this rare condition. However, it is highly likely to be attributable to the ethnicity of the patient, South-Asian genotype having the highest risk of being affected [5,6].

It has also been demonstrated that in patients with acute keratoconus, hyperemia of the eyeball is caused not only by the inflammation of a degenerative and aberrant corneal tissue, but also by a bacterium – *Serratia marcescens* – found in the conjunctival sac. This organism is a species of rod-shaped gram-negative bacteria in the family Enterobacteriaceae, which can cause non-inflammatory or slightly inflammatory hyperemia of the eyelid skin due to the secretion of red pigment.

The pathogenesis of acute keratoconus is determined by a rupture in the endothelial-cum-Descemet layer resulting in the saturation (permeation) of the corneal stroma with the fluids of the anterior chamber, and a subsequent formation, inside the stroma, of large cysts filled with liquid. This process is clinically manifested in the development of an incassate corneal leukoma, the size of which depends on the location and the size of the rupture. Consequently, if no adequate treatment is received, and provided that the outer layer of the cornea is not broken (which in turn may be enhanced by consecutive infection, or reinfection), these leukomas become vascularized due to the vascular ingrowth into the limb zone.

The causes of the Descemet membrane damage remain unclear. However, it is believed to be associated with immunity disorders and particularly with the increase of the IgE titer. This claim is indirectly confirmed by the research demonstrating that keratoconus patients have a statistically significant concurrence of such diseases as rhinoconjunctivitis, asthma, and eczema, all of which are related to the increase of this antibody titer [1-3,6].

In our case, no broken segments of the Descemet-cum-endothelial layer have been identified morphologically. However, the significant decrease in the density of the endothelial cells could be the course of aberrations similar to hydrops [Figure 5].

There are two modern approaches to treating keratoconus: surgical and conservative. The latter is related to the idea that the damaged Descemet's membrane can heal spontaneously, with the subsequent dissolution of the cystic content. In such cases, the patients are prescribed topical anti-inflammatory therapy including steroid eye-drops, prostaglandin antagonists (inhibitors), and wearing SCL as a kind of bandage. There are references to successful cases of using this methodology in specialized literature. However, this treatment usually takes up to 6-7 months and does not ensure complete restoration of visual acuity due to residual opaque spots in the cornea [1,2,4].

Surgical methods of treating corneal hydrops descend from the attempts to tampanade the rupture of the Descemet-cum-endothelial layer in the anterior chamber with gases. Some authors believe, that injecting a bulb of a dissolving gas C3F8 is the most effective and short-term method. Tampanade can be enhanced by partial paracenteses in order to accelerate the process of draining the cystic cavities. It should be noted, however, that injecting a slow-dissolving gas can itself cause epithelial and endothelial dystrophy of the cornea. Besides, it has been shown histologically that ruptures of the Descemet's membrane often take a peculiar course: the edges of the membrane curl in the form of scrolls and cannot smooth out by themselves to close the gap. Therefore, it has been suggested that such patients should be treated with posterior keratoplasty. However, this surgical method may not be applied due to the lack of transparency in the cornea [4-6].

Results

In the case under consideration, taking into account several factors, the authors have decided to perform cut-through subtotal penetrating keratoplasty.

Discussion

First, the increasing thinning of the cornea above the cystic zone could lead to the perforation of the stroma and the formation of a corneal fistula. Second, the development of a large leukoma pointed to the presence of an extensive defect in the Descemet's membrane, which seemed highly unlikely to close spontaneously. Third, conservative and palliative therapies usually require prolonged rehabilitation periods and do not fully ensure considerable increase in visual acuity, particularly in case residual nebulae remain in the central optical zone.

Conclusion

The application of the "bio-material for the restoration of the cornea" produced by "iLAB" for cut-through PKP proved highly effective in carrying out scheduled eye-surgeries. This particular clinical case also confirms effectiveness of the technology in carrying out urgent interventions.

References

1. Fan JC, Good WR, Patel DP, McGhee CN (2013) The Auckland keratoconus study: Identifying predictors of acute corneal hydrops in keratoconus. *Clin Exp Optom* 96: 208-13.
2. Lindsay R (2013) Special Keratoconus. *Clin Exp Optometry* 208-13.
3. Ueno H, Matuzawa A, Kumagai Y, Takagi H, Ueno S (2012) Imaging of a Severe Case of Acute Hydrops in a Patient with Keratoconus Using Anterior Segment Optical Coherence Tomography. *Case Rep Ophthalmol* 3: 304-10.
4. Ueno H, Matuzawa A, Kumagai Y, Takagi H, Ueno S (2013) Imaging of a Severe Case of Acute Hydrops in a Patient with Keratoconus Using Anterior Segment Optical Coherence Tomography. *Case Rep Ophthalmol* 3: 304-10.
5. Blodi FC, Bralev AE. Acute keratoconus.
6. Lyon F, Anderson SB, Ellingham RB (2007) Acute hydrops in a corneal graft for keratoconus. *Eye* 21: 1130-1.

Submit your next manuscript to Annex Publishers and benefit from:

- ▶ Easy online submission process
- ▶ Rapid peer review process
- ▶ Online article availability soon after acceptance for Publication
- ▶ Open access: articles available free online
- ▶ More accessibility of the articles to the readers/researchers within the field
- ▶ Better discount on subsequent article submission

Submit your manuscript at
<http://www.annexpublishers.com/paper-submission.php>