

# Management of Postoperative Pain in Patients Undergoing Surgery for Mandibular Fracture

Zineb G<sup>\*1</sup> and Slimani F<sup>1,2</sup>

<sup>1</sup>Department of Stomatology and Oral and Maxillo-facial Surgery, Hospital 20 Août, CHU Ibn Rochd, Casablanca, Morocco

<sup>2</sup>Faculty of Medicine and Pharmacy, Hassan II University of Casablanca, Morocco

**\*Corresponding author:** Zineb G, Department of Stomatology and Oral and Maxillo-facial Surgery, Hospital 20 Août, CHU Ibn Rochd, Casablanca, Morocco, Tel: 00212661197852, E-mail: zinebgallaoui@hotmail.fr

**Citation:** Zineb G, Slimani F (2017) Management of postoperative pain in patients undergoing surgery for mandibular fracture. *J Surg Oper Care* 2(1): 103. doi: 10.15744/2455-7617.2.103

**Received Date:** August 24, 2017 **Accepted Date:** October 24, 2017 **Published Date:** October 26, 2017

## Abstract

The mandible is one of the most frequently fractured bones in the facial skeleton. Postoperative pain control is an important outcome in assessing overall treatment success and patient satisfaction. However, few focused studies have reviewed protocols for postoperative pain management in patients with mandibular trauma. The aim of this study is to evaluate the protocol for the management of postoperative pain in patients undergoing surgery for mandibular fracture in our department.

**Method:** We performed a prospective study of pain management in 24 adult patients who had oral procedure surgery for mandibular fracture of the tooth portion between November 1st and December 31, 2016. These patients had an analgesic combination of paracetamol and corticosteroids. A regular evaluation of postoperative pain using the analog visual scale was carried out over a month of follow-up.

**Results:** The average age of our patients was 29 years, with a clear male predominance. The trauma was due to aggression in 54.1% of cases, followed by brawls (29.16%) and road accidents (16.6%). The average hospital stay was 2.91 days. Compliance was good in all patients and no side effects were reported. Pain reported by patients was mild to moderate in the first week after surgery, then zero to postoperative day 14 and postoperative day 30.

**Conclusion:** The evaluation of our protocol suggests that this combination was sufficient in the management of postoperative pain in patients operated for mandibular fracture.

**Keywords:** Postoperative pain; Mandibular fracture

## Introduction

The mandible is one of the most frequently fractured bones in the facial skeleton [1]. Restoration of ormalocclusion, bite function, and facial symmetry are the goals of mandibular fracture treatment [2]. Successful treatment is also judged by the avoidance of functional limitations, including pain with mouth opening [3].

Postoperative pain control is an important outcome in assessing overall treatment success and patient satisfaction. With multiple agents available and novel combination strategies and patient factors to consider, clinicians must choose how to best manage pain in the immediate postoperative period [4,5].

Unlike other dentoskeletal procedures, specifically orthognathic surgery [6,7] or third molar extraction [4,5] few focused studies have reviewed protocols for postoperative pain management in patients with mandibular trauma [8].

A study of pain as an outcome after surgery ideally reports the specific type of analgesics given, uses validated pain assessments, and reports adverse effects related to the agent prescribed.

The aim of this study is to evaluate the protocol for the management of postoperative pain in patients undergoing surgery for mandibular fracture in our department. Is the combination of paracetamol and corticosteroids sufficient or should we prescribe another type of analgesic, especially a step 2?

## Methods

We carried out a prospective study of pain management in patients operated for mandibular fracture between November 1, 2016 and December 31, 2016. Of the 39 patients operated during this period, we excluded from our study all patients undergoing condylar fracture, patients with other associated facial fractures, pathological fractures, patients under 16 years of age, and those with psychiatric conditions.

Finally, there were 24 patients (23 males/ 1 female) who had monofocal (12 patients) or bifocal mandibular fracture (12 patients). They all had an intraoral approach. We explained to them the protocol of management and evaluation of the pain with a minimum follow-up of 1 month. It consisted in the administration of Paracetamol at a rate of 1 g every 6 hours for 5 days and corticosteroids (prednisolone) at 2 mg / kg / day for the first 24 hours, then at a rate of 1 mg / kg / day during 5 days, associated with gastric protection and an antibiotic prophylaxis (amoxicilline + clavulanic acid).

Administration of the drugs was intravenous in the first 24 hours, followed by an orally administration. A visual analogue scale (VAS) pain assessment was performed in all patients in postoperative hour 2, hour 4, hour 6, hour 12, day 1, day 3, day 7, day 14, and day 30. Statistical analysis was performed using Epi Info 7.0.

## Results

The average age of our patients was 29 years, with a clear male predominance (23 patients out of 24). 58.3% of our patients were chronic smokers, 12.5% were alcoholics and 12.5% were regular cannabis users (Figure 1). The circumstances of the trauma were represented by aggression in 54.1% of cases, followed by brawls (29.16%) and road accidents (16.6%). The average take-up time was 8.7 days. Fractures were located at the mandibular angle in 70% of cases, symphysis in 54% of cases, parasymphysis in 12.5% of cases, and the body in 12.5% of cases (Table 1). The average hospital stay was 2.91 days. Compliance was good in all patients and no side effects were reported. Pain reported by patients was mild to moderate with an average of 0.58 to hour 2, 1.54 to hour 4, 2.54 to hour 6, 2.41 to hour 12, 1.16 to day 1, 0.6 to day 3, from 0.1 to day 7, then zero to day14 and day 30. One of the patients reported pain estimated at 5 according to the EVA at post-operative day 3. This was related to a hematoma. The drainage reduced the pain threshold to 3 (Table 2). There was no statistically significant difference between patients with monofocal fracture or those with bifocal fracture ( $p=0,072 > 0,05$ ). (Table 3) Toxic habits also had no impact on the intensity of pain ( $p=0,463 > 0,05$ ) (Table 4).

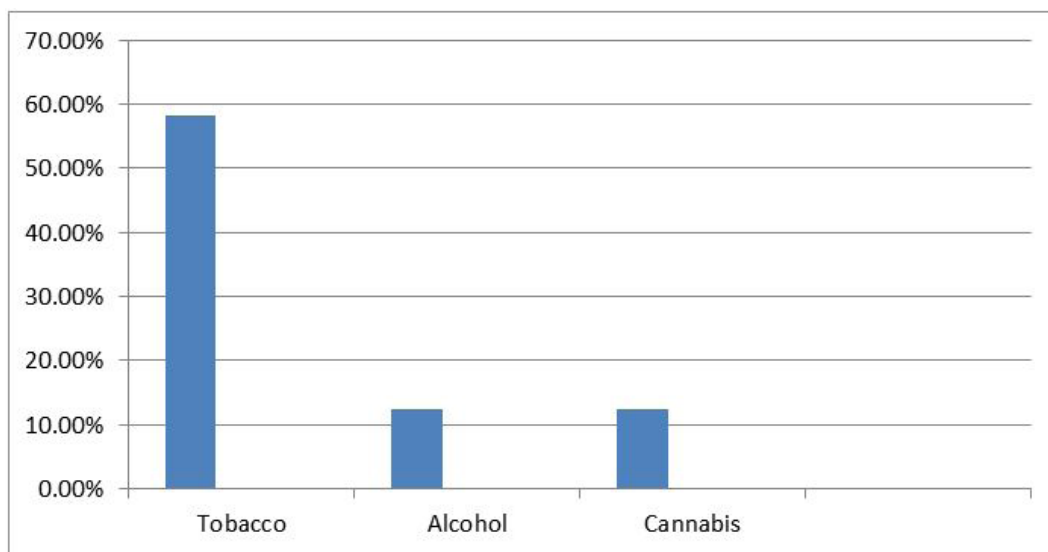


Figure 1: Toxic habits

Site of fracture	Percentage
Symphysis	12,5%
Parasymphysis	54%
Horizontal branch	12,5%
Angle	70%

Table 1: Fracture site

Patients	VSA H2	VSA H4	VSA H6	VSA H12	VSA D1	VSA D3	VSA D7	VSA D14	VSA D30
1	0	1	2	3	2	1	0	0	0
2	0	2	4	3	3	2	0	0	0

Patients	VSA H2	VSA H4	VSA H6	VSA H12	VSA D1	VSA D3	VSA D7	VSA D14	VSA D30
3	0	2	3	4	2	5	3	0	0
4	0	1	3	3	1	0	0	0	0
5	0	1	2	2	1	0	0	0	0
6	0	2	2	2	0	1	0	0	0
7	1	0	3	2	0	1	0	0	0
8	2	2	3	3	2	1	0	0	0
9	0	1	2	2	0	0	0	0	0
10	1	0	3	2	1	1	0	0	0
11	0	3	3	3	1	0	0	0	0
12	3	4	2	3	2	1	0	0	0
13	2	1	3	3	0	0	0	0	0
14	0	2	3	2	2	1	0	0	0
15	2	3	4	4	3	0	0	0	0
16	0	2	2	2	0	0	0	0	0
17	0	3	3	2	1	0	0	0	0
18	1	1	2	3	1	1	0	0	0
19	0	0	2	1	0	0	0	0	0
20	0	0	1	2	0	0	0	0	0
21	1	3	3	2	2	0	0	0	0
22	0	2	3	2	1	0	0	0	0
23	0	1	2	2	2	1	0	0	0
24	1	0	1	1	2	0	1	0	0
<b>Average</b>	<b>0,58</b>	<b>1,54</b>	<b>2,54</b>	<b>2,41</b>	<b>1,16</b>	<b>0,6</b>	<b>0,1</b>	<b>0</b>	<b>0</b>

Table 2: Pain evaluation

Overall average pain								
	N	Average	Standard deviation	Standard error	The average from confidence interval to 95%		Minimum	Maximum
					Lower bound	Upper bound		
<b>Monofocal</b>	12	,8519	,48161	,13903	,5459	1,1579	,33	2,11
<b>Bifocal</b>	12	1,1759	,34640	,10000	,9558	1,3960	,78	1,78
<b>Total</b>	24	1,0139	,44240	,09030	,8271	1,2007	,33	2,11

$p=0,072 > 0,05$

Interpretation: statistically insignificant difference. The mean pain score is not different between the "monofocal fracture" and "bifocal fracture" group

Table 3: Site of fracture

Overall average pain								
	N	Average	Standard deviation	Standard error	The average from confidence interval to 95%		Minimum	Maximum
					Lower bound	Upper bound		
<b>Non</b>	10	,9333	,48630	,15378	,5855	1,2812	,33	1,78
<b>Oui</b>	14	1,0714	,41712	,11148	,8306	1,3123	,56	2,11
<b>Total</b>	24	1,0139	,44240	,09030	,8271	1,2007	,33	2,11

$p=0,463 > 0,05$

Interpretation: statistically insignificant difference. The mean score of the pain is not different between the group of patients with toxic habits of those who do not.

Table 4: Toxic habits

## Discussion

Postoperative pain remains a basic problem in surgical patient management. Postoperative pain has been reported to be present in up to 77% of surgical patients, with 80% of these individuals having moderate to severe pain [9].

High levels of acute postoperative pain have been reported to be associated with slower recovery of function, increased length of hospital stay, and perioperative complications [10].

In general, patients with mandibular fracture undergo equally or more extensive surgery, are more likely to be impoverished or have mental illness, and are more likely to be malnourished and abuse alcohol, tobacco, or illicit drugs than patients undergoing other orofacial procedures [11,12]. Given the possibility of nicotine-related analgesic effects, one might hypothesize that smokers in pain would require less analgesic medication than nonsmokers. However, research indicates that this is not the case. In fact, smokers in pain appear to use substantially more analgesic medication than nonsmokers [13]. In two postoperative pain trials using cannabis (levonantradol) was superior to placebo [14]. Girona and al [11] reported that pain levels were a predictor of postoperative depression symptoms in patients after mandibular fracture repair. This added patient morbidity can result in a vicious cycle, with pain levels harder to assess and control. Adherence to treatment, quality of life, and time to full recovery may be affected [15].

The establishment of an analgesic plan that is based on guidelines and medical evidence is important for effective pain management. The aim of postoperative pain management should not be complete pain relief but, rather, a stable state of pain control. Reduction of approximately 30-35% in pain intensity was reported to be necessary in order to achieve a clinically measurable change [16]. Another study, in which the VAS was investigated as a predictor of clinically important change after removal of third molars, revealed that even an absolute reduction of VAS by 2.5 mm is a strong predictor of an adequate analgesic treatment [17]. In addition, the timing of pain management, in particular early administration of analgesic treatment, is important for pain control and its prognosis [18].

Although good surgical technique is a given, all surgery creates injury to the soft and hard tissues. The inflammatory response to injury is the key to the development of pain and eventually swelling after any surgery. The more difficult the surgery, the more likely the patient will experience pain, swelling and trismus. The prevention of inflammation and, thus, swelling is the goal of reducing postoperative pain [19].

Corticosteroids have been the most common medications used to treat and prevent swelling and edema after surgery. The administration of corticosteroids in the preoperative period via the parenteral route has the greatest impact on reducing postoperative swelling and trismus [20].

Comparing corticosteroid (methylprednisolone) administration versus NSAIDs for the relief of pain, swelling, and trismus has also been studied. The preemptive intravenous dosing of these drugs had both a positive and equal impact on postoperative control of pain and swelling. However, the use of methylprednisolone had better relief of trismus [19,20].

Acetaminophen is a centrally acting analgesic and antipyretic. Although acetaminophen is one of the oldest and most widely prescribed analgesic drugs, its analgesic efficiency has been found to be improved by combining it with NSAID medications, such as ibuprofen. These new combination medications or just combining them on your own may obviate or decrease the need for narcotic use in many patients [21,22].

In a literature review of postoperative pain management protocols in patients with mandibular fracture, all studies that reported the type of analgesic administered used paracetamol, some of them (3 out of 5 studies) used it in combination with ibuprofen. None of the studies reported the use of opioids [8]. In our department, we usually use paracetamol in combination with corticosteroids with good results.

## Conclusion

The evaluation of the combination of paracetamol and cortico steroids in the management of postoperative pain in patients operated on for mandibular fracture suggest that this protocol was sufficient, with good adhesion to postoperative rehabilitation.

## Competing Interests

Authors declare they have no conflict of interest.

## References

1. Sharabi SE, Koshy JC, Thornton JF, Hollier LH (2011) Facial fractures. *Plast Reconstr Surg* 127: 25-34e.
2. Nasser M, Pandis N, Fleming PS, Fedorowicz Z, Ellis E, et al. (2013) Interventions for the management of mandibular fractures. *Cochrane Database Syst Rev* 7: CD006087.
3. Alpert B (1998) Management of the complications of mandibular fracture treatment. *Operative Techniques Plast Reconstr Surg* 5: 325-3.
4. Bailey E, Worthington H, Coulthard P (2014) Ibuprofen and/or paracetamol (acetaminophen) for pain relief after surgical removal of lower wisdom teeth: a Cochrane systematic review. *Br Dent J* 216: 451- 5.
5. Joshi A, Parara E, Macfarlane TV (2004) A double-blind randomised controlled clinical trial of the effect of preoperative ibuprofen, diclofenac, paracetamol with codeine and placebo tablets for relief of postoperative pain after removal of impacted third molars. *Br J Oral Maxillofac Surg* 42: 299-306.
6. Oncül AM, Cimen E, Küçükyavuz Z, Cambazoğlu M (2011) Postoperative analgesia in orthognathic surgery patients: diclofenac sodium or paracetamol? *Br J Oral Maxillofac Surg*. 49: 138-41.
7. Dan AE, Thygesen TH, Pinholt EM (2010) Corticosteroid administration in oral and orthognathic surgery: a systematic review of the literature and meta-analysis. *J Oral Maxillofac Surg* 68: 2207-20.
8. Butts SC (2015) Reporting of postoperative pain management protocols in randomized clinical trials of mandibular fracture repair. A systematic review *JAMA Facial Plast Sur* 17: 440-8.

9. Dietrich EM, Griessinger N, Neukam F, Schlittenbauer T (2016) Consultation with a specialized pain clinic reduces pain after oral and maxillofacial surgery. *J Craniomaxillofac Surg* 45: 281-9.
10. Janis JE, Joshi GP (2014) Introduction to “current concepts in pain management in plastic surgery” *Plast Reconstr Surg*. 134: 6-7S.
11. Girona MW, Der-Martirosian C, Belin TR, Black EE, Atchison KA (2009) Predictors of depressive symptoms following mandibular fracture repair. *J Oral Maxillofac Surg* 67: 328-34.
12. Pena I Jr, Roberts LE, Guy WM, Zevallos JP (2014) The cost and inpatient burden of treating mandible fractures: a nationwide inpatient sample database analysis. *Otolaryngol Head Neck Surg*. 15: 591-98.
13. Omeje KU, Rana M, Adebola AR, Efunkoya AA, Olasoji HO, et al. (2014) Quality of life in treatment of mandibular fractures using closed reduction and maxillo-mandibular fixation in comparison with open reduction and internal fixation: a randomized prospective study. *J Craniomaxillofac Surg* 42: 1821- 6.
14. Farrar JT, Young JP Jr, LaMoreaux L, Werth JL, Poole RM (2001) Clinical importance of changes in chronic pain intensity measured on an 11-point numerical pain rating scale. *Pain* 94: 149-58.
15. Martin WJ, Ashton-James CE, Skorpil NE, Heymans MW, Forouzanfar T (2013) what constitutes a clinically important pain reduction in patients after third molar surgery? *Pain Res Manag*. 18: 319-22.
16. Fainsinger RL, Fairchild A, Nekolaichuk C, Lawlor P, Lowe S, Hanson J (2009) is pain intensity a predictor of the complexity of cancer pain management? *J Clin Oncol* 27: 585-90.
17. Drew SJ (2015) Best practices for management of pain, swelling, nausea and vomiting dentoalveolar surgery. *Oral Maxillofac Surg Clin North Am*. 27: 393-404.
18. Herrera-Briones FJ, Prados Sánchez E, Reyes Botella C, Vallecillo Capilla M (2013) Update on the use of corticosteroids in third molar surgery: systematic review of the literature. *Oral Surg Oral Med Oral Pathol Oral Radiol* 116: e342-51.
19. Balley E, Worthington HV, Coulthard P (2014) Ibuprofen and/or paracetamol (acetaminophen) for pain relief after surgical removal of lower wisdom teeth. *Cochrane database systematic rev. Br Dent J* 216:451-5.
20. Qi DS, May LG, Zimmerman B, Peng P, Atillasoy E et al. (2012) A randomized, double-blind, placebo-controlled study of acetaminophen 1000mg versus acetaminophen 650mg for the treatment of postsurgical dental pain. *Clin Ther* 34:2247- 58

Submit your next manuscript to Annex Publishers and benefit from:

- ▶ Easy online submission process
- ▶ Rapid peer review process
- ▶ Online article availability soon after acceptance for Publication
- ▶ Open access: articles available free online
- ▶ More accessibility of the articles to the readers/researchers within the field
- ▶ Better discount on subsequent article submission

Submit your manuscript at

<http://www.annexpublishers.com/paper-submission.php>