

Should the Lateral Chest Radiograph be a Routine Projection in the Diagnosis of Pneumonia in Children: A Narrative Review?

Bell G¹, Kapsambelis R¹ and Chau M^{*1,2}

¹Medical Imaging Department, Flinders Medical Centre, Flinders Drive Bedford Park, South Australia

²School of Health Sciences, University of South Australia, North Terrace, Adelaide, South Australia

*Corresponding author: Chau M, School of Health Sciences, University of South Australia, 108 North Terrace, Adelaide, 5001 South Australia, E-mail: Shayne.Chau@unisa.edu.au

Citation: Bell G, Kapsambelis R, Chau M (2019) Should the Lateral Chest Radiograph be a Routine Projection in the Diagnosis of Pneumonia in children: A Narrative Review? J Adv Radiol Med Image 4(1): 103

Received Date: May 24, 2019 **Accepted Date:** August 27, 2019 **Published Date:** August 29, 2019

Abstract

Background: Chest x-rays (CXR) are frequently used in the diagnosis of pneumonia in pediatrics patient. The lateral projection produces more than double the effective patient dose than the frontal (anterior-posterior (AP)/ posterior-anterior (PA)) projection in CXR series, with potentially little assistance in diagnosing disease.

Methods: The databases MedLine, PubMed, Cochrane and Scopus were searched for peer-reviewed publications regarding the lateral chest projection in the diagnosis of pneumonia in children. Certain key-words and inclusion/exclusion criteria were included. The results were cross-checked by two appraisers for relevance and duplicates removed.

Results: As this study considered only the pediatrics population from recent studies, only 3 studies were included in the review: two retrospective studies and one random control trial. All the studies reviewed agreed that the combined frontal and lateral examinations was able to diagnose more pneumonias than the frontal only examination, however there was disagreement as significance of the amount. The sole study that assessed the impact on the clinical environment found that having the frontal projection only did not significantly change the clinical management of the patients in comparison to both projections. No studies included looked at the efficiency or costs associated with a second projection.

Conclusion: Due to many limitations, more current evidence is necessary before a definitive conclusion can be made and used in a clinical environment.

Keywords: Chest Radiography; Chest X-Ray; Children; Pediatric; Pneumonia

Background

Pneumonia is one of the leading causes of hospitalization for children under 5 years of age in Australia. For every 1000 children, approximately 5-8 are diagnosed with the disease each year [1]. Chest X-rays (CXR) are considered the gold-standard for diagnosis of pneumonia [2] and are therefore a commonly requested examination in Australian Emergency Departments.

Performing CXRs on pediatric patient requires greater skill, patience and technical experience from radiographer. Furthermore, the examination can be highly distressing to these patients and the parents and often requires more staff to correctly immobilize the patient. The WHO currently recommends the use of 2 views in the standard x-ray series: the frontal posterior-anterior (PA) or anterior-posterior (AP) view and the lateral view [3]. Of these two views, the lateral is considered more technically challenging and is associated with a higher repeat rate [3].

For all radiographic examinations, it is important that radiographers adhere to the ALARA (As Low as Reasonably Achievable) principle in regards to patient dose. Limiting patient dose is particularly important in the case of pediatrics x-rays as children are far more sensitive to the damaging effects of ionizing radiation than adults [4]. The lateral CXR is often associated with higher dose to the patient and some studies have found that the estimated dose of a lateral CXR is more than double that of the frontal projection [5].

Despite this the lateral image can be of value in certain situations. Many articles, such as one by Feigin [6], have stated that the lateral projection is able to better clarify some abnormalities by providing additional information. For example, the lateral projection is able to demonstrating areas which are usually superimposed by the mediastinum on a frontal projection. Furthermore, it is able to show small collections in the posterior cost-phrenic angles that may not be visualized on the frontal view. The extra information seen in the lateral image can help to diagnose pathologies such as non-confluent lobar pneumonia in children, pneumoperitoneum and cardiac pseudo aneurysm. The lateral projection is also useful in determining the position of foreign bodies such of surgical implants [7].

With the implications of patient dose, patient welfare, departmental efficiency, and overall costs to the health care system in mind, this literature review aims to investigate whether the lateral CXR is necessary for the routine investigation of pneumonia in pediatric patients. In conducting the review, the objective was to assess the evidence of the diagnostic value of the additional lateral projection compared to the standalone frontal projection in pediatrics (zero to 18) with suspected pneumonia.

Objectives

Research Question

The following research question was developed to help guide further research into this topic:

Are single image x-ray examinations (frontal projection only) as effective as combined Frontal and Lateral examinations at diagnosing pneumonia in pediatric patients?

Study Design

Narrative Review

Materials and Methods

Search Strategy

The search strategy for this narrative review was conducted on using four databases (MedLine, PubMed, Cochrane and Scopus) following the search terms below:

The results were reviewed and relevant studies were initially selected based on title. After the initial search, copies of all potentially relevant articles were obtained and the abstracts were read to determine if the study met the inclusion exclusion criteria. The resulting articles were then put into a table so that any duplicated could be easily identified and removed.

After the initial search, copies of all potentially relevant articles were obtained and the abstracts were read to determine if the study met the inclusion and exclusion criteria. Studies that met the criteria were then read in full and appraised by 2 reviewers (GB & RK); a summary of each article was produced for easier reference. The inclusion and exclusion criteria used in this study are listed below (Table 1).

Inclusion Criteria	Exclusion Criteria
Studies published between 1998 and 2018	Studies published in a language other than English
Studies involving pediatric patient (0-18 years old)	Non-human studies
Original research	Studies involving adult patients (18+ years old)
Peer reviewed research	Letters to the editor, commentaries and case studies
Random control trials and retrospective studies	Literature reviews
	Studies focusing on other pathologies

Table 1: Search Strategies

Studies before 1998 were excluded to ensure the literature reflected more recent practice; a shorter time period would have been desirable however the study was limited by the small number of articles available on this topic.

Results

Search Results

After searching the four databases a total of 24 studies were retrieved. Of these 24 studies, eight were removed as duplicates and upon reviewing the abstracts, a further 13 were removed for not meeting the inclusion criteria. One was removed for being a commentary, one was removed for being a radiological guide, two were removed for being literature reviews, and eight were removed for lack of relevance and one was removed for not having an available English translation. This resulted in a total of three studies to be included in the review: two retrospective studies and one random control trial (RCT) [8-10] (Figure 1).

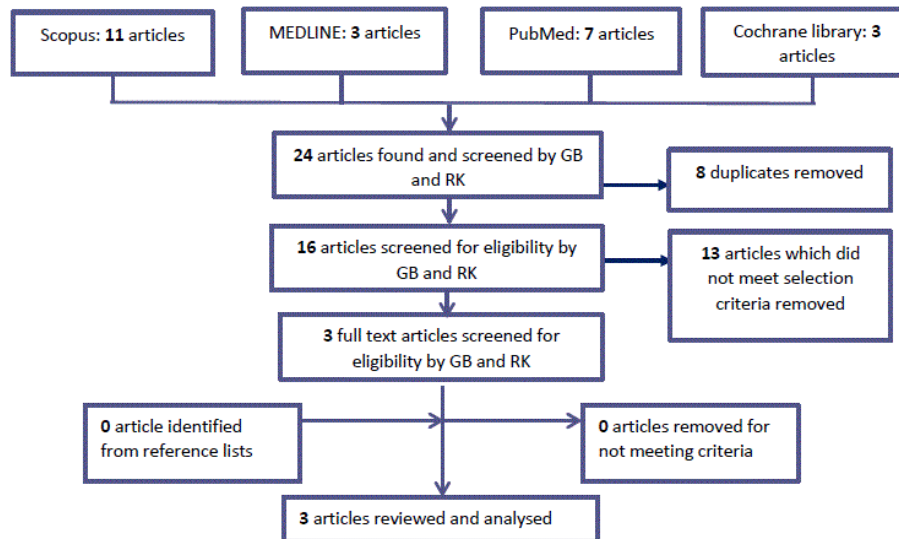


Figure 1: Modified PRISMA Flowchart

Level of Evidence

Only three studies were identified that met the inclusion and exclusion criteria, one RCT and two retrospective studies. The retrospective studies reflected a case control design and were deemed to be level III-2 evidence according to NHMRC (2009) guidelines. Only one of the studies was deemed to be level II, however, due to the overall quality, relevance and consistency this review grades the evidence at level B (Table 2 and 3). Indicating that the body of evidence can be trusted to guide practice in most situations [11].

Category	
Population	Pediatric patient between the ages of 0 – 17 years old who are suspected of having pneumonia
Intervention	Radiographic chest series, Anterior-Posterior (AP) or Posterior-Anterior (PA) projection only
Comparison	Radiographic chest series including both AP or PA and Lateral projections
Outcomes	Definitive Diagnosis of Pneumonia

Table 2: PICO Study Design

Author	Level of Evidence	Grade of Recommendation
Soudack <i>et al.</i> 2018	II	B
Rigsby <i>et al.</i> 2004	III-2	
Lynch <i>et al.</i> 2004	III-2	

Table 3: Level of Evidence of Included Studies

Appraisal of Evidence

The research was appraised by two reviewers (GB &RK) using the QUADAS-2 checklist. Each study showed varied levels of bias with Soudack *et al.* [8] having the highest risk (Table 4). This was largely due to a lack of rigor in testing for both the index test and reference standard. Another issue identified was the short time period used by both Soudack *et al.* [8] and Rigsby *et al.* [9] which could have introduced learned bias. Finally, it was noted that a larger age range for patient selection could affect the results due to the differences in anatomy and common pathologies found between infancy and late adolescence. All the studies were found to be highly applicable to the research question (Table 5).

	Patient Selection	Index Test	Reference Test	Flow and Timing
Soudack <i>et al.</i>	2	2	2	1
Rigsby <i>et al.</i>	2	3	3	1
Lynch <i>et al.</i>	3	2	3	3

Grading system: Low risk of bias = 3, some risk of bias = 2, High risk of bias = 1

Table 4: QUADAS-2 Appraisal Results: Risk of Bias Assessment

	Patient selection	Index Test	Reference Test
Soudack <i>et al.</i> 2018 (6/12)	3	3	3
Rigsby <i>et al.</i> 2003 (9/12)	2	3	3
Lynch <i>et al.</i> 2004	2	3	3

Grading system: Highly applicable = 3, somewhat applicable = 2, Low applicability = 1

Table 5: QUADAS-2 Appraisal Results: Applicability

Characteristics of Studies

The two retrospective studies included varied greatly in time frame, sample size and method. The first study by Soudack *et al.* [8] was the more recent of the two and involved a review of 451 patients (192 females and 256 males) admitted to a large Pediatric Emergency Department between December 2011 and May 2012. All subjects were between 1 month and 18 years and received combined frontal and lateral chest x-rays for suspected community acquired pneumonia. These images were retrospectively reviewed by one of four experienced pediatric radiologist who were blinded to the initial report. The radiologists were first asked to make a diagnosis using only the frontal view; they then repeated the evaluation 4 weeks later with both images. The study found the following results for the frontal image only: sensitivity 86.2%, specificity 93.9%, positive predictive value (PPV) 81.7%, negative predictive value (NPV) 95.5%, false positive rate (FPR) 15% and false negative rate (FNR) 21%. The number needed to treat (NNT), which is the number of lateral images needed to detect one extra case of pneumonia, was 29. Finally, the inter observer agreement for a diagnosis of pneumonia and a diagnosis of not pneumonia was 86% and 72% respectively.

The second study by Rigby *et al.* [9] was much more robust in sample size with 1268 subjects between 0 and 18 years old. All subjects revied frontal and lateral chest x-rays between 1994 and 1995 however the reason for referral was not specified. Images were evaluated by a team of three pediatric radiologists (two staff members and one fellow), in 2 sessions spaced two weeks apart. Whether the frontal or combined series was reviewed first was randomized. The results for the index text were as follows: sensitivity 85%, specificity 98%, PPV 89%, NPV 96%. There was also an FNR of 15% and a FPR of 2.3%.

Only one of the studies found was a random control trial, which was by Lynch *et al.* [10]. This trial was performed between May 1998 and December 1999 in a busy Pediatric Emergency Department and 570 patients between 0 and 16 years of age with suspected pneumonia were enlisted. Participants were separated into two groups using block randomization; group A had 300 participants while group B had 267. All patients received both frontal and lateral chest x-rays, group A returned to the department with only their frontal image for interpretation by experienced pediatricians and group B returned with both images. Diagnosis was conferment by agreement between two of three blinded radiologists. The sensitivity, specificity and FNR of group A was 87%, 57% and 4.5% respectively. The sensitivity, specificity and FNR of group B was 91%, 58% and 3.1%.

Discussion

All the studies reviewed agreed that the combined frontal and lateral examinations was able to diagnose more pneumonias than the frontal only examination, however there seems to be disagreement as to whether the amount is significant. Combined frontal and lateral chest x-rays result in more than double the exposure to the patient [4], as well as increased cost. Furthermore, the extended exam time may cause greater distress to sick patients and to parents [9]. For these reasons it is important that routine use of this image is justified by a significant increase in diagnostic accuracy and/or a notable change in clinical outcomes.

Only Soudack *et al.* [8] made a strong case for including a lateral image, stating that it was likely to prevent over prescription of antibiotics from false positive diagnoses and reduce morbidity from under diagnosis. This is backed up by their unfavorable results for the index test with an FPR of 15% and an FNR of 21%. It should, however, be noted that in this study each subject was reviewed by only one of four radiologists and that the inter observer agreement for diagnosis of pneumonia and a diagnosis of not pneumonia was 86% and 72% respectively. This indicates a reasonably high level of discrepancy between individual reporting. Furthermore, the radiologist's viewing sessions for the frontal and combined series' were only spaced 2 weeks apart. This is a relatively short time interval could have also affected the outcomes of the study. Despite all this Soundack *et al.* [8] was the most recent study and has the benefit of using images taken on more modern equipment.

Rigby *et al.* [9] also found that the combined series is superior in some cases. They calculated a relatively high FNR (15%) and state that non-lobular infiltrated are likely to be underdiagnosed without the lateral image. However, they also claimed that the frontal image was sufficient for diagnosing confluent lobular pneumonia and found that no cases of this were misdiagnosed in their study. Furthermore, their FPR was only 2.3% which does not support the claim that the frontal only image may significantly increase over prescription of antibiotics. Rigby *et al.* [9] has the largest sample size and unlike Soudack *et al.* [8], their images were interpreted by a team of three pediatric radiologists and consensus agreement between at least two of the three was used to confirm diagnosis. Furthermore, their overall agreement between observers was high (kappa 0.71 for the frontal view and kappa 0.72 for the combine series), all of which could have helped to reduce inter observer bias. The researchers also randomized whether the frontal only

radiograph was evaluated first or whether the combined images were evaluated first which may have helped to reduce learner bias given the short time frame between viewing sessions.

The study by Lynch *et al.* [10] seemed to have the most favorable results for the frontal only examination and had the added benefit of not only considering the radiologist interpretation, but also factoring in the pediatric Accident and Emergency (A&E) physician's evaluation of the images. Due to the demands of the Emergency Department setting, pediatric doctors may be required to start treatment before receiving the radiologist's reports, thus is important to look at the clinical impact as well as the diagnostic impact of single view examinations. In this trial they found that the FNR 4.1%, only slightly higher than the 3.1% of the combined examinations. Out of 570 patients only 11 required a change of management after radiologist review with 6 of these being from the frontal only group and 5 from the combined group. Therefore, only 1 extra patient was misdiagnosed because of excluding the lateral image. Out of both groups the patient who did not receive treatment due to a false negative result were contacted via phone and prescribed antibiotics. None of the patients who received treatment and were found to not have pneumonia required a change of management, in all these cases the patients had some other infective process and the antibiotics prescribed were sufficient to treat this thus the course was continued. Lynch *et al.* [10] also found that the difference in sensitivity and specificity between the frontal and combined series was insignificant, with it being 87% and 57% respectively for the frontal only exam and 91% and 58% for the combined exam.

Limitations

One of the limitations of this study is the small body of current research on this topic. We were only able to find one random control trial and two retrospective studies, thus more original research would help to shed greater light on the issue. Furthermore, two of the three studies were published in 2004 and were performed using film or other older technologies. More research using modern Digital Radiography (DR) equipment would help better characterize the accuracy of the single frontal view examination in the modern setting.

Another limitation of our study is the wide age range used. This was done to help include more research. Ideally a narrower age span would have been preferred. This is because there are significant changes in anatomy from infancy to young adulthood. What's more, infants under one year are more likely to develop bronchiectasis rather than pneumonia which is better characterized on the lateral image [12] thus including these children with other pediatric patients could potentially affect the results of the studies.

Finally, we were unable to find any research that presented a cost benefit analysis on this topic. Studies comparing the increased risk of radiation exposure to the population with harm caused from underdiagnosed pneumonia would also be beneficial.

Conclusion

Overall the literature seems to suggest that the combined frontal and lateral examination is more accurate at detecting pneumonia than the frontal only examination. There is, nevertheless, disagreement between how much more accurate and whether this is clinically impactful. The two retrospective studies calculated a relatively high FNR, between 15% and 21%, which could justify the increase in resources and patient exposure. However, these studies only examined diagnosis from the radiologist's perspective and didn't consider the clinical impact. Only one study looked at image interpretation by pediatricians in an emergency setting and this found that there was very little impact on overall treatment. Furthermore, the FNR in this study was much lower at only 3.3%. As patient outcomes and clinical impact are of high importance, we believe more research should be focused on this aspect. While the lateral chest x-ray is important for characterizing certain pathologies and may be useful for further investigation of some abnormal images, it is a consideration that it should not be used routinely, rather as an additional projection in specific situations.

Competing Interests

The authors have no competing interests with the work presented in this manuscript.

Author Contributions

All the authors substantially contributed to the literature review, drafting the manuscript and approve the final version of the manuscript.

Acknowledgment

We are deeply grateful to the Medical Imaging Department at Flinders Medical Centre for their great support to this work.

References

1. Burgner D, Richmond P (2005) The burden of pneumonia in children: An Australian perspective. *Paediatr Respir Rev* 6: 94-100.
2. Moberg A, Taléus U, Garvin P, Fransson S, Falk M (2016) Community-acquired pneumonia in primary care: clinical assessment and the usability of chest radiography. *Scand J Prim Health Care* 34: 21-7.
3. World Health Organization (2001) Model chapter for textbooks: IMCI integrated management of childhood illness. Geneva, Switzerland.

4. World Health Organization (2016) Communicating Radiation Risks in Paediatric Imaging. World Health Organization, Geneva, Switzerland.
5. Abdelhalim MAK, Al-Darwish RO, Al-Ayed MS (2008) Assessment of Patient Doses Levels During X-Ray Diagnostic Imaging Using TL Dosimeters and Comparison with Local and International Levels. Trends Med Res 3: 72-81.
6. Feigin DS (2010) Lateral Chest Radiograph. Acad Radiol 17: 1560-6.
7. Osman F, Williams I (2014) Should the lateral chest radiograph be routinely performed? Radiography 20: 162-6.
8. Soudack M, Plotkin S, Ben-Shulsh A, Raviv-Zilka L, Jacobson J (2018) The Added Value of the Lateral Chest Radiograph for Diagnosing Community Acquired Pneumonia in the Pediatric Emergency Department. Isr Med Assoc J 20: 5-8.
9. Rigsby CK, Strife JL, Johnson ND, Atherton HD, Pommersheim W (2004) Is the frontal radiograph alone sufficient to evaluate for pneumonia in children? Pediatric Radiology 34: 379-83.
10. Lynch T, Gouin S, Larson C, Patenaude Y (2004) Does the Lateral Chest Radiograph Help Pediatric Emergency Physicians Diagnose Pneumonia? A Randomized Clinical Trial. Acad Emerg Med 11: 625-9.
11. Coleman K, Weston A, Norris S, Grimmer-Somers K, Hillier S, et al. (2009) NHMRC levels of evidence and grades for recommendations for developers of guidelines. NHMRC 2009: 1-22.
12. Lynch T, Gouin S, Larson C, Patenaude Y (2003) Should the lateral chest radiograph be routine in the diagnosis of pneumonia in children? A review of the literature. Paediatr Child Health 8: 566-8.

Submit your next manuscript to Annex Publishers and benefit from:

- ▶ Easy online submission process
- ▶ Rapid peer review process
- ▶ Online article availability soon after acceptance for Publication
- ▶ Open access: articles available free online
- ▶ More accessibility of the articles to the readers/researchers within the field
- ▶ Better discount on subsequent article submission

Submit your manuscript at

<http://www.annexpublishers.com/paper-submission.php>