

## Mimicking Occlusal Anatomy Using Innovative Stamp Technique: Case Series

Roja Raj<sup>\*</sup>, Munish Singla, Harleen Kaur, Saloni Gupta, Reetu Arora and Mintu Maria Joseph

Conservative and Endodontics, Adesh Institute of Dental Sciences and Research, Bathinda, Punjab, India

**\*Corresponding Author:** Roja Raj, Conservative and Endodontics, Adesh Institute of Dental Sciences and Research, Bathinda, Punjab, India, Tel.: 7093787190, E-mail – rojaraj.vs@gmail.com

**Citation:** Roja Raj, Munish Singla, Harleen Kaur, Saloni Gupta, Reetu Arora, Mintu Maria Joseph (2024) Mimicking Occlusal Anatomy Using Innovative Stamp Technique: Case Series, J Case Rep Stud 12(1): 104

**Received Date:** June 04, 2024 **Accepted Date:** July 04, 2024 **Published Date:** July 08, 2024

### Abstract

The incremental procedure for composite resin restorations is time-consuming and technique-sensitive, requiring the physician to have outstanding hand dexterity to achieve appropriate contacts and shapes. The "stamp technique" for posterior composite restoration is a technique for precisely replicating occlusal architecture but is less popular. When the tooth's pre-operative anatomy is intact, this treatment is recommended. When caries has caused the occlusal surface to cavitate, an indirect approach may be used. This case series goal is to explain the direct and indirect methods of fabricating and restoring stamps using various materials, with a focus on how dependable and predictable they are when done correctly and how much they aid the practitioner to perfection.

**Keywords:** Dental Caries; Biomimetic Dentistry; Composites; Restorative Dentistry

## Introduction

Over the past few decades, the field of restorative dentistry has witnessed a remarkable transformation, with composite resin materials emerging as a prominent alternative to the traditional amalgam fillings. Since their introduction, these light-cured composite resins have become one of the most used types of dental fillings, with their success rate steadily increasing [1].

The growing demand for aesthetic procedures, particularly among adolescent and young adult patients, has been a driving force behind the evolution of composite resin restorations. Advancements in material science, including the development of improved monomers, fillers, and bonding systems, have enabled clinicians to create conservative and functional restorations with excellent longevity and aesthetic appeal.

The main goal of restoration is to restore the shape, function and occlusion of individual teeth affected by disease. Direct restorations pose a challenge in achieving the original contact, contour and anatomy of the tooth making them highly technique sensitive. Although it being technique sensitive and time consuming, it may still not result in the achievement of proper occlusal anatomy. Today, posterior composite restorations have become the standard in modern dentistry, moving towards biomimetic dentistry. Biomimetic means to imitate nature. In addition, the earlier prophylactic concept of extension is being displaced by minimally invasive dentistry concept by Mount, which focuses on preserving the sound dental structure. A good restoration is one that resembles the original anatomy of the tooth, known as a biomimetic restoration. The purpose of which is to form a perfect and complete attachment between the teeth and restoration.

In the stamp technique, an occlusal matrix is created before carious tissue is removed and the occlusal anatomy of the back teeth is imprinted. This matrix is pressed into the final composite increments prior to curing. This technique is suitable when caries is evident on clinical examination. The literature emphasizes that this technique helps reproduce the original occlusal structure and occlusion. Minimal porosity is minimized and desirable polymerized occlusal surfaces are achieved with minimal finishing and polishing required [2]. In the era of modern dentistry, various restorative materials are introduced for the longevity and improvement in esthetics. Given the drawbacks of other conventional materials in terms of physical properties and esthetics there is increased preference for composites as direct restorations due to their superior mechanical properties and esthetics.

The 'stamp technique' for direct composite restorations proposed by London-based practitioner Waseem Riaz helps achieve a precise occlusal topography. A stamp is an index that reproduces the anatomy of an unprepared tooth. After creating the stamp on the unprepared occlusal surface, the cavity is prepared and the prepared stamp is pressed into the final composite increment before curing [3].

In Class I and Class II preparations, where the occlusal surface is intact prior to restoration, the stamp approach is recommended. For proximal lesions, matricing is necessary before applying an occlusal stamp to the middle or cervical thirds. Cavities are blocked with wax and sculpted to the appropriate morphology in cavitated lesions. Due to the elimination of air during stamp pressing, it enables perfect reproduction of the original occlusal anatomy, little finishing, polishing, and voids with excellent polymerization. Achieving a successful and durable composite restoration requires meticulous attention to patient preparation and the use of appropriate isolation techniques. Proper isolation, specifically with a rubber dam, is crucial to control moisture contamination and ensure a clean, predictable working field. Composite restorations are highly sensitive to the presence of saliva, blood, or any other contaminants during placement, as these can compromise the bond strength and integrity of the restoration over time.

Light-cured composite, self-cured acrylic resin, polyvinylsiloxane bite registration material, liquid dam material, clear silicone molds, and occlusal transfer devices are some of the materials utilized to make the occlusal replicas [3]. This case series presents

composite restorations using direct stamp technique using liquid dam material, flowable composites and assessment of inlay wax as a stamp material for cost efficiency.

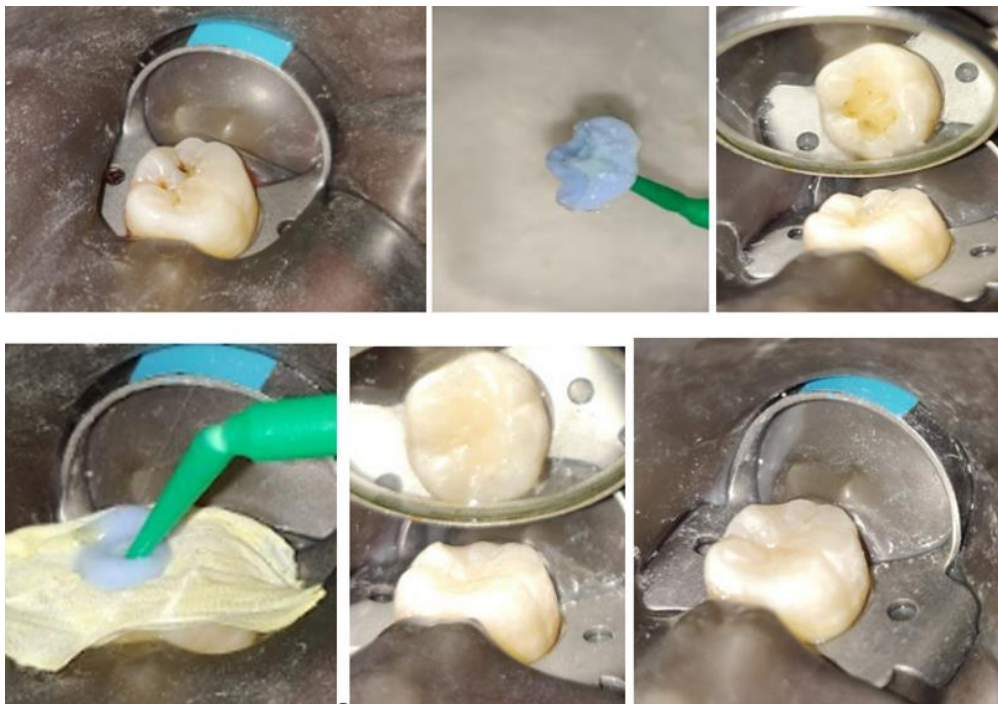
## Case Reports

**Case 1:** A 19-year-old came with the complaint of blackening of lower left back tooth. On Clinical examination, there was Class 1 carious lesion with respect to 46 with an intact occlusal surface. The occlusal surface on examination showed intact anatomy, therefore, Composite restoration using stamp technique was planned.

After Isolation was achieved with rubber dam placement, the tooth surface was cleaned with pumice slurry to remove any impurities and the stamp index was obtained by flowing Liquid dam material over the surface of the tooth. A micro brush was placed in the material and it was light cured. Cavity preparation was done followed by etching with 35% phosphoric acid and rinsing.

The prepared surface was then coated with bonding agent and light cured. The cavity was restored with composite in increments. The stamp was placed over the final increment with Teflon tape as a separator and then light cured.

The restoration was checked for occlusal discrepancy, as an anatomic stamp was created the post-operative occlusal surface followed the same anatomy of the pre-operative surface; Patient did not report any occlusal discrepancy. Finishing and polishing was done to remove and excess flash present on the surface (Shofu Composite Finishing Kit, Shofu Inc., Japan). Marginally the restoration was checked for adaptation using explorer, and no surface discrepancy was noticed and the restoration was well adapted (Figure 1).

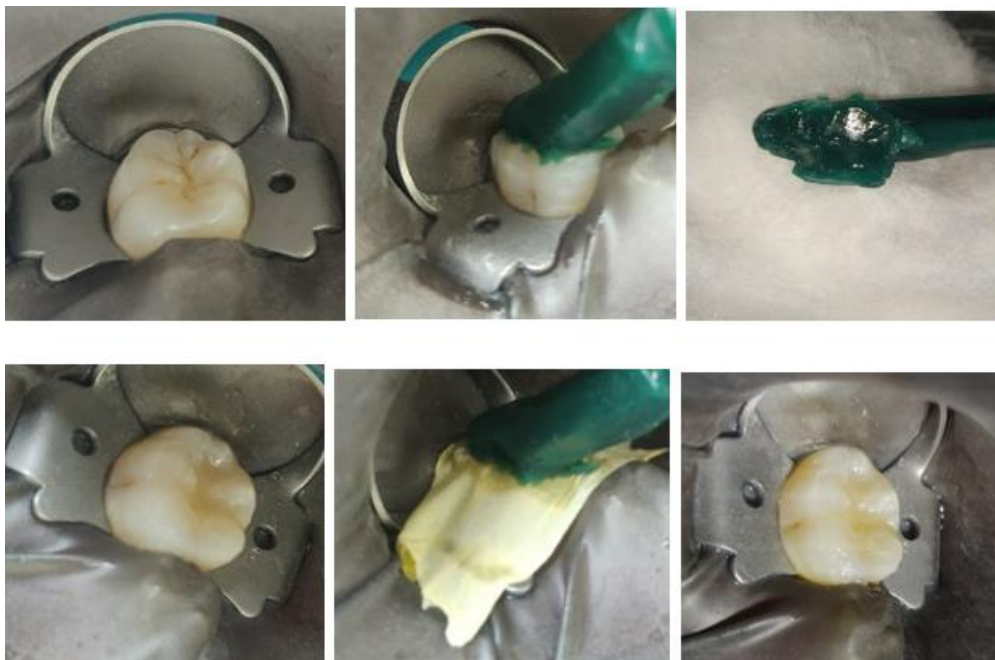


**Figure 1:** (a) Pre-operative (b) Stamp taken with inlay wax stick (c) Stamp Index (d) Cavity preparation (e) Stamp Index placed on final increment of composite (f) Post-operative.

**Case 2:** A 26-Year-old female patient came with the complaint of blackening of lower right back tooth. On Clinical Examination there was Class 1 carious involvement of the tooth 46. The occlusal surface showed intact anatomy upon examination, hence restoring it with composite using stamp technique was planned.

After Rubber Dam isolation, oral prophylaxis was done and the tooth surface was cleaned with pumice slurry to remove any surface impurities, the stamp index was taken using a 1-inch stick of inlay wax. One end of the wax was softened over the flame of a spirit lamp and pressed over the occlusal surface of the tooth after coating it with Vaseline. Upon cooling the occlusal pattern of the said tooth was registered. Another method would be to flow the wax in increments over the surface of the tooth and place a heated bur in it which would serve as the handle. After stamp registration the caries excavation was done using a no.4 round bur. The prepared surface was Etched with 35 % Phosphoric acid for 10 seconds, rinsed and air dried; followed up with bonding agent application which was light cured for 15 seconds. The cavity was restored with composite in increments and cured subsequently. Upon placement of the final increment a Teflon tape was placed over the surface and the stamp index was placed over it. The stamp index is removed and the composite surface is light cured.

The restoration was then checked for occlusal height; Patient did not report any occlusal discrepancy. Finishing and Polishing was done. (Shofu Composite Finishing Kit, Shofu Inc., Japan) (Figure 2).



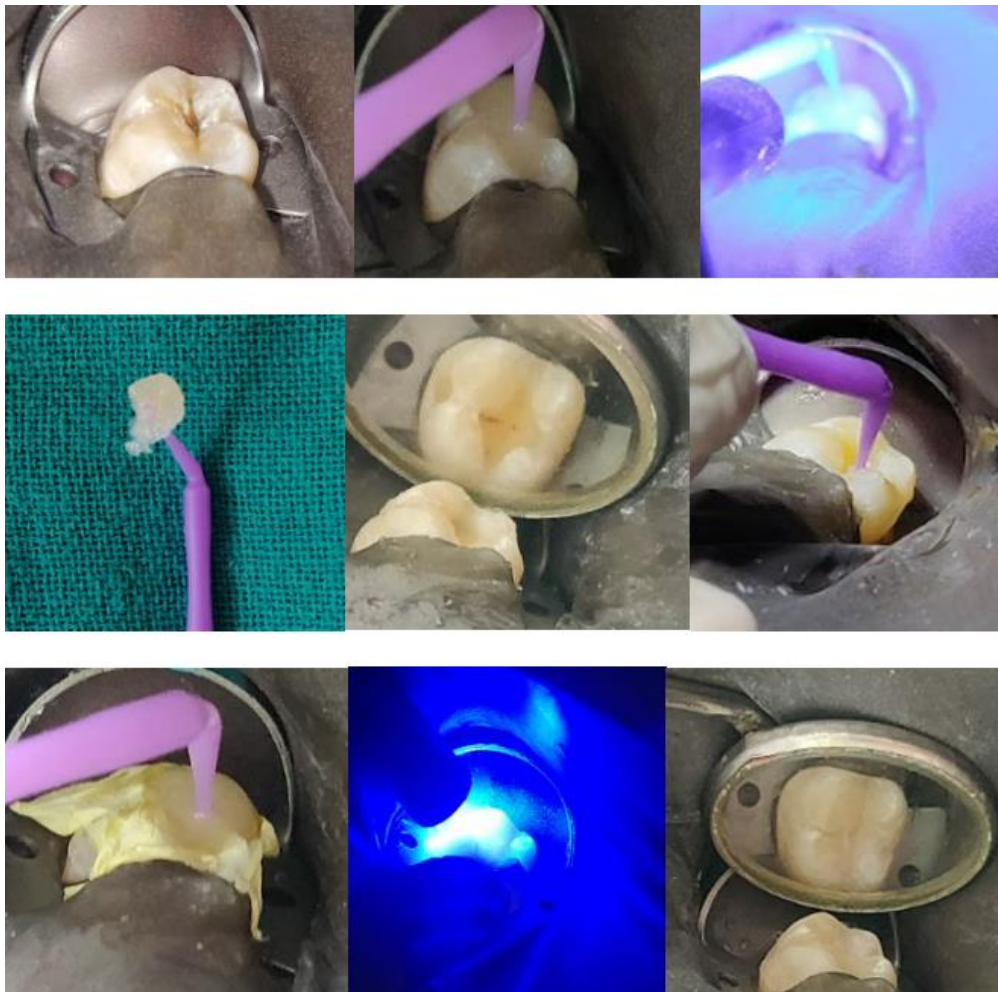**Figure 2:** (a) Pre-operative (b) Stamp taken with inlay wax stick (c) Stamp Index (d) Cavity preparation (e) Stamp Index placed on final increment of composite (f) Post-operative.

**Case 3:** A 19-year-old male patient came with the complaint of discoloration of lower right back tooth. Upon examination, it was a Class 1 carious lesion with intact occlusal anatomy, therefore, it was decided to be restored with composite using stamp technique.

After rubber dam application and surface prophylaxis, the stamp index was taken with flowable composite. The flowable composite was flowed over the surface of tooth and a microbrush head was inserted into it before curing it. The microbrush acts as a handle for the stamp.

Caries excavation was carried out and cavity preparation was done. The cavity was etched, rinsed, bonded and cured. The cavity was restored with composite and the stamp was placed over it with a teflon tape barrier and cured.

The restoration was checked for occlusal height, mild flash due to composite excess was present which was removed and finishing and polishing was done. Patient was satisfied with the post operative appearance and was not able to differentiate between the tooth and restoration interface. (Figure 3).



**Figure 3:** (a) Preoperative. (b) Making of stamp. (c) Curing of stamp. (d) Composite stamp (e)Cavity preparation. (f)Applying bonding agent (g) Placing of stamp on Teflon tape. (h) Curing. (i) After finishing and polishing

## Discussion

Primary carious lesion in posterior teeth may sometimes present with intact occlusal anatomy where there is little or no damage to the enamel but the dentin is affected. The infected dentin is reached after sufficient amount of healthy enamel has been removed. The concept of using stamp technique is applied in restoring such initial lesions with composite. Such lesions are called occult as they possess an intact occlusal surface but are undermined with decay which is seen as a bluish black discoloration underneath the enamel surface [4]. Various other methods to diagnose such lesions include endoscopy (AcuCam), laser fluorescence (DIAGNOdent), fiber-optic transillumination, digital radiography, electrical caries monitor and detection (ECM), among others [4]. The pro that gets the most attention is maybe the shorter turnaround time after the talent is understood because the restoration takes less time to complete because the cusp-fossa relationship is nearly immediately sought. This is beneficial for the busy practitioners and enhances their standing with patients [5].

Additionally, the time spent learning and first doing this technique is important. However, this can readily be remedied using practice. Additionally, it is essential to note that getting the desired results requires the occlusal stamp to be positioned correctly and precisely developing a precise cusp-fossa relationship as a goal. Without it, distortions always happen, defeating the main goal of the procedure [6].

## Conclusion

The micro brush stamp technique is a simple process for accurately recreating the occlusal topography in teeth with preserved occlusal anatomy. In terms of restoration durability, the stamp process does not appear to have any problematic elements, such as microleakage, marginal adaptation, or filling flaws. This method encourages the development of substantial overflowing margins, though, which necessitates a careful finishing procedure [7].

## Clinical Significance

This case series presents the use of stamp technique to restore carious lesions which have reached the dentin with the occlusal anatomy intact. Reproduction of the anatomical details of the tooth is highly technique sensitive. The stamp technique helps retain the original biologic anatomy of the tooth even after the restoration. It provides superior esthetics and adaptation. The usage of different materials to make stamp indexes can also be considered, like wise inlay wax was used to make the stamp index along with flowable composites and gingival barrier providing cost effective alternatives.

## Prior Presentation

None

## Funding Support

None

## Conflicts of Interest

None

## Ethical Approval

None

## Conflicts of Interest

None

## References

1. AlJehani, Yousef & Baskaradoss, Jagan & Geevarghese, Amrita & Alshehry, Marey (2014) Current Trends in Aesthetic Dentistry. *Health*, 06: 1941-1949.
2. Nishad S, Sharma U (2018) Stamp Technique for Posterior Composite Restorations-A Case Report. *IOSR J. Dent Med Sci*, 17: 13-5.
3. Karunakar P, Reddy MSR, Kumar BS, Rayapati N (2022) Direct and indirect stamp techniques for composite restorations – Sealing the uniqueness of a tooth: A case series. *J Conserv Dent*, 25: 327-31.
4. Gomez J (2015) Detection and diagnosis of the early caries lesion. *BMC Oral Health*, 15: S3.
5. Alshehadat SA, Halim MS, Carmen K, Fung CS (2016) The stamp technique for direct Class II composite restorations: A case series. *J Conserv Dent*, 19: 490-3.
6. Murashkin A (2017) Direct posterior composite restorations using stamp technique-conventional and modified: A case series. *International Journal of Dentistry Research*, 2: 3-7.
7. Zotti F, Vincenzi S, Zangani A, Bernardi P, Sbarbati A (2023) Stamp Technique: An Explorative SEM Analysis *Dent J*, 11: 77.

Submit your next manuscript to Annex Publishers and benefit from:

- ▶ Easy online submission process
- ▶ Rapid peer review process
- ▶ Online article availability soon after acceptance for Publication
- ▶ Open access: articles available free online
- ▶ More accessibility of the articles to the readers/researchers within the field
- ▶ Better discount on subsequent article submission

Submit your manuscript at

<http://www.annexpublishers.com/paper-submission.php>