

# Tomotherapy Treatment of Chronic Lymphocytic Leukemia and Ocular Lymphoma

Sidimoussa A<sup>1</sup>, Soufi MZ<sup>1</sup>, Lock M<sup>2</sup>, Coad T<sup>2</sup> and Yartsev S<sup>\*2</sup>

<sup>1</sup>Centre Sidi Abdellah Cancérologie, Pole Santé Sidi Bennour, Mahelma 16093, Alger, Algérie

<sup>2</sup>London Regional Cancer Program, London Health Sciences Centre, London, Ontario, Canada

\*Corresponding author: Yartsev S, PhD, London Regional Cancer Program, London Health Sciences Centre, 800 Commissioners Road East, P.O. Box 5010, STN B, London, ON, Canada N6A 5W9, Tel: (519)-685-8605, E-mail: slav.yartsev@lhsc.on.ca

**Citation:** Sidimoussa A, Soufi MZ, Lock M, Coad T, Yartsev S (2018) Tomotherapy Treatment of Chronic Lymphocytic Leukemia and Ocular Lymphoma. J Case Rep Stud 6(3): 301. doi: 10.15744/2348-9820.6.301

**Received Date:** April 17, 2018 **Accepted Date:** June 25, 2018 **Published Date:** June 27, 2018

## Abstract

**Objective:** To describe two cases of radiation therapy for ocular and near ocular targets with helical tomotherapy.

**Methods:** A sixty-five-years-old male patient with history of non-Hodgkin's lymphoma of the right orbit and a fifty-years-old female patient with chronic lymphocytic leukemia with peripheral lymphocytosis were treated on TomoTherapy. In the first case, a 1 cm beam was used for planning a delivery of 30.6 Gy in 17 fractions with a sequential boost of 9 Gy in 5 fractions. Tumor involvement of the ipsilateral lens and lacrimal gland in the planning target volume necessitated a compromise between preserving patient's vision and delivery of tumoricidal dose to the target. In the second case, 30 Gy in 20 fractions delivery was planned with a 2.5 cm beam. The tumor extended anteriorly and this technique allowed sparing more orbital tissue and required a high modulation factor.

**Results:** The plan for non-Hodgkin's lymphoma resulted in sufficient target coverage with the mean doses to the ipsilateral eye lens and lacrimal gland of 23.44 and 24.87 Gy, respectively. Treatment was generally well-tolerated and acute toxicity profile was mild. For the patient with chronic lymphocytic leukemia low doses of 5.94 Gy for the left lens and 6.00 Gy for the right lens were achieved, while assuring the mean dose to the target of required 30.5 Gy. Long term follow up has demonstrated excellent cosmetic results and clinical outcome.

**Conclusion:** Helical tomotherapy has proved to be effective treatment technique for ocular and near ocular targets.

**Keywords:** Radiation Therapy; Tomotherapy; Head and Neck Cancer; Lymphocytic Leukemia; Ocular Lymphoma

**List of abbreviations:** CT: Computed Tomography; CTV: Clinical Target Volume; DQA: Delivery Quality Assurance; Gy: Gray; MRI: Magnetic Resonance Imaging; MVCT: MegaVoltage Computed Tomography; PTV: Planning Target Volume; cm: centimeter

## Introduction

Radiation therapy plays an essential role in the treatment of a wide range of tumors that arise in the orbit, invade the orbit, or are located in close proximity to the orbit. Partial or total orbital irradiation may cause a wide spectrum of early and late toxicities, ranging from transient irritation to permanent blindness or to salvage orbital exenteration [1]. Non-Hodgkin's lymphoma (NHL) is a group of malignant neoplasms that involve excessive proliferation of B- or T-lymphocytes. Orbital lymphoma refers to a lymphoma occurring in the conjunctiva, lacrimal gland, eyelid and ocular musculature [2]. Chronic lymphocytic leukemia, a usually slow growing cancer, starts in the white blood cells in the bone marrow, invades the blood and can spread to other organs, including the lymph nodes and spleen. While many patients with chronic lymphocytic leukemia do not have early symptoms, others experience symptoms such as enlarged lymph nodes, fever, fatigue, and weight loss. Many options are available; Tomotherapy is a preferred method of treatment for patients with tumors in proximity of organs sensitive to radiation, especially when the tumor has a concave shape requiring high conformity of dose delivery [3-5]. We report the treatment of orbital lymphoma and chronic lymphocytic leukemia treated with tomotherapy.

## Case Descriptions

Our first case, treated in Centre Sidi Abdellah, is a 65 y.o. male with a history of a small B-cell Stage 1 NHL of right orbit, with no repercussions on vision. The patient was immobilized in supine position using a thermoplastic mask system with active fixation and scanned with a GE Computed Tomography scan (General Electric Healthcare, Milwaukee, WI) with 2.5 mm slice spacing.

The Clinical Target Volume (CTV) was the region of right ocular orbit with a volume of 42.13 cm<sup>3</sup>, the first planning target volume (PTV1) was delineated with a 3 mm margin from CTV, the gross target volume (GTV) was defined as the gross extent of tumor demonstrated by CT and MRI imaging fusion with a volume of 5.57 cm<sup>3</sup>. PTV boost was delineated with a 3 mm margin from GTV. Normal tissue structures included the right and left lenses, right and left eyeballs, lacrimal glands, temporal lobes, optic nerves, optic chiasm and brainstem [1]. In addition to the organ at risk, Crop-PTV (PTV1 without lens and lacrimal gland), donut ring (1 cm/1 mm), and internal (3 mm margin from external) volumes were created to optimize the dose distribution. Radiation was delivered in two steps: the first plan (Plan 1) with the prescription of 30.6 Gy in 17 fractions and the Plan 2 with the prescription of 9 Gy in 5 fractions to the PTV boost [6]. The radiotherapy plan was calculated with the field width of 1.05 cm, a planning modulation factor of 2 and a pitch of 0.287 for both plans. The treatment beam-on time was 257.1 seconds for Plan 1 and 268.6 seconds for Plan 2. The two plans were optimized to reach clinically acceptable PTV coverage and organ at risk (OAR) sparing [7], but the target coverage of was slightly sacrificed (91% of the PTV1 was covered by 95% of the prescription dose), because the PTV1 included lens and lacrimal gland Figure 1.

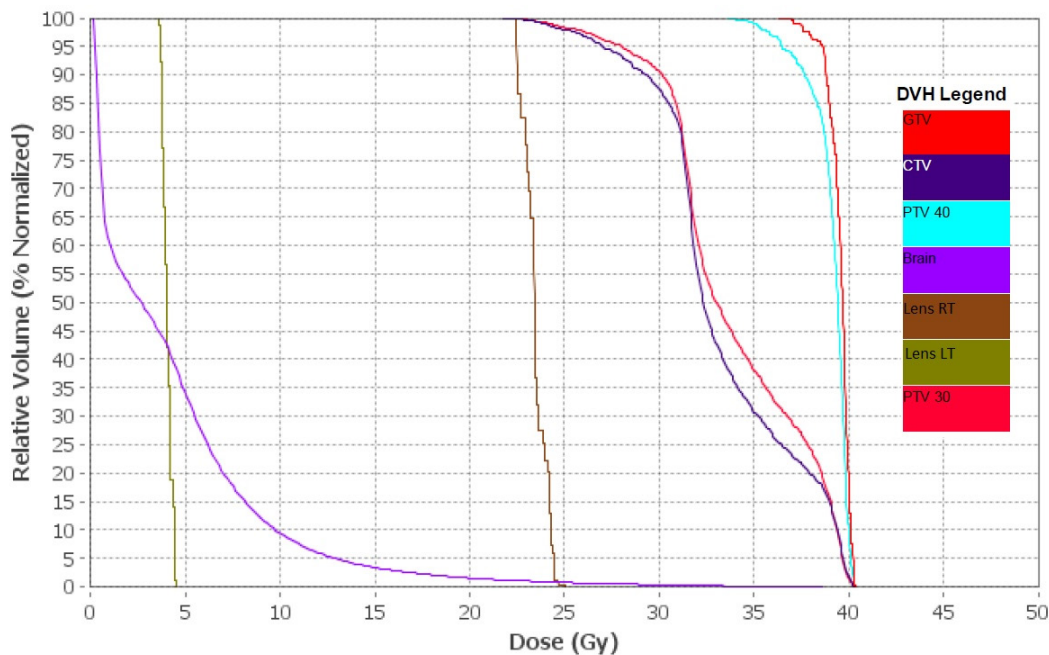


Figure 1: Planned dose distribution of case 1

Due to excellent dose distribution shown in Figure 2, the treatment resulted in resolution of the disease at this location without severe treatment-related side effects and preserving patient’s vision. With this approach, we were able to protect the lacrimal gland to avoid dryness of the eyes while treating the PTVs [8]. For our patient treated to 30.6 Gy with boost up to 39.6 Gy, we were able to achieve contralateral mean eye dose of 4.28±0.66 Gy. The mean dose to the contralateral eye lens was only 4.03±0.25 Gy, while the ipsilateral eye lens and lacrimal gland included in the PTV1 received 23.44±0.62 add 24.87±2.03 Gy, respectively. Treatment was generally well-tolerated and acute toxicity profile was mild.

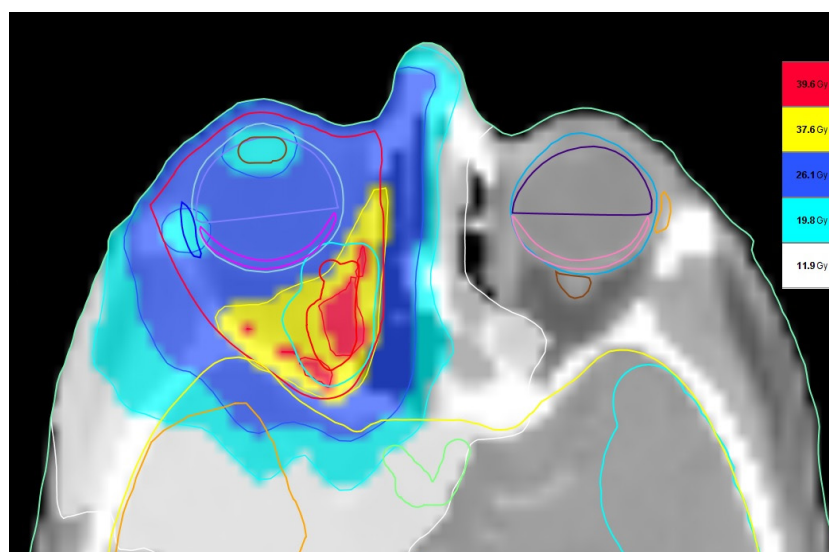


Figure 2: Dose-volume histogram for case 1

Our second case treated in London, Ontario involved a 50-year-old, female patient who was diagnosed with chronic lymphocytic leukemia with peripheral lymphocytosis. The patient developed ocular masses with lymphomatous infiltration with a small cell lymphocytic lymphoma, which resulted in proptosis and severe swelling. Because of the high risk associated with surgical procedures and the extension of tumor to the lacrimal glands, TomoTherapy was chosen for this patient. Sculpting the dose into a shape similar to an ‘ice cream cone’ to avoid treating the eye (‘ice cream’) was required and would have been very difficult and/or long with other systems. Without this procedure, the chance of vision or eye loss would have been significant. Dry eye and corneal ulceration are major concerns as they could lead to the need for exenteration. As the disease was progressing rapidly around the eye, a rapid turnaround between CT, planning and treatment was required. The patient was immobilized with an S-frame to ensure stable position during pre-treatment imaging and radiation delivery. The PTV of 59.01 cm<sup>3</sup> was treated with the dose of 30 Gy in 20 fractions with the field width of 2.5 cm, an actual modulation factor of 4.243, and a pitch of 0.215. This high modulation factor was necessary to achieve low doses of 5.94±0.93 Gy for the left lens and 6.00±1.06 Gy for the right lens. The mean dose to the PTV was 30.5±0.7 Gy. Figure 3 presents the dose distribution obtained for this case and the planned dose-volume histogram in shown in Figure 4. The treatment beam-on time was 228 s. Follow-up for this particular procedure primarily involves blood work, but imaging using CT and MRI were also valuable to monitor regression. The patient returned for a follow-up, and while there was short term decreased visual acuity, several months of transient episodic periorbital angioedema (swelling below the surface of the skin around the eyes) and several months of dry eyes post radiation treatment, the patient currently, 10 years after the treatment, has no visual issues requiring intervention. For example, the patient does not require eye drops and her last hematology oncology visit revealed no issues. This is outstanding considering that portions of her eye and lacrimal glands overlapped areas requiring treatment.

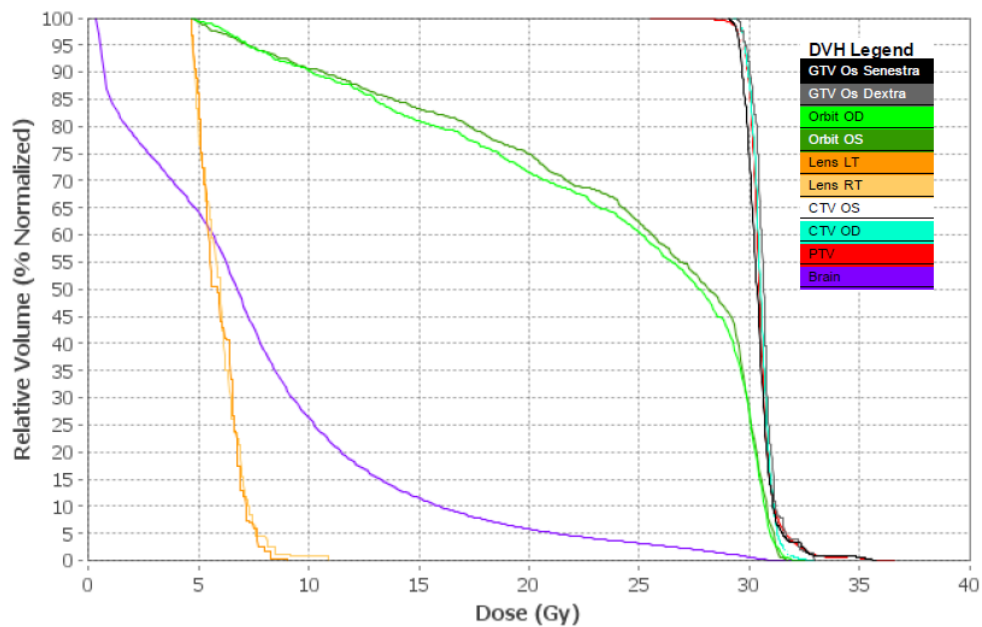


Figure 3: Planned dose distribution of case 2

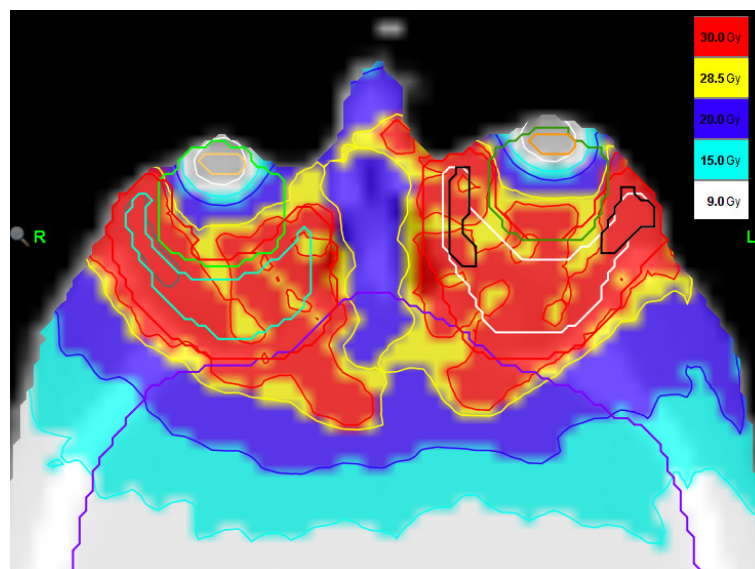


Figure 4: Dose-volume histogram for case 2

For each treatment fraction, the patients were scanned in the treatment position, and the daily position was compared to the one obtained for planning and adjusted for precise delivery. After the treatment was performed, the daily MVCT image was used for verification of delivered dose during this day using TomoTherapy Planned Adaptive software. TomoTherapy is also used when the patient anatomy is expected to change between radiation delivery fractions. Daily pre-treatment megavoltage computed tomography (MVCT) imaging on the TomoTherapy system can provide the necessary information to adjust patient position for precise delivery.

A delivery quality assurance (DQA) procedure, which consists of calculating the dose distribution in a phantom using the radiation fluence calculated for this patient, was prepared for the patient. This DQA procedure was then performed on the TomoTherapy treatment station where calculated dose was verified with the measured data.

Recently, Pinnix *et al.* reported the outcomes for 22 patients with indolent B-cell and mantle cell ocular adnexal lymphoma treated by ultra-low-dose (4 Gy in two 2 Gy fractions) radiotherapy resulting in a complete response in 19 patients (86%) and a partial response in 3 patients (14%) [9]. Proton therapy is another option for ocular tumors [10]. Detailed comparison of long term outcomes and treatment costs is needed for determination of the preferred treatment option for specific patient cases.

## Conclusion

Helical tomotherapy has proved to be effective treatment technique for ocular and near ocular targets.

## Disclosures

The authors report no conflict of interest concerning the materials or methods used in this study or the findings specified in this paper.

## References

1. Jeganathan VS, Wirth A, MacManus MP (2011) Ocular risks from orbital and periorbital radiation therapy: A critical review. *Int J Radiat Oncol Biol Phys* 79: 650-9.
2. Gulati S, Corrêa ZM, Karim N, Medlin S (2016) Ocular adnexal lymphoma presenting with visual loss. *North Am J Med Sci* 8: 56-60.
3. Fogliata A, Yartsev S, Nicolini G, Clivio A, Vanetti E, et al. (2009) On the performances of Intensity Modulated Protons, RapidArc and Helical Tomotherapy for selected paediatric cases. *Radiat Oncol* 4: 10.1186/1748-717X-4-2.
4. Mackie TR, Holmes T, Swerdloff S, Reckwerdt P, Deasy JO, et al. (1993) Tomotherapy: A new concept for the delivery of dynamic conformal radiotherapy. *Med Phys* 20: 1709-19.
5. Penagaricano JA, Yan Y, Corry P, Moros E, Ratanatharathorn V (2007) Retrospective evaluation of pediatric cranio-spinal axis irradiation plans with the Hi-ART tomotherapy system. *Tech Cancer Res Treat* 6: 355-60.
6. Yadav BS, Sharma SC (2009) Orbital lymphoma: Role of radiation. *Ind J Ophthalmol* 57: 91-7.
7. Thariat J, Racadot S, Pointreau Y, Boisselier P, Grange JD, et al. (2016) Intensity-modulated radiotherapy of head and neck cancers: Dose effects on the ocular, orbital and eyelid structures. *Cancer Radiother* 6: 467-74.
8. Nanda T, Wu CC, Campbell AA, Bathras RM, Jani A, et al. (2017) Risk of dry eye syndrome in patients treated with whole-brain radiotherapy. *Med Dosim* 42: 357-62.
9. Pinnix CC, Dabaja BS, Milgrom SA, Smith GL, Abou Z, et al. (2017) Ultra-low-dose radiotherapy for definitive management of ocular adnexal B-cell lymphoma. *Head Neck* 39: 1095-100.
10. Doyen J, Bondiau PY, Benezery K, Thariat J, Vidal M, et al. (2016) Indications and results for protontherapy in cancer treatments. *Cancer Radiother* 20: 513-8.

Submit your next manuscript to Annex Publishers and benefit from:

- ▶ Easy online submission process
- ▶ Rapid peer review process
- ▶ Online article availability soon after acceptance for Publication
- ▶ Open access: articles available free online
- ▶ More accessibility of the articles to the readers/researchers within the field
- ▶ Better discount on subsequent article submission

Submit your manuscript at

<http://www.annexpublishers.com/paper-submission.php>