

Mediastinitis Revealing Primitive Thyroid Tuberculosis

Chaouki A*, Halily S, Ballage A, Rouadi S, Abada R, Roubal M and Mahtar M

Department of Oto-Rhino-Laryngology, Head and Neck Surgery, University Hospital, Casablanca, Morocco

*Corresponding author: Chaouki A, Department of Oto-Rhino-Laryngology, Head and Neck Surgery, University Hospital, Casablanca, Morocco, Tel: + 212 618984627, E-Mail: anasschaouki.ac@gmail.com

Citation: Chaouki A, Halily S, Ballage A, Rouadi S, Abada R, et al. (2019) Mediastinitis Revealing Primitive Thyroid Tuberculosis. J Case Rep Stud 7(2): 204. doi: 10.15744/2348-9820.7.204

Received Date: January 23, 2019 Accepted Date: April 24, 2019 Published Date: April 26, 2019

Abstract

Introduction: Tuberculosis of the thyroid gland is very rarely diagnosed with a prevalence of 0.1-0.3 %. According to Ghosh, *et al.*, the rarity of this localization is due to the bactericidal action of colloid and also the high iodine content and high blood flow in thyroid tissue.

Case report: We report a very rare case of 45 years old man with no medical history, admitted in the head and neck department for a neck abscess with mediastinitis. The patient underwent surgical drainage with multiple biopsies. Histology showed primitive tuberculosis of the thyroid. The patient was started on anti-tuberculosis drugs with good evolution.

Discussion: Primary TB of the thyroid gland is an extremely rare extra pulmonary manifestation of TB even in endemic areas. The fine needle aspiration cytology is described as the best method for cytological and bacteriological examination. The imaging techniques are not useful for the diagnosis of tuberculous thyroiditis. The Thyroid tuberculosis responds well to anti-tuberculosis drugs and the role of surgery is to drain any abscess. Evolution is often favorable with the exception of a few cases of treatment failure due to bacterial resistance.

Keywords: Thyroid Tuberculosis; Mediastinitis

Introduction

The first case of primary thyroid tuberculosis was reported in 1893 by Bruns [1]. It remains very rare even in endemic countries. The prevalence varies from 0.1% to 0.3% in histologically diagnosed specimens [2].

Thyroid Tuberculosis is difficult to diagnose, thus Fine Needle Aspiration Cytology (FNAC) or histopathological examination of the resected specimen forms the mainstay of diagnosis [2].

We report a very rare case of thyroid localization of primary tuberculosis revealed by a mediastinitis. This case highlights the importance of evoking the diagnosis of tuberculosis in case of any anterior abscess of the neck with an insidious clinical presentation.

Case Report

We report a case of a 45-year-old man with no medical history who consults for a left supraclavicular swelling evolving for fifteen days. The patient reports a month history of fever, night sweats and palpitation without respiratory signs, all associated to deterioration of the general state and weight loss.

Clinical examination found cervical swelling, fullness of the left supraclavicular fossa and pain on palpation, without collateral circulation or facial swelling. The pulmonary examination was normal. There were no palpable lymphadenopathies.

On the biological assessment, the patient had a high leukocyte count (16,000/ mm³) with an elevated C Reactive Protein (CRP) at 240 mg / l.

Cervical computed tomography (CT) showed an abscess of the thyroid with central necrosis, and extension to the left supraclavicular region sparing the main vessels of the neck (Figure 1).

Surgical exploration was carried out allowing the drainage of a thick greenish liquid. Aerobic and anaerobic cyto-bacteriological studies as well as Mycobacterium tuberculosis testing were negative (Figure 2). The diagnosis of thyroid tuberculosis was made based on pathology results showing a tuberculoid granuloma with central caseous necrosis.

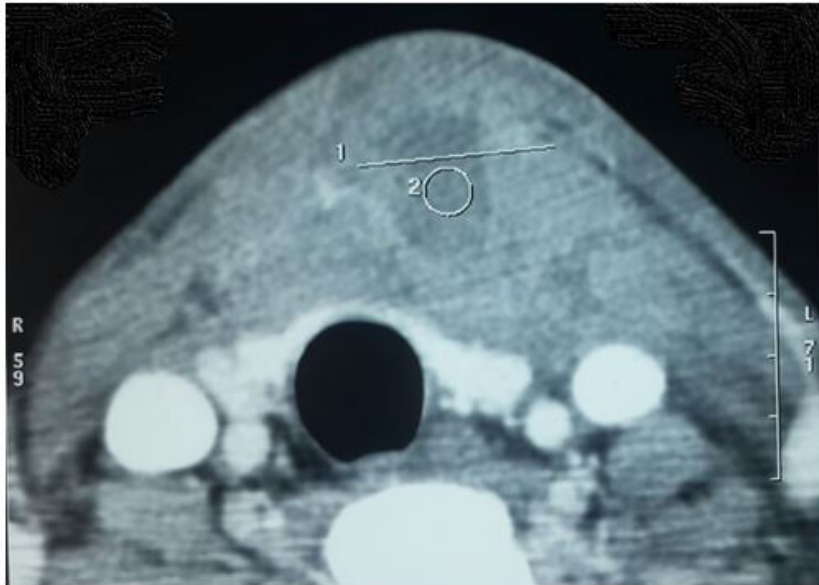


Figure 1: Cervical computed tomography

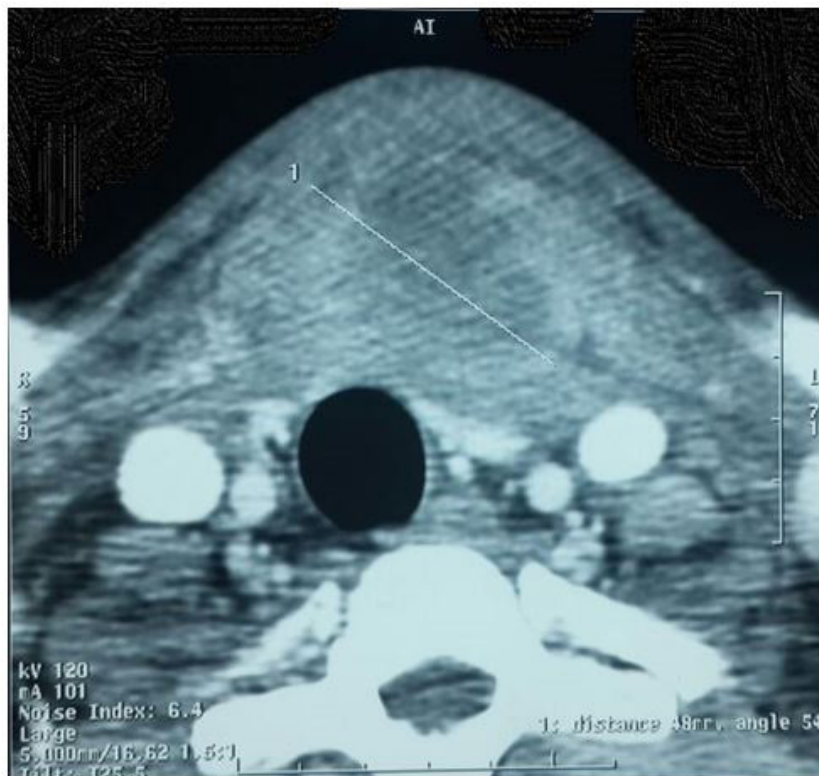

Figure 2: Aerobic and anaerobic cytobacteriological studies as well as Mycobacterium tuberculosis

Patient was put on anti-tuberculosis drugs for nine months, with a good clinical and biological evolution. The cervical swelling and mediastinitis regressed, and general state improved. On biology, white blood cells count and CRP were back to normal.

Discussion

There are about 200 cases of thyroid tuberculosis that had been reported in world literature [2]. According to Ghosh, *et al.*, several hypotheses have been described to explain the rarity of this localization including the bactericidal action of colloid, the high content of iodine and the good thyroid blood flow [2]. This localization can be isolated or associated with multifocal tuberculosis [3,4]. In our case, the location was primitive.

Tuberculosis can spread directly from adjacent organs or through the blood stream. In our case, the mycobacterium tuberculosis probably diffused through an adjacent lymphadenopathy.

The clinical presentation is highly variable and non-specific [3,4]. Most cases are asymptomatic. It can occur in different forms; a solitary cold abscess, diffuse goitre with castration, acute abscess, or chronic fibrotic lesions [3]. In our case it was a subacute cold abscess. In majority of cases, diagnosis is made after surgical drainage through histopathological examination.

Fine needle aspiration is described as the best method for cytological and bacteriological examination [5]. In our case the diagnosis was confirmed by the pathological study. The differential diagnosis of thyroid tuberculosis depends on the presence or absence of cervical pain. If pain is the predominant clinical finding, the differential diagnosis is between an infectious form of thyroiditis (bacterial, fungal, etc.) and subacute granulomatous thyroiditis (De Quervain, thyroid sarcoidosis, etc.). The culture of aspiration specimen and the histological results confirm the diagnosis of tuberculous thyroiditis. In this case pain was mild, only on palpation thus thyroid tuberculosis might falsely be diagnosed as a malignant thyroid tumor.

Imaging techniques are not very useful for diagnosing tuberculous thyroiditis. Ultrasound generally reveals a heterogeneous, hypoechoic mass similar to a neoplastic lesion. CT can help locate caseous necrosis. This finding consists of a necrotic center with a peripheral edge due to acute inflammation causing adjacent tissue thickening [6].

Thyroid tuberculosis responds well to anti-tuberculosis drugs. The treatment is carried out for nine months (isoniazid, rifampicin, ethambutol or streptomycin, pyrazinamide). Monitoring of thyroid hormone levels is required before, during and after treatment. Treatment failure is rare and usually due to bacterial resistance. Recurrence rate is 1% [7]. The role of surgery in thyroid tuberculosis remains limited to drainage of an abscess and in some cases, lobectomy [3].

Sclerosing tuberculous mediastinitis is a rare condition complicating a primary tuberculous lesion, especially ganglionnic. Clinical manifestations are made of a swelling of the face, an upper vena cava syndrome with edema, fullness and tenderness of the two supra-clavicular regions and a thoracic collateral vein circulation. The treatment is mainly medical based on anti-tuberculosis drugs and anticoagulants [8].

In our case, the patient reported a left supraclavicular swelling without signs of superior vena cava syndrome.

Conclusion

Despite its rarity, thyroid tuberculosis should be considered during the evaluation of patients with thyroid mass evolving insidiously to avoid serious complications including mediastinitis.

Conflict of Interests

The authors declare no conflict of interest.

References

1. Ortiz-Flores A, Gioia F, Montáñez-Fernández L, Santacruz E, Martín-Dávila P, et al. (2017) Incidental finding of a primary thyroid tuberculosis. *Oxf Med Case Reports* 2017: omx022.
2. Lourtet-Hascoet J, Le Grusse J, Fontaine S, Caron P (2015) Thyroid tuberculosis: a new case and review of the literature. *Ann Endocrinol (Paris)* 76: 635-7.
3. Varghese A, Suneha S, Shaha A (2015) Primary Tuberculosis of Thyroid. *Am J Otolaryngol* 36: 808-9.
4. Chuang TJ, Liu JS, Hung YJ, Hsieh CH (2014) Thyroid tuberculosis. *QJM* 108: 47-8.
5. Luiz HV, Pereira BD, Silva TN, Vellozo A, Matos C, et al. (2013) Thyroid tuberculosis with abnormal thyroid function--case report and review of the literature. *Endocr Pract* 19: e44-9.
6. Majid U, Islam N (2011) Thyroid tuberculosis: a case series and a review of the literature. *J Thyroid Res* 2011: 1-4.
7. Ponce Villar Ú, Roig MP, Franco AC, MonzoFP, Perez FC, et al. (2015) Presentation of primary thyroid tuberculosis as a subacute thyroid abscess. About a case (Presentación de tuberculosis tiroidea primaria como absceso subagudo de tiroides). *Semergen* 41: e58-e60
8. Wu Z, Jarvis H, Howard LS, Wright C, Kon OM (2017) Post-tuberculous fibrosing mediastinitis: a review of the literature. *BMJ Open Respir Res* 4: e000174.

Submit your next manuscript to Annex Publishers and benefit from:

- ▶ Easy online submission process
- ▶ Rapid peer review process
- ▶ Online article availability soon after acceptance for Publication
- ▶ Open access: articles available free online
- ▶ More accessibility of the articles to the readers/researchers within the field
- ▶ Better discount on subsequent article submission

Submit your manuscript at
<http://www.annepublishers.com/paper-submission.php>