

# Can Myofascial Treatment with Pulsating Vibrations Improve Mobility for Patients with Frozen Shoulder? A Case Study

Borg H<sup>1</sup>, Bohlin H<sup>2</sup> and Ranje-Nordin C<sup>3</sup>

<sup>1</sup>Physician, Private Practicing, Sweden

<sup>2</sup>Business Economics, Private Practicing Manual Therapist, Sweden

<sup>3</sup>Agriculture Animal Science, Private Practicing Human & Equine Therapist, Sweden

\***Corresponding author:** Borg H, Md, Physician, Private Practicing, Skördevagen 10, Se 61146 Nyköping, Sweden, Tel: +46708280536, E-mail: hafr@telia.com

**Citation:** Borg H, Bohlin H, Ranje-Nordin C (2019) Can Myofascial Treatment with Pulsating Vibrations Improve Mobility for Patients with Frozen Shoulder? A Case Study. J Case Rep Stud 7(5): 504

**Received Date:** September 9, 2019 **Accepted Date:** October 26, 2019 **Published Date:** October 29, 2019

## Abstract

Thousands of patients are annually diagnosed with Frozen Shoulder (FS) or adhesive capsulitis, where the joint capsule contracts and becomes less flexible. The condition is painful, with reduced range of motion (ROM) in the shoulder and arm and causes great suffering, often with difficulty sleeping and greatly reduced work ability. The treatment given today is partly conventional treatment with cortisone or NSAID preparations as well as physiotherapy and other therapeutic treatment which usually have limited effect. The study investigates whether myofascial treatment, using a device generating deep pulsating vibrations, can provide increased ROM and facilitate for these patients. 23 patients diagnosed with FS were included in the study. Three treatments were performed, within set time intervals. The ROM was measured before and after each treatment, pictures were taken with a thermography camera and angles were measured. The result showed that 87 percent got an increased ROM by 30 degrees or more, that 52 percent of the patients improved ROM by 60 degrees or more, and that 30 percent regained full ROM. 61 percent of the patients also reported improved quality of sleep. The study indicates that this treatment could possibly improve ROM and well-being for patients with FS. Further studies are recommended to evaluate and validate these findings. A validated treatment of FS could mean great socioeconomic benefits and an increased quality of life for patients diagnosed with FS.

**Keywords:** Frozen Shoulder; Adhesive Capsulitis; Fascia; Myofascial Pain; Fascia Treatment; Myofascial Treatment

## Introduction

Frozen shoulder (FS), adhesive capsulitis, is a common disease characterized by gradual decreased, active and passive movement of the glenohumeral joint. The disease course is a gradual process that starts with inflammation of the synovial fluid and progresses to fibrosis in the joint capsule, which contracts and solidifies, which occurs in four different clinical stages (Hannafin *et al*, 2000) [1]. FS is divided into primary or secondary FS. Primary FS, also idiopathic FS, occurs spontaneously without any known cause or trauma, while secondary FS is caused by trauma or immobilization of the shoulder (Zuckerman *et al*, 2011) [2]. The initiator of synovitis in primary FS is unclear but Kanbe *et al* (2009) [3] found molecules related with mechanical stress in the synovium. The first stage, which lasts a few months, is characterized by inflammatory processes in the synovial fluid, but the joint capsule is intact (Hannafin *et al*, 2000) [1]. The patient experiences severe pain during certain movements, which results in a reduced range of motion (ROM) but also pain at rest and during the night. This can also cause the patient to avoid moving the arm and more immobility leads in turn to even more stiffness and reduced ROM, (Stecco *et al*, 2013) [4]. In stage 1, the decrease in ROM appears to be largely due to the pain and not to the joint capsule being densified. There also were more signs of inflammation in stage 1, which begin to decline in stage 2. In the later stages, changes have begun to occur in the joint capsule's connective tissue which has begun to densify, and scar tissue and fibrosis can be seen, and the inflammation is declining. The pain has increased gradually and is more persistent and this can continue for many months up to a year or more. Then the pain begins to decrease but the shoulder becomes more immobile and stiffer, it has "frozen". FS starts to heal and improves slowly, and this stage can continue for a long time, up to two years. However, a certain limitation in the ROM often remains afterwards (Hannafin *et al*, 2000) [1].

Primary FS, without any obvious preceding cause, is diagnosed by history and physical examination while other causes of motion loss and pain are excluded (Hannafin *et al*, 2000) [1]. Due to the slow creeping course of primary FS, it is common for the patient not to notice the deterioration in ROM but only to respond to slowly increasing pain in the shoulder (Manske *et al*, 2008) [5]. FS is most common between the ages of 40 and 60 and affects about three percent of the population and is also more common in

women. Also, patients with diabetes are at increased risk of getting the disease (Manske *et al*, 2008) [5]. The condition is difficult to treat and hitherto, treatments consist of corticosteroids and NSAIDs as well as physiotherapy and home exercises with limited results. It is known that vibration and oscillation stimulate and facilitate circulation and flow in the fascia and release tension (Comeaux, 2010) [6].

The fascia has a variety of functions, including power transmission, movement, stability, proprioceptive communication and by providing a sliding layer and reducing friction in connection with movement (Kumka and Bonar, 2012) [7]. The fascia is abundantly innervated and contains a large number of free nerve endings and proprioceptors (Stecco *et al.*, 2007 [8]; Stecco *et al.*, 2013 [4]; Bhattacharya *et al.*, 2011) [9]. Densification and adhesions in the fascia and its extracellular matrix (ECM) are related to decreased glide ability due to increased viscosity (Stecco *et al.*, 2011, 2013, 2018; Langevin *et al.*, 2011; Chaitow, 2014) [4,10,11-13]. Stecco *et al* suggest that the viscoelasticity of fascia can modify activation of the nervous receptors within fascia. These mechanoreceptors respond to the viscoelasticity in surrounding tissue and if they are overstimulated, they can become nociceptors (Stecco *et al*, 2007, 2013) [4,8].

Cells in the fascia, specialized in producing hyaluronic acid (HA) for the ECM, like the cells in the subsynovial membrane, have been demonstrated, together with the importance of the role of HA in maintaining the viscoelasticity of a healthy fascia and how this affects a variety of pathological conditions such as myofascial pain, muscle contractures, densification, fibrosis, etc. (Stecco *et al.*, 2011, Stecco *et al.*, 2013; Stecco *et al.*, 2018) [4,10,11]. It has been known in the past that changes in HA concentration are associated with inflammation and degenerative joint diseases (Temple-Wong *et al.*, 2016) [14] and that problems with the fascial glide function can interfere with the whole tissue's function and induce pain (Stecco *et al*, 2013 [4]; Bordoni *et al*, 2014) [15]. It is also generally known that HA has an active role in the healing processes of the tissue. HA is a high molecular weight polysaccharide and is a key component of the ECM in the loose fascia, including between deep fascia and muscle, within muscles and between the collagen layers in the deep fascia. It is also a major component of articular joint synovial fluid, where it provides the viscoelasticity and lubrication to protect the joint cartilage. HA has a wide variety of physiological functions in the body, including maintenance of a viscoelastic cushion to protect tissues and to facilitate smooth gliding during movement and in transmission of force from muscle contraction, receptor mediated signaling, cell migration, inflammation and healing properties. Thus, HA has a fast turnover rate and it is also known that it behaves like a non-Newtonian fluid at high concentrations and becomes more viscous (Stecco *et al*, 2014; Cowman *et al*, 2015) [16-18]. During inflammatory conditions, concentrations of HA is increased, and the molecules are degraded to shorter chains and lower molecular weight. Changes in HA concentration, molecular weight, inflammatory modifications of HA, binding interactions with other macromolecules, temperature and pH with more, affect the viscoelastic properties of HA and can have dramatic effects on the sliding properties of the fascia. The higher the concentration, the higher the viscosity. (Cowman *et al*, 2015) [18].

Immobilization of a body segment (as with pain caused by FS) can lead to an increase in the concentration of HA within and between the epimysial fasciae and thus increase the fluid viscosity which in turn decrease the fascial gliding between the layers and give cause for stiffness (Okita *et al*, 2004; Stecco *et al*, 2013) [4,19]. Reduced ROM can also give rise to shortening of sarcomere length in muscle fibers in the early stage of immobilization. These changes can increase the number of cross bridges attached during contraction and after several weeks of immobilization the collagen fibrils arrangement in the endomysium adapts and become more circumferential instead of longitudinal to the axis of the muscle fibers (Okita *et al*, 2004; Cowman *et al*, 2015) [18,19].

In conditions of inflammation, the concentration of HA increases and the HA-chains begin to entangle into complex arrays and altering the viscoelastic properties that can give rise to myofascial pain. Then, the HA becomes adhesive rather than lubricating, and the distribution of ROM in lines of force, within the fascia become altered. By increased viscosity, the receptors within the fascia can get over-stimulated and send a pain message from a degree of stretching of the fascia that is even within the physiological range (Stecco *et al*, 2007, 2013) [4,8]. When concentration of HA is altered, it triggers a cascade of changes, leading to fibrosis due to the deposition of collagen within and between muscle bundles. This in turn leads to further increase in ECM viscosity in the surrounding tissue and restarting the circle (Stecco *et al*, 2013 ; Stecco *et al*, 2014) [4,16,17].

The study investigates whether myofascial treatment around the shoulder and myofascial chains (Myers T W, 2013) [20], (in and between muscles, around tendons, joint capsules), using a device generating deep pulsating vibrations, can provide increased ROM and reduced pain for patients with diagnosed primary FS.

The effect of treatment using devices generating deep pulsating vibrations has been tested clinically on horses where changes in muscle tone were measured by multifrequency bioimpedance analysis (Harrisson *et al*, 2015) [21]. The effect of a similar treatment procedure applied to the shoulders has been studied by Bhagwat, (2010) [22].

## Materials and Methods

### Patients

The selection of patients was made using online advertising. The inclusion criteria were a) patients diagnosed with primary FS and b) patients willing to participate in the study. Exclusion criteria included patients who suffered from trauma such as bone fractures, ligation in the shoulder or whiplash injury over the past six months as well as those who have performed arthrodesis, who were pregnant, had implanted prosthesis or suffered from severe osteoporosis.

52 patients applied for the study. 12 were excluded for meeting the exclusion criteria. 23 patients with FS were randomly selected. The 23 spots were made available via an online booking system and the 40 remaining applicants were invited by email. The first 23 patients signing up were called within two days to verify their diagnosis. The study was designed with three sets of three treatment sessions. The first set had five spots and the second and third had nine spots each. At the first session the patients were given written and oral information regarding the study, including background, purpose, study design, consequences and data processing. The patients gave a written consent that they had received the information as well accepting the terms and conditions of the study stating that the study was voluntary meaning they could choose to drop out at any given time, they were to receive no compensation other than the treatment itself and that they were not to undergo any other treatments during the study period.

Of the 23 patients who started the study, 17 completed all three treatments. Three patients interrupted and dropped off the study after the first treatment and two patients dropped off after the second treatment. One regained full ROM after the first treatment and decided not to continue, three patients cancelled for personal reasons and two patients excluded themselves from the study by getting other treatment in between the sessions. The gender distribution was 15 women and 8 men in the age range 27 - 89 years. The duration of symptoms was from two months to two years.

The study was approved by the Swedish Ethical Review Authority in the spring of 2018.

## Equipments

The devices used in the study to generate deep pulsating vibrations were Atlasbalans M1 and Atlasbalans M2. These devices provide mechanical vibrations at a variable frequency between 400 to 1200 pulsations per minute in a sine wave. Thermography camera FLIR T540 is used for documentation of ROM. A thermography camera was chosen to keep the patient's images anonymous. ROM was measured using a protractor with 170-180° assessed as full ROM with the arm straight up.

## Arrangement

The treatment included three treatment sessions. Treatment one and two were performed with 7 days intervals and the third treatment 37 days after the first treatment. Before the first treatment the patients were asked when and how the symptoms appeared. Before the second and third treatment the patients were asked about what they had experienced since the last session. Before each session, patients were also asked about their experience of perceived pain and their quality of sleep. No pain scales were used to measure the answers.

## Photographing

At each occasion, the movement of the arms was measured after a specific pattern, items 1-6 and images 1-6. The movements were performed with both right and left arm regardless of side with dysfunction. The same movements were performed before treatment and after treatment. The ROM was documented with a thermography camera, twelve images of the upper body at each occasion. Images were taken in six different positions, six before and six after treatment item 1-6. The thermography images make the patient anonymous and at the same time they can give an indication of inflammation (high heat) or poor circulation (abnormally cold). In order to repeat the measurements in the same way, all images were taken from the same distance (200 cm), height (150 cm) and from the same angle (90 degrees from the floor). Photography takes place with the patient standing against a light-colored background on a mat with markings where the patient should set their feet. This is to ensure that the patient always has the same starting position. The following angles were imaged in the following order (Item 1-6). This shows a patient with full ROM, 170-180°. Angles were measured with a digital protractor placed on the images.

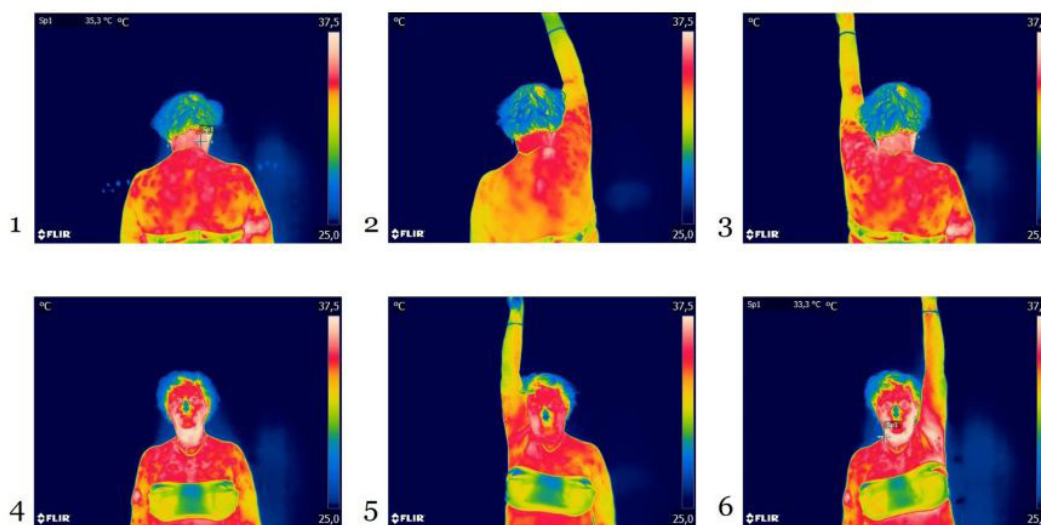


Figure 1: Thermographic image on item 1-6

1. Back to the camera, arms loosely hanging straight down.
2. Back to the camera, right arm is stretched straight up in abduction.
3. Back to the camera, left arm is stretched straight up in abduction.
4. Face to the camera, arms loosely hanging straight down.
5. Face to the camera, right arm is stretched straight up in abduction.
6. Face to the camera, left arm is stretched straight up in abduction.

**Treatment**

The treatment is a soft and deep massage treatment. Treatment of the neck, upper back and arm was performed with two devices for about 40 minutes. The following areas were treated.

1. M. Supraspinatus towards the shoulder joint.
2. All muscles between scapula and thoracic spine, M.Levator scapula, M.Serratus, M.Splenius, M.Rhomboideus, M.Trapezius thoracis.
3. Scapula's lower part, M.Infraspinatus, also M.Triceps brachii's origin at the shoulder joint.
4. Skull base and the neck side and the whole M.Trapezius cervicis towards the shoulder joint.
5. Lateral side of the upper arm, M.Deltoideus and all muscle attachments to deltoid tuberosity of humerus.
6. The lower part of the thoracic spine, the lower part of M.Trapezius thoracis and under the scapula to reach the M. subscapularis, with the arm behind the back.
7. M.Biceps brachii's long tendon, bursa intertubercularis and M.Pectoralis attachment to shoulder and upper arm.
8. M.Biceps brachii.
9. M. Pectoralis major and minor
10. M. Subclavius

**Results**

Of 23 patients who started the study, 17 completed all three treatments. Three discontinued after the first treatment (one regained full ROM after one treatment) and three terminated after treatment number two. Of the 17 who completed, seven regained full ROM. All patients were given increased ROM to varying degrees. 61 percent of total 23 patients experienced an improved quality of sleep. Two of the patients who regained full ROM have had the problems between one to two years. The concentration of heat in the neck noted on three patients, disappeared in all cases after the first treatment. Six patients had limited improvement after the treatment (See Table 1, Patient ID FS01, FS03, FS8, FS10, FS11 & FS20), and all of them have other issues correlated to fascia adhesions (Table 2 and 3).

Patient ID	Age	Gender	FS duration in months	°ROM Day 1 before	°ROM Day 1 after	°ROM Day 7 before	°ROM Day 1 after	°ROM Day 37 before	°ROM Day 1 after	Δ°ROM	Full ROM	Improved sleep
FS01	52	W	7-9	65	95	105	110	115	120	55		X
FS02	57	W	5-7	80	180	180	180	180	180	100	X	
FS03	42	W	14-16	50	90					40		X
FS04	41	W	7-9	100	180					80	X	
FS05	51	W	4-6	30	90					60		
FS06	56	M	6-8	80	120	125	140	140	150	70		X
FS07	50	W	6-8	65	130	75	115			50		X
FS08	42	W	5-7	65	90	95	110	95	110	45		X
FS09	46	W	5-7	135	180	180	180	180	180	45	X	X
FS10	48	W	4-6	50	80	70	80			30		
FS11	69	M	10-11	75	90	80	90	80	100	25		X
FS12	62	M	1-2	100	180	115	170	140	140	40		
FS13	89	W	11-13	65	115	100	150	150	160	95		
FS14	47	W	9-11	70	140	150	160	180	180	110	X	X
FS15	49	W	10-12	90	135	140	160	120	135	45		X
FS16	47	M	5-7	160	170	170	170			10	X	
FS17	47	W	3-5	135	150	160	160	160	160	25		
FS18	45	M	22-24	100	170	140	180	180	180	80	X	
FS19	58	M	12-14	135	160	130	170	130	170	35	X	

Patient ID	Age	Gender	FS duration in months	*ROM Day 1 before	*ROM Day 1 after	*ROM Day 7 before	*ROM Day 1 after	*ROM Day 37 before	*ROM Day 1 after	Δ*ROM	Full ROM	Improved sleep
FS20	68	W	6-8	50	130	100	125	80	85	35		
FS21	27	M	3-5	70	160	135	180	180	180	110	X	X
FS22	42	W	8-10	60	110	70	100	90	150	90		X
FS23	45	M	3-5	70	140	155	180	180	180	110	X	X

Table 1: Summary of the results

	No	>30°	>45°	>60°	>90°	Full	Imp sleep
Total	23	20	16	12	9	9	14
Percent	100 %	87%	70%	52%	39%	39%	61%

Table 2: Increased ROM in degrees calculated on all 23 patients in the study

	No	>30°	>45°	>60°	>90°	Full	Imp sleep
Total	17	15	13	12	10	9	12
Percent	100%	88%	76%	59%	53%	41%	71%

Table 3: Increased ROM in degrees calculated on 17 patients who continued the whole study

## Discussion

The study shows positive results for myofascial treatment, using a device generating deep pulsating vibrations, as an alternative for the participating patients diagnosed with Frozen Shoulder (FS). The result shows that the treatment, in a short time, provided increased ROM in the adhesive shoulder and in some cases the ROM was fully recovered. All patients perceived the treatment as pleasant and no patient's condition got worse after the treatment.

Nine patients regained full ROM and of these, seven were most likely in stage 2 of FS (Hannafin *et al*, 2000) [1], (one of them regained full ROM after the first treatment and dropped off the study). The other two patients regaining full ROM had had FS between one and two years, stage 3-4, and therefore might have been in a recovery phase, meaning that the treatment could have been speeding up an already existing healing process. In stage 2 of the disease, the inflammatory process in the synovial fluid begins to decrease and instead the connective tissue in the joint capsule begins to densify with increased fibrosis as a result. That could indicate that the treatment affects the flow in connective tissue and reduces the fibrous formation in the joint capsule so that the process turns faster as the inflammation processes have decreased. 61 percent, 14 of total 23 patients, also perceived an improved sleep.

Six of the eight patients that had limited effect of the treatment (less than 60° increased ROM) had other underlying symptoms than FS. Two patients had peritendinitis calcarea, one had had surgery in both knees, two patients had an atrophied deltoideus muscle and one had ceacum appendix surgery ten months prior to the first session. These problems may have had an effect on the results, perhaps due to connective tissue/muscle interactions, abnormal movement pattern, fascia adhesions and so on.

The documentation of the ROM was made with a thermography camera and these images at the same time show that some patients had a clearly increased heat image around the neck-shoulder portion before treatment which disappeared after the first treatment. Inflammation of the tissue gives an elevated heat image and the result indicates that as the flow in the tissue around the painful area improves, this gives a more even temperature in the tissue. There may be a connection between inflammation in the tissue and pain, as well as demonstrated in previous studies (Linnman *et al* 2011, Hoheisel *et al* 2015, & Wilke *et al* 2017) [23-25].

A major component of the fascia is HA, which affects the density in the fascia (Stecco *et al*, 2011, Stecco *et al.*, 2014) [10,16,17]. HA is a high molecular weight polysaccharide in healthy tissues and is a key component of the ECM in the loose fascia, including between deep fascia and muscle, within muscles and between the collagen layers in the deep fascia. It is also a major component of articular joint synovial fluid, where it provides the viscoelasticity and lubrication to protect the joint cartilage. It is known that the concentration and composition of HA in the ECM of the fascia is associated with inflammation and joint problems (Temple-Wong *et al.*, 2016) [14]. HA has an important significance for the slide and glide function and densification and adhesions in the fascia ECM are linked to reduced sliding ability (Langevin *et al.*, 2011; Chaitow, 2014) [12,13]. Though HA has a non-Newtonian behavior, it is possible that the deep vibrations and pressure affect the viscosity of the HA to decrease, in a short time. Massage, manipulation, or physical therapies can cause disaggregation of the pathologic chain-chain interactions and a reversal of the aggregation of the HA fragments, by an increase of the subcutis temperature to 40° there is a change in viscosity (Stecco *et al*, 2013) [4]. Stecco *et al.* assume that this increase in temperature will not alter the quantity of HA but rather its structure and associative behavior. Treatment which only increases the temperature therefore gives short lasting effects. When HA is subjected to mechanical stress, such as manual deep friction or vibration, it is depolymerized, and lower molecular mass polymers are generated which help to restore the quality of HA and heal and re-establish a normal tissue sliding in the endo-, peri- and epimysium and deep fascia. This smaller HA polymers are highly inflammatory, angiogenic and immunogenic (Noble, 2002;

Stecco *et al*, 2013, 2014) [4,16,17,26]. Stecco *et al*. suggest that manual manipulation with deep compression and friction is able to catalyze this reaction and that this self-resolving inflammatory reaction is the mechanism that restores the correct quantity and quality of substances in the fascia. The results indicate that myofascial treatment using a device generating deep pulsating vibrations reaches deeper in the tissue than manual manipulation and massage, but the physiological mechanism behind the successful treatments have to be further investigated. Ness *et al*. [27] and Usuki *et al*. [28] also have found that treatment with vibratory stimulation for spasticity gives promising results.

The study has a lot of deficits. It is a small study with a few patients, but it indicates a clear improvement in the ROM and the patients perceived reduced pain. Also, it is difficult to get patients to complete the treatment, as it may feel unjustified to continue as they have improved or got rid of their pain. There is also uncertainty with determining diagnosis, as there may be other underlying causes than FS to the shoulder problems. The duration period that the patients have had problems varies, which means that they have been in different phases (Hannafin *et al*, 2000) [1] and this most likely gives different effects of the treatment. Photographing and measurement of ROM are also a source of misinterpretation, in some cases the movement is not entirely pure abduction when the patients strain themselves and folded the body. Additional sources of error are the measurement of the angles with the protractor.

## Conclusion

The study indicates that myofascial treatment with deep pulsating vibrations could be a valuable alternative for shortening the healing process and providing increased ROM and thus quality of life for patients diagnosed with FS. Using this type of treatment in the care process for these patients could be an easy and pleasant way to shorten the course of the disease. Further studies are recommended with larger patient groups as well as clinical studies to evaluate and validate the treatment effect in general and the findings of this study. If validated, a treatment method for patients with FS, could mean great socioeconomic benefits and an increased quality of life [29].

## Conflict of Interest

This study was initiated by physician Håkan B after discovering that more than fifty patients got increased mobility as a result of myofascial treatment with deep pulsating vibrations. As the main author, Håkan B receives no financial contribution and guarantees the publishing ethics and the unbiasedness of the study. Camilla RN has been working independently with myofascial treatment since 2015 and receives no financial contribution. Hans B has been working with myofascial treatment since 2012 and has invented the myofascial treatment devices and the treatment process used in this study.

## References

1. Hannafin JA, Chiaia TA (2000) Adhesive capsulitis. A treatment approach. *Clin Orthop Res* 372: 95-109.
2. Zuckerman J D, Rokito A (2011) Frozen shoulder: a consensus definition. *J of shoulder elbow surg* 20: 322-32.
3. Kanbe K, Inoue K, Inoue Y, Chen Q (2009) Inducement of mitogenactivated protein kinases in frozen shoulders. *J Orthop Sci* 14: 56-61.
4. Stecco A, Gesi M, Stecco C, Stern R (2013) Fascial components of the myofascial pain syndrome. *Curr Pain Headache Rep* 17: 352.
5. Manske RC, Prohaska D (2008) Diagnosis and management of adhesive capsulitis. *Curr Rev Musculoskelet Med* 1: 180-9.
6. Comeaux Z (2011) Dynamic fascial release and the role of mechanical/ vibrational assist devices in manual therapies. *J Bodyw Mov Ther* 15: 35-41.
7. Kumka M, Bonar J (2012) Fascia: A morphological description and classification system based on a literature review. *J Can Chiropr Assoc* 56: 179-91.
8. Stecco C, Gagey O, Belloni A, Pozzuoli A, Porzionato A, et al. (2007) Anatomy of the deep fascia of the upper limb. Second part: Study of innervation. *Morphologie* 91: 38-43.
9. Bhattacharya V, Chaudhuri GR, Mishra B, Kumar U (2011) Demonstration of live lymphatic circulation in the deep fascia and its implication. *Eur J Plast Surg* 34: 99-102.
10. Stecco C, Stern R, Porzionato A, Macchi V, Masiero S, et al. (2011) Hyaluronan within fascia in the etiology of myofascial pain. *Surg Radiol Anat* 33: 891-6.
11. Stecco C, Fede C, Macchi V, Porzionato A, Petrelli L, et al. (2018) The Fasciocytes: A new cell devoted to fascial gliding regulation. *Clin Anat* 31: 667-76.
12. Langevin HM, Fox JR, Koptiuch C, Badger GJ, Greenan-Naumann AC, et al. (2011) Reduced thoracolumbar fascia shear strain in human chronic low back pain. *BMC Musculoskelet Disord* 12: s203.
13. Chaitow L (2014) Somatic dysfunction and fascia's gliding-potential. *J Bodyw Mov Ther* 18: 1-3.
14. Temple-Wong MM, Ren S, Quach P, Hansen BC, Chen AC, et al. (2016) Hyaluronan concentration and size distribution in human knee synovial fluid: Variations with age and cartilage degeneration. *Arthritis Res Ther* 18: 18.
15. Bordonni B, Zanier E (2014) Clinical and symptomatological reflections: The fascial system. *J Multidiscip Healthc* 7: 401-11.
16. Stecco A, Meneghini A, Stern R, Stecco C, Imamura M (2014) Ultrasonography in myofascial neck pain: Randomized clinical trial for diagnosis and follow-up. *Surg Radiol Anat* 36: 243-53.
17. Stecco A, Stecco C, Raghavan P (2014) Peripheral Mechanisms Contributing to Spasticity and Implications for Treatment. *Curr Phys Med Rehabil Rep* 2: 121-7.
18. Cowman MK, Schmidt TA, Raghavan P, Stecco A (2015) Viscoelastic Properties of Hyaluronan in Physiological Conditions. *F1000Res* 4: 622.
19. Okita M, Yoshimura T, Nakano J, Motomura M, Eguchi K (2004) Effects of reduced joint ROM on sarcomere length, collagen fibril arrangement in the endomysium, and hyaluronan in rat soleus muscle. *J Muscle Res Cell Motil* 25: 159-66.
20. Myers T (2013) *Anatomy trains*. Third edition. Elsevier.

21. Harrison AP, Elbrønd VS, Riis-Olesen K, Bartels EM (2015) Multi-frequency bioimpedance in equine muscle assessment. *Physiol Meas* 36: 453-64.
22. Bhagwat S (2010) Role of Matrix-Rhythm-Therapy in the treatment of non-traumatic restricted movements of shoulder. Annual conference of physiotherapy, Mangalore.
23. Linnman C, Appel L, Fredrikson M, Gordh T, Söderlund A, et al. (2011) Elevated [11C]-D Deprenyl uptake in chronic whiplash associated disorder suggests persistent musculoskeletal inflammation. *PLoS ONE* 6: e19182.
24. Hoheisel U, Rosner J, Mense S (2015) Innervation changes induced by inflammation of the rat thoracolumbar fascia. *Neuroscience* 300: 351-9.
25. Wilke J, Schleip R, Klingler W, Stecco C (2017) The lumbodorsal fascia as a potential source of low back pain: A narrative review. *BioMed Res* 2017: 5349620.
26. Noble PW (2002) Hyaluronan and its catabolic products in tissue injury and repair. *Matrix Biol* 21: 25-9.
27. Ness LL, Field-Fote EC (2009) Effect of whole-body vibration on quadriceps spasticity in individuals with spastic hypertonia due to spinal cord injury. *Restor Neurol Neurosci* 27: 621-31.
28. Usuki F, Tohyama S (2011) Vibration therapy of the plantar fascia improves spasticity of the lower limbs of a patient with fetal-type Minamata disease in the chronic stage. *BMJ Case Rep* 2011: bcr0820114695.
29. Booth CM, Cortina-Borja MJ, Theologis TN (2001) Collagen accumulation in muscles of children with cerebral palsy and correlation with severity of spasticity. *Dev Med Child Neurol* 43: 314-20.

Submit your next manuscript to Annex Publishers and benefit from:

- ▶ Easy online submission process
- ▶ Rapid peer review process
- ▶ Online article availability soon after acceptance for Publication
- ▶ Open access: articles available free online
- ▶ More accessibility of the articles to the readers/researchers within the field
- ▶ Better discount on subsequent article submission

Submit your manuscript at

<http://www.annexpublishers.com/paper-submission.php>