

# Proposal for a Guideline-Compliant HCC-Imaging Diagnostic Protocol Based on Perfusion-CT Quantification: A Feasibility Study

Thaiss WM<sup>5</sup>, Ekert K<sup>1</sup>, Haberland U<sup>2</sup>, Kloth C<sup>3</sup>, Kaufmann S<sup>1</sup>, Nikolaou K<sup>1</sup>, Bitzer M<sup>4</sup> and Horger M<sup>1</sup>

<sup>1</sup>Eberhard Karls University, Department of Radiology, Diagnostic and Interventional Radiology, Tübingen, Germany

<sup>2</sup>Siemens Healthcare Limited, Sir William Siemens Square, Frimley, Camberley, United Kingdom

<sup>3</sup>Department of Diagnostic and Interventional Radiology, University Hospital Ulm, Albert-Einstein-Allee, Ulm, Germany

<sup>4</sup>Department of Internal Medicine I, Eberhard-Karls-University, Tübingen, Germany

<sup>5</sup>Department of Nuclear medicine, University Hospital Ulm, Albert-Einstein-Allee, Ulm, Germany

\*Corresponding author: Ekert K, MD, Eberhard Karls University, Department of Radiology, Diagnostic and Interventional Radiology, Hoppe-Seyler-Str. 3, D-72076 Tübingen, Germany, Fax: +49 7071 29-82087, Tel: +49 7071 29-86677,

E-mail: kaspar.ekert@med.uni-tuebingen.de

**Citation:** Thaiss WM, Ekert K, Haberland U, Kloth C, Kaufmann S, et al. (2021) Proposal for a Guideline-Compliant HCC-Imaging Diagnostic Protocol Based on Perfusion-CT Quantification: A Feasibility Study. J Cancer Sci Clin Oncol 8(1):103

## Abstract

**Purpose:** To adapt the perfusion-CT (PCT) examination-protocol in patients with liver cirrhosis and suspected hepatocellular carcinoma (HCC) while keeping diagnostic accuracy and qualitative assessment of tumor enhancement patterns (wash-in/wash-out) at comparable radiation dose.

**Materials and Methods:** 123 liver PCT examinations were evaluated retrospectively in 76 patients (mean age 64.8 ± 10.0 years, 6 female) between October 2015 and December 2016 for suspected HCC. PCT (temporal-resolution 1.5sec/80kVp/100mAs for 40sec) was used and arterial liver perfusion (ALP), portal-venous perfusion (PVP) and hepatic perfusion index (HPI) were quantified. Two additional spiral data sets after 80 sec were included to generate subtraction maps for arterial phase (AP, 18.5sec post injection), early (EPVP, 40sec) and late portal-venous phase (LPVP, 86sec), as well as LPVP minus EPVP to quantify wash-out.

**Results:** 141 lesions were analyzed. In 10 examinations no HCC was found at PCT. HCCs could be identified and characterized by wash-in and wash-out enhancement patterns as well as in terms of ALP (mean 45.6±22.9 mL/100mL/min), PVP (7.8±14 mL/100mL/min) and HPI (88.1±18.9%). Ratios of HCC to liver tissue showed a mean of 7.3 (AP), 4.8 (EPVP) and 1.1 (LPVP) and 0.1 (LPVP-EPVP). Dose length product for perfusion-CT was 1003±89 mGy x cm, resulting in a mean effective dose of 15.05 mSv.

**Conclusions:** Perfusion-CT with added late phase imaging can provide the information necessary to characterize and diagnose HCC including guideline-compliant assessment of contrast wash-out kinetics.

**Keywords:** Liver Perfusion; HCC; Computed Tomography

**List of abbreviations:** AASLD: American Association for the Study of Liver Diseases; ALP: Arterial Liver Perfusion; AP: Arterial Phase; CECT: Contrast Enhanced CT; EASL: European Association for the Study of Liver Diseases; EPVP: Early Portal-Venous Phase; HCC: Hepatocellular Carcinoma; HPI: Hepatic Perfusion Index; LPVP: Late Portal-Venous Phase; PCT: Perfusion-CT; PVP: Portal-Venous Perfusion

## Introduction

Hepatocellular carcinoma (HCC) is among the most common gastrointestinal tumors and a cancer entity for which diagnosis can be made with imaging alone [1]. Current international guidelines for non-invasive diagnosis of hepatocellular carcinoma such as the American Association for the Study of Liver Diseases (AASLD) and the European Association for the Study of Liver Diseases (EASL) define the typical HCC vascular pattern as early hyper-enhancement (wash-in) in the arterial phase followed by also early wash-out in the portal-venous or late equilibrium phase [1,2]. While some differences exist between these guidelines with respect to the size of hepatic lesions to be characterized and the kind and number of imaging techniques necessary for making a definite diagnosis (mostly CT and MRI), protocol prerequisites for CT typically include three to four phase examinations for assessment of HCC-typical enhancement patterns [1].

All of these imaging modalities have individual drawbacks such as radiation exposure and potentially inadequate delay times in CT to optimally assess wash-in and wash-out contrast kinetics, long examination times as well as the presence of disturbing motion artifacts - in particular in patients with ascites or portal encephalopathy - for MRI or of small lesion size including hypovascular HCC [3,4]. Moreover, differentiation of HCC from its precursors (regenerative nodules, low-grade and high-grade dysplastic nodules) can be challenging due to some overlap in imaging findings and different magnitudes of arterial vs. portal-venous blood supply [5,6]. Finally, both these referred guidelines recommend no definite classification of hepatic lesions < 1 cm as compared to nodules > 1 cm due to difficulties in their characterization [1]. In recent years, liver perfusion-CT protocols (PCT) used for detection and characterization of hepatic lesions in cirrhotic patients have gained more attention [7-9]. This technique uses lower energy examinations with short measurement times (mostly about 40s), high temporal resolution and sophisticated post-processing software to quantify both the arterial and portal-venous blood supply to the liver and liver tumors. This approach is comparable with CT-hepatic arteriography + CT-portography [10] but non-invasive and with quantifiable and reproducible data acquisition. Knowingly, along the so-called hepatocarcinogenesis pathway, lesions become more and more arterially supplied during their malignant transformation and thus their characterization with PCT is not only technically feasible, but also possible for small (<1 cm) lesions. However, one major limitation of short PCT-protocols is the fact that they potentially miss the wash-out phase which according to the current recommendations in international guidelines should always be documented as it is among the most specific imaging features for HCC in the clinical setting of liver cirrhosis, hepatitis B or C and hemochromatosis [11]. To be in line with these guidelines, and to additionally gain relevant information with respect to the amount of arterial blood supply of liver lesions, later acquisition phases are required for PCT. Such a modified PCT-liver protocol could provide all the necessary information with additional helical scans (non-enhanced, arterial, and portal-venous).

The main goal of this study was to adapt the current liver CT-perfusion protocol to the requirements of modern imaging guidelines for non-invasive diagnosis of HCC documenting additionally also the wash-out contrast kinetics by using supplemental late measurement points while keeping radiation exposure for the patient within ranges that are comparable with those of a 3-4-phase contrast-enhanced CT-protocol. For this task, identification of the peak enhancement times for both liver parenchyma and liver tumor was essential to obtain the best discriminatory tumor-to-liver ratios for performing image subtraction.

## Material and Methods

### Patients

All consecutive liver perfusion CT examinations between October 2015 and December 2016 were included. Patients underwent perfusion CT for suspected HCC due to prior ultrasound or MRI examination. Other inclusion criteria were baseline and follow-up examinations before and under systemic therapy with antiangiogenic agents. Exclusion criteria included patients after transarterial chemoembolization, local ablation or radiotherapy as well as impaired renal function or known allergy to iodine contrast agents. 123 examinations were evaluated retrospectively in 76 patients (mean age  $64.8 \pm 9.9$  years, 6 female). This retrospective study was approved by the ethics committee (442/2009BO2).

### CT Perfusion protocol

A 256-row CT scanner (Somatom Definition Flash, Siemens Healthineers, Forchheim, Germany) was used. Adaptive spiral scanning technique with 80 kVp, 100 mAs,  $64 \times 0.6$  mm collimation, and scan time of 40 seconds (26 helical scans) at a time resolution of 1.5 sec per spiral data set was used covering the whole liver volume. Scan length (13-17.6 cm) was adapted based on the liver size on the primary localizer. An unenhanced scan was performed for subtraction analysis. A dual-head pump injector (Medtron, Saarbruecken, Germany) was used for the administration of 50 ml Ultravist 370 (Bayer, Leverkusen, Germany) with a flow rate of 5 ml/s. After 40 seconds, a gap was planned and two additional scans were conducted at 85.8 and 87.2 seconds for ensuring acquisition of late portal venous phase image data which should allow for documentation of tumor contrast wash-out. Scanning duration is limited to 90 sec by the vendor. Shallow breathing was instructed for the patients during the time of examination. Axial images with a slice thickness of 3 mm were reconstructed for perfusion analysis using a medium smooth tissue convolution kernel (B10f).

### Perfusion-CT Analysis

Syngo Dynamic Angio (Siemens Healthineers, Forchheim, Germany) was used for data evaluation. For baseline generation, the mean of the two earliest spiral data sets were averaged to reduce noise. The data set for arterial enhancement were defined depending on the time activity curve (maximum arterial enhancement of the liver (AP), mean  $18.5 \pm 1.75$  sec after the scan was started). Early portal-venous enhancement (EPVP,  $40.0 \pm 3.5$  sec after the scan was started) and late portal-venous phase (LPVP, 85.8-87.2 sec after contrast injection) were generated accordingly with averages of two helical scans at these time points to reduce noise as described below. The wash-out pattern for HCC was present when the contrast medium density of the HCC was less than in the surrounding liver. This was assessed both qualitatively as well as quantitatively with calculated ratios to the surrounding healthy liver tissue.

HepaCare (prototype software, Version 3.0, Siemens Healthineers, Forchheim, Germany) was used to generate subtraction maps. The above-mentioned data sets for each time point were loaded, registered and the non-enhanced baseline scan was subtracted from the arterial, early portal-venous and late portal-venous scans. The generated subtractions were archived to PACS for reading.

Two radiologists with with 4 and 8 years of experience in abdominal and liver oncological imaging drew regions of interest in the HCCs in the series where the lesions were best detectable and in non-affected liver tissue of the same lobe. The readers were blinded to the radiology report.

Additionally, the liver-PCTs were analyzed using whole-body perfusion software on SyngoVia VB 30A (Siemens Healthineers, Forchheim, Germany). First, automatic motion correction and threshold-based reduction of noise and exclusion of bone, fat and air were performed.

Lesion detection was processed by a liver quantification protocol which considers the dual arterial and portal-venous blood supply to the liver and tumors performing separate quantification using a dual input maximum slope approach. A region of interest (ROI) was defined for the abdominal aorta, the portal vein and the spleen to generate input values. ROI was drawn manually at the maximal hypervascular tumour outline. Lesion assessment is optimal if using arterial liver perfusion color-coded maps and arterial liver perfusion (ALP; mL/100 mL/min), portal-venous perfusion (PVP; mL/100 mL/min), and hepatic perfusion index (HPI; %) were determined.

For comparison of liver dose, liver PCT and four-phase contrast enhanced CT (CECT) for whole liver imaging were compared based on the calculation assumptions made in the Tissue-Weighting Factors for International Commission on Radiological Protection (ICRP) Publication 103 [12].

### Four-phase liver CT

Radiation exposure for a four-phase liver CT was calculated in another patient cohort (55 patients, 43 male; mean age, 64 years) with known liver cirrhosis who were referred to CT-diagnostic for exclusion of HCC.

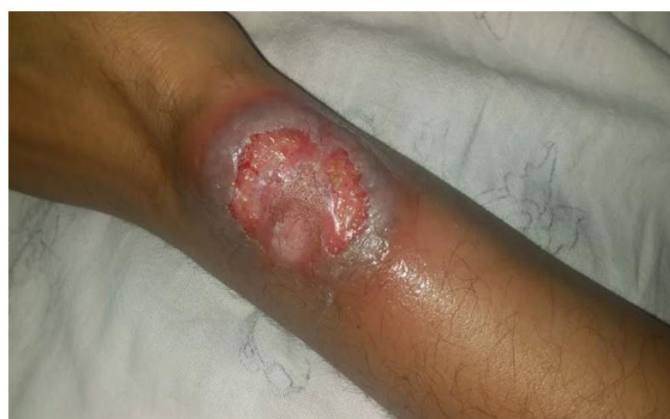### Statistical analysis

Values are reported as mean  $\pm$  standard deviation. Ratios for HCC to liver tissue were calculated. One-way ANOVA was used for group differences between time points, p values were corrected with the Bonferroni method for multiple testing. P values  $< 0.05$  were considered significant. Interreader agreement was assessed using intraclass correlation coefficients (ICC) for each parameter pair. The calculations were performed using Prism 7 (GraphPad Software, La Jolla California, USA).

## Results

### Liver and tumor enhancement ratios

In 10 examinations no HCC was found. 141 lesions were analyzed; all tumors could be identified and characterized by wash-in and wash-out enhancement pattern (Figure 1). 21 lesions underwent biopsy and were graded as HCC histologically; the other lesions

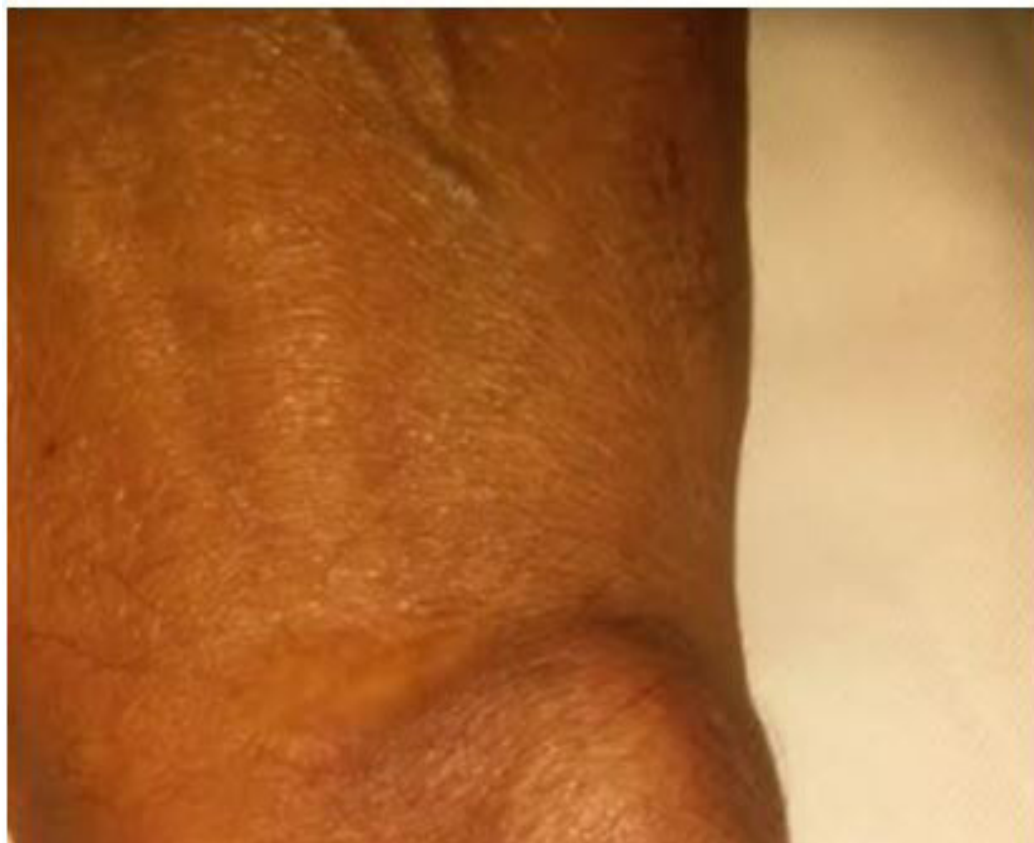

**Figure 1:** Newly diagnosed HCC in a 76-year old male (A) and a 81-year old male (B) with focal HCC. Subtraction images for arterial phase minus baseline (AP), early portal-venous phase minus baseline (EPVP), late portal-venous phase (LPVP) and LPVP minus EPVP are shown from top to bottom. Notice wash-in (top row) and wash-out (bottom) for all lesions

were validated as HCCs with follow-up examinations or MRI. Lesion size range was from 0.8 to 4.9 cm, mean 2.4 cm.

Normal liver tissue HU with peak *arterial* enhancement minus baseline (non-enhanced, AP) was  $18.2 \pm 10.4$  HU (range, 4- 59 HU) whereas HCCs had HU values of  $79.0 \pm 37.0$  HU (range, 20 – 206 HU).

At *early portal-venous* enhancement minus baseline (EPVP), liver tissue attenuation reached  $40.8 \pm 23.9$  HU (range, 8 – 99 HU) while HCCs attenuation increased to  $135.7 \pm 57.4$  HU (range, 24– 252 HU). During *late portal-venous phase* minus baseline (LPVP), liver tissue enhanced to a mean of  $81.7 \pm 28.5$  HU (range 21 – 174 HU) and HCCs to  $88.1 \pm 36.2$  HU (range, 21-243 HU). In LPVP-EPVP subtraction maps, liver tissue showed HU values of  $48.2 \pm 21.3$  HU (range, 4 – 48 HU) and HCCs  $3.5 \pm 12.2$  HU (range, -34 – 84 HU, ANOVA  $F = 197$ ,  $p < 0.0001$ ; Figure 2). All values showed significant differences, both between liver tissue and HCC at an individual time points during measurement, as well as compared to different time points with the exception of the comparison between liver tissue and HCC at LPVP ( $p = 0.9$ ).



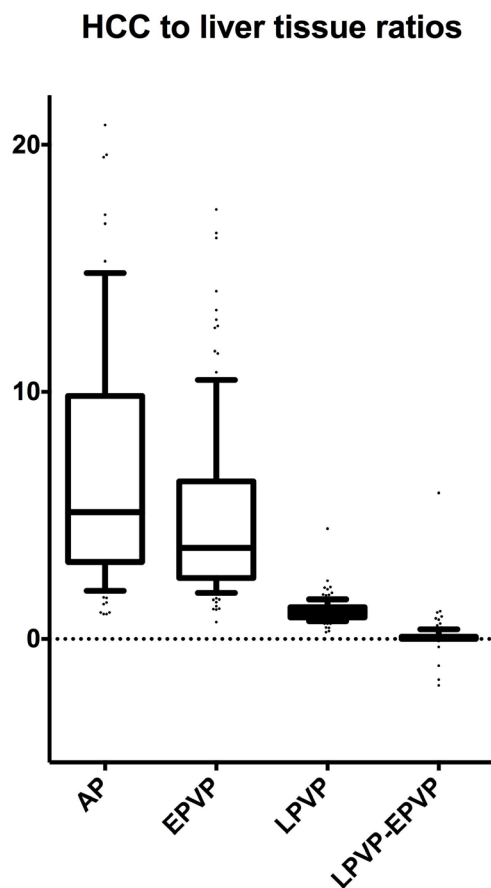
**Figure 2:** Hounsfield units for subtraction images for arterial phase minus baseline (AP), early portal-venous phase minus baseline (EPVP), late portal-venous phase (LPVP) and LPVP minus EPVP are given for liver tissue (left) and HCC (right). Whiskers of box-plots indicate 95% percentile, values outside are shown as dots. One-way ANOVA revealed significant group differences between all individual time points for HCC and liver tissue, respectively ( $F = 197$ ,  $p < 0.0001$ ), except for the comparison between liver tissue and HCC at LPVP ( $p = 0.9$ )

Ratios of HCC to liver tissue showed a mean of 7.7 for AP, 4.9 for EPVP, 1.1 for LPVP and 0.1 for LPVP-EPVP ( $F = 45$ ,  $p < 0.0001$ ; Figure 3). Significant differences were present between all ratios, except for LPVP vs. LPVP-EPVP imaging ( $p = 0.5$ ).

Intraclass correlation coefficients (ICC) for all lesions was 0.79.

### Quantitative perfusion-CT tumor parameters

Arterial liver perfusion of HCCs resulted in a mean of  $45.6 \pm 22.9$  mL/100mL/min, portal venous perfusion was  $7.8 \pm 14$  mL/100mL/min and hepatic perfusion index was  $88.1 \pm 18.9$  %.



**Figure 3:** Ratios between HCC and liver tissue at arterial phase minus baseline (AP), early portal-venous phase minus baseline (EPVP), late portal-venous phase (LPVP) and LPVP minus EPVP are given. One-way ANOVA revealed significant group differences between all ratios, ( $F = 45p, < 0.0001$ ), except for LPVP vs. LPVP-EPVP imaging ( $p = 0.5$ )

## Radiation dose

Dose length product for perfusion-CT was  $1003 \pm 89$  mGy x cm, resulting in an effective liver dose of 15.05 mSv. Calculated effective dose of a typical four phase examination protocol for the liver was 16.75 mSv (unenhanced: 100kVp, 40 mAs: DLP 67 mGy x cm \* 0.015 = 1.00 mSv; arterial phase: 120 kVp, 150 mAs: 390 mGy x cm \* 0.015 = 5.85 mSv; portal-venous phase: 120 kVp, 140 mAs: 330 mGy x cm \* 0.015 = 4.95 mSv; delayed phase: 120 kVp, 140 mAs: 4.95 mSv).

## Discussion

Non-invasive characterization of liver lesions in the setting of liver cirrhosis, hepatitis B or C and hemochromatosis is of utmost importance as all these disorders have the potential for development of HCC [1]. Our study proposes a modified CT-examination protocol consisting of twenty-six whole-liver helical scans including the non-enhanced, arterial, early portal-venous and late portal-venous phases, thus being capable of visualizing the HCC-typical enhancement patterns (wash-in and wash-out) in addition to quantifying the amount of arterial blood supply of the tumor for enhanced characterization. For this purpose, some limitations had to be overcome. First, the scanning duration time is limited by the vendor to 90 seconds which at least for visual assessment of wash-out kinetics might be too short. Therefore, we hypothesized that wash-out kinetic could be identified with the help of late portal-venous phase acquisitions. Second, radiation dose for PCT consisting of a total of twenty-six helical scans had to be minimized. Third, the proper time points along the tumor time-density-curves had to be assessed first.



For visualization of wash-in contrast kinetics, the abundance of arterial helical scans covering the whole liver offers optimal conditions to identify the wash-in phase as one of the entailed risks in inadequately delayed four-phase CECT. The optimal contrast of lesion-to-background (liver parenchyma) was reached at the peak arterial enhancement time for HCC at a mean of 18.5 seconds. These results are in line with those of previous works dealing with this issue as Ma et al. found that the mean times of contrast enhancement (wash-in, peak, and wash-out) were  $18 \pm 4.2$  seconds,  $27 \pm 3$  seconds, and  $55.7 \pm 21$  seconds for HCC, respectively [13].

Contrast enhancement (wash-in) continued over the early portal-venous phase with an equilibrium at the end of the first scanning period of 40 seconds and dropping proportionally after 80 seconds. Images obtained at this latter time point resulted in the lowest ratio (0.1) of HCC to surrounding liver parenchyma (wash-out) in all our patients. Hence, late portal-venous images (85.8 to 87.2 seconds post-injection) seem to be sufficient for visualization of wash-out tumor kinetics if using image subtraction techniques with additional late portal-venous phase scans. It is beyond the scope of this report to describe the perfusion characteristics of HCC, but all our tumors could be quantified with respect to the degree of arterial liver perfusion showing an average value of 88% which is in line with previous publications on this topic [8,9,14,15]. Using our examination protocol including contrast agent volume and flow, the best series for image subtraction and display of wash-in and wash-out dynamics were an early arterial phase and a subtraction of a late portal-venous phase minus early portal-venous phase. Despite twenty-six measurements performed according to our PCT-protocol, radiation exposure was slightly lower compared to that of a four-phase normal-dose CECT, which is in line with previous calculation studies and below the calculations by Gawlitza et al [16].

The rationale for performing hepatic PCT was debated in many previous reports. In our opinion, the assessment of the degree of arterial tumor supply in the clinical setting of liver cirrhosis significantly increases both sensitivity and specificity of CT for the diagnosis of HCC and discrimination from its precursors. Current guidelines in the diagnosis of HCC recommend the use of either multiphase CT or dynamic contrast-enhanced MRI in order to detect the characteristic enhancement pattern of HCC consisting of arterial phase enhancement (wash-in) and wash-out [1,2]. The presence of tumor capsule and the interval growth are additional findings in support of the diagnosis of HCC, but the latter sign implies repeated (surveillance) imaging [17]. While the presence of wash-in and wash-out is expected in all encapsulated HCC larger than 2cm in diameter, these enhancement features may be missing in smaller lesions or hypovascular HCC [4,18,19].

One major challenge with three or four phases CT is to anticipate the precise timing of image acquisition after administration of the contrast bolus in order to visualize HCC-typical contrast kinetics [20,21]. For increased detection of wash-in, dual phase arterial scan protocols have been advocated in order to improve detection of hypervascular HCC [22,23]. Detection of tumor contrast wash-out can also be challenging and is dependent not only on the degree of portal-venous supply of the tumor, but also on the degree of arterial supply to the liver parenchyma as both contribute essentially to the final tissue contrast. Tan et al. recommended a cut-off of 10 HU attenuation difference between the arterial and equilibrium phases as a simple and objective method that could be included as an adjunct to visual assessment to improve sensitivity for determining lesion wash-out on CT [24]. Liu et al. suggested a cut-off value of  $\geq 107\%$  attenuation ratio between portal-venous and delayed phase for defining wash-out in patients with HCC [25].

Previous reports also suggested the use of enhancement ratios for more confident detection of the typical HCC-enhancement patterns [14,26]. In contrast, PCT enables accurate tumor perfusion quantification. This could be of particular interest in hypovascular HCC (about 20%) which belong to the group of liver nodules exhibiting a nonspecific vascular profile [26]. Using HPI or ALP maps, even hypovascular liver lesions are clearly detectable on PCT as the HPI of cirrhotic livers is lower compared to HCC. As cirrhotic livers comprise fibrotic tissue intermixed with hepatocytes, they often lead to portal hypertension and consequently poor wash-in and wash-out behavior [9]. At our institution PCT constitutes standard routine protocol for the differentiation of suspected hyperarterial liver lesions and no 3-4-phase CECT is acquired as a consequence. The collected perfusion data renders standard CECT for differentiation of HCC second-tier.

Finally, the use of separate calculation of arterial vs. portal-venous blood supply to liver lesions generates color-coded maps which reflect the same enhancement pattern as with the use of wash-in and wash-out image series as they objectify the same shifting between hepatic arterial and portal-venous blood supply in liver tumors as well as in liver parenchyma (ALP vs. PVP). Other arguments in support of perfusion quantification are delivered by recent reports emphasizing the role of PCT-derived perfusion parameters as predictors of response to sorafenib systemic therapy [27-29], or TACE [30,31].

Our study has some limitations. First, it was retrospective in character. Second, there was no histologic proof of HCC, but indirect confirmation by non-invasive imaging and follow-up. Our examination protocol focused on the liver and did not cover eventual distant metastasis, however, our examination can detect local lymphadenopathy or portal vein thrombosis.

## **Conclusion**

The refined perfusion-CT protocol with added late phase imaging can provide the information necessary to characterize and diagnose HCC according to both the current recommendations of international guidelines and also based on tumor perfusion quantification with wash-in and wash-out at a comparable radiation dose to standard three or four phase CT.



## References

1. Heimbach JK, Kulik LM, Finn RS (2017) AASLD guidelines for the treatment of hepatocellular carcinoma. *Hepatology* 67: 358-80.
2. EASL–EORTC (2012) Clinical Practice Guidelines: Management of hepatocellular carcinoma. *Journal of Hepatology* 56: 908-43.
3. Choi YR, Chung JW, Yu MH, Lee M, Kim JH (2018) Diagnostic accuracy of contrast-enhanced dynamic CT for small hypervascular hepatocellular carcinoma and assessment of dynamic enhancement patterns: Results of two-year follow-up using cone-beam CT hepatic arteriography. *PLOS ONE* 13: e0203940.
4. Forner A, Vilana R, Ayuso C (2007) Diagnosis of hepatic nodules 20 mm or smaller in cirrhosis: Prospective validation of the noninvasive diagnostic criteria for hepatocellular carcinoma. *Hepatology* 47: 97-104.
5. Krinsky G (2004) Imaging of Dysplastic Nodules and Small Hepatocellular Carcinomas: Experience with Explanted Livers. *Intervirology* 47: 191-8.
6. Thaïss WM, Kaufmann S, Kloth C, Nikolaou K, Bösmüller H, et al. (2016) VEGFR-2 expression in HCC, dysplastic and regenerative liver nodules, and correlation with pre-biopsy Dynamic Contrast Enhanced CT. *Eur J Radiol* 85: 2036-41.
7. Atzidakis A, Perisinakis K, Kalarakis G (2018) Perfusion-CT analysis for assessment of hepatocellular carcinoma lesions: diagnostic value of different perfusion maps. *Acta Radiologica* 2018: 028418511879120.
8. Ippolito D, Sironi S, Pozzi M (2008) Hepatocellular Carcinoma in Cirrhotic Liver Disease. *Academic Radiology* 15: 919-27.
9. Kaufmann S, Horger T, Oelker A (2015) Characterization of hepatocellular carcinoma (HCC) lesions using a novel CT-based volume perfusion (VPCT) technique. *Eur J Radiol* 84: 1029-35.
10. Ohki T, Tateishi R, Akahane M (2013) CT With Hepatic Arteriography as a Pretreatment Examination for Hepatocellular Carcinoma Patients: A Randomized Controlled Trial. *The American Journal of Gastroenterology* 108: 1305-13.
11. Rimola J, Forner A, Reig M (2009) Cholangiocarcinoma in cirrhosis: absence of contrast washout in delayed phases by magnetic resonance imaging avoids misdiagnosis of hepatocellular carcinoma. *Hepatology* 50: 791-8.
12. Christner JA, Kofler JM, McCollough CH (2010) Estimating effective dose for CT using dose-length product compared with using organ doses: consequences of adopting International Commission on Radiological Protection publication 103 or dual-energy scanning. *AJR American journal of roentgenology* 194: 881-9.
13. Ma X, Samir AE, Holalkere N-S, Sahani DV (2008) Optimal Arterial Phase Imaging for Detection of Hypervascular Hepatocellular Carcinoma Determined by Continuous Image Capture on 16-MDCT. *American Journal of Roentgenology* 191: 772-7.
14. Kurucay M, Kloth C, Kaufmann S (2017) Multiparametric imaging for detection and characterization of hepatocellular carcinoma using gadoteric acid-enhanced MRI and perfusion-CT: which parameters work best? *Cancer Imaging* 17: 10.1186/s40644-017-0121-9
15. Syha R, Gatidis S, Grözinger G (2016) C-arm computed tomography and volume perfusion computed tomography (VPCT)-based assessment of blood volume changes in hepatocellular carcinoma in prediction of midterm tumor response to transarterial chemoembolization: a single center retrospective trial. *Cancer Imaging* 16: 10.1186/s40644-016-0088-y

16. Gawlitza J, Haubenreisser H, Meyer M (2016) Comparison of organ-specific-radiation dose levels between 70 kVp perfusion CT and standard tri-phasic liver CT in patients with hepatocellular carcinoma using a Monte-Carlo-Simulation-based analysis platform. *European journal of radiology open* 3: 95-9.
17. Anis M, Irshad A (2011) Imaging of Hepatocellular Carcinoma: Practical Guide to Differential Diagnosis. *Clinics in Liver Disease* 15: 335-52.
18. Khalili K, Kyoung Kim T, Jang H-J, Kochak Yazdi L, Guindi M, et al. (2011) Indeterminate 1-2-cm nodules found on hepatocellular carcinoma surveillance: Biopsy for all, some, or none? *Hepatology* 54: 2048-54.
19. Sangiovanni A, Manini MA, Iavarone M (2009) The diagnostic and economic impact of contrast imaging techniques in the diagnosis of small hepatocellular carcinoma in cirrhosis. *Gut* 59: 638-44.
20. Tanabe M, Kanki A, Wolfson T (2016) Imaging Outcomes of Liver Imaging Reporting and Data System Version 2014 Category 2, 3, and 4 Observations Detected at CT and MR Imaging. *Radiology* 281: 129-39.
21. Pugacheva O, Matsui O, Kozaka K (2011) Detection of small hypervascular hepatocellular carcinomas by EASL criteria: Comparison with double-phase CT during hepatic arteriography. *European Journal of Radiology* 80: e201-e6.
22. Kim T, Murakami T, Hori M (2002) Small Hypervascular Hepatocellular Carcinoma Revealed by Double Arterial Phase CT Performed with Single Breath-Hold Scanning and Automatic Bolus Tracking. *American Journal of Roentgenology* 178: 899-904.
23. Murakami T, Kim T, Takamura M (2001) Hypervascular Hepatocellular Carcinoma: Detection with Double Arterial Phase Multi-Detector Row Helical CT. *Radiology* 218: 763-7.
24. Tan CH, Thng CH, Low AS (2011) Wash-out of hepatocellular carcinoma: quantitative region of interest analysis on CT. *Annals of the Academy of Medicine, Singapore* 40: 269-75.
25. Liu YI, Shin LK, Jeffrey RB, Kamaya A (2013) Quantitatively Defining Washout in Hepatocellular Carcinoma. *American Journal of Roentgenology* 200: 84-9.
26. Erra P, Puglia M, Ragozzino A (2015) Appearance of hepatocellular carcinoma on gadoxetic acid-enhanced hepato-biliary phase MR imaging: a systematic review. *La radiologia medica* 120: 1002-11.
27. Ippolito D, Querques G, Okolicsanyi S (2018) Dynamic contrast enhanced perfusion CT imaging: A diagnostic biomarker tool for survival prediction of tumour response to antiangiogenetic treatment in patients with advanced HCC lesions. *European Journal of Radiology* 106: 62-8.
28. Ippolito D, Querques G, Pecorelli A (2018) Diagnostic Value of Quantitative Perfusion Computed Tomography Technique in the Assessment of Tumor Response to Sorafenib in Patients With Advanced Hepatocellular Carcinoma. *Journal of Computer Assisted Tomography* 2018: 10.1097/rct.0000000000000807.
29. Kaufmann S, Thaïss WM, Schulze M (2018) Prognostic value of perfusion CT in hepatocellular carcinoma treatment with sorafenib: comparison with mRECIST in longitudinal follow-up. *Acta radiologica* 59: 765-72.

30. Borgheresi A, Gonzalez-Aguirre A, Brown KT (2018) Does Enhancement or Perfusion on Preprocedure CT Predict Outcomes After Embolization of Hepatocellular Carcinoma? *Academic Radiology* 2018: 10.1016/j.acra.2018.02.027.
31. Popovic P, Leban A, Kregar K, Garbajs M, Dezman R, et al. (2017) Computed tomographic perfusion imaging for the prediction of response and survival to transarterial chemoembolization of hepatocellular carcinoma. *Radiology and Oncology* 52: 14-22.

Submit your next manuscript to Annex Publishers and benefit from:

- ▶ Easy online submission process
- ▶ Rapid peer review process
- ▶ Online article availability soon after acceptance for Publication
- ▶ Open access: articles available free online
- ▶ More accessibility of the articles to the readers/researchers within the field
- ▶ Better discount on subsequent article submission

Submit your manuscript at  
<http://www.annexpublishers.com/paper-submission.php>