

Enhancing the Esthetic of Metallic Removable Partial Denture Using Axial Attachment: A Case Report

Ahlem Raddaoui, Sana Bekri*, Sameh Rzigui, Amel Labidi, Mohamed Ben Yaala, Hiba Triki, Lamia Mansour

Removable Prosthetics Department, ABCDF Laboratory, Faculty of Dental Medicine, University of Monastir, Tunisia

*Corresponding Author: Sana Bekri, Removable Prosthetics Department, ABCDF Laboratory, Faculty of Dental Medicine, University of Monastir, Tunisia, Tel.: 21756809, E-mail: sanabekri2015@gmail.com

Citation: Ahlem Raddaoui, Sana Bekri, Sameh Rzigui, Amel Labidi, Mohamed Ben Yaala et al. (2024) Enhancing the Esthetic of Metallic Removable Partial Denture Using Axial Attachment: A Case Report, J Dent Oral Care Med 11(2): 201

Received Date: June 21, 2024 Accepted Date: June 21, 2024 Published Date: June 25, 2024

Abstract

Association of a supra-radicular attachment with a removable partial denture on a metal framework is a therapeutic solution that may overcome the biomechanical and aesthetic challenges associated with posterior extensive edentulism. However, the success of the treatment requires rigorous preliminary study, thorough expertise in prosthetic implementation, as well as active patient cooperation.

The objective of this article is to describe, through a clinical case report rehabilitation of a partially edentulous patient with a partial removable denture using a supra-radicular attachment and to illustrate the advantages and disadvantages of this prosthetic device.

Keywords: Supra-radicular attachment; Removable partial denture; Metal framework

Introduction

Rehabilitation of partially edentulous patients is a real challenge for prosthodontists. Removable partial denture (RPD) often represents a preferred therapeutic solution, particularly for financial reasons and as it preserves residual tissues [1].

However, despite its advantages, RPD may also present various issues, both biomechanically and aesthetically. Among these problems is tissue duality, where the difference in compressibility between soft tissues and natural teeth can lead to uncomfortable rocking movements for the patient [2].

Additionally, the visibility of clasps in the anterior region can affect the aesthetic result and cause patient dissatisfaction [3].

This is where the supra-radicular axial attachment comes into play, offering an effective solution in terms of retention and aesthetics. By eliminating the vestibular arm of the cast clasp, the axial attachment helps enhance the aesthetic appearance of the prosthesis while ensuring better retention, thereby improving patient comfort and satisfaction [4].

The objective of this article is to present, through a clinical case, the different steps of an oral rehabilitation with a metal framework prosthesis associated to a supra-radicular axial attachment and to illustrate the advantages and disadvantages of this prosthetic device.

Materials and Methods

Patient S.B, a 43-year-old, female in good general health, was addressed to the removable partial denture department at the Monastir Dental Medicine Clinic for aesthetic and functional prosthetic rehabilitation

In the maxillary arch (figure 1a), remaining teeth were 11-12-13-15-21-22-23-24-25, they were free of caries or dental mobility. The residual ridge was moderately high and wide, covered by adherent fibro-mucosa. The palate was wide and moderately deep. The right and left tuberosities were present, well-formed, and covered with adherent fibro-mucosa.

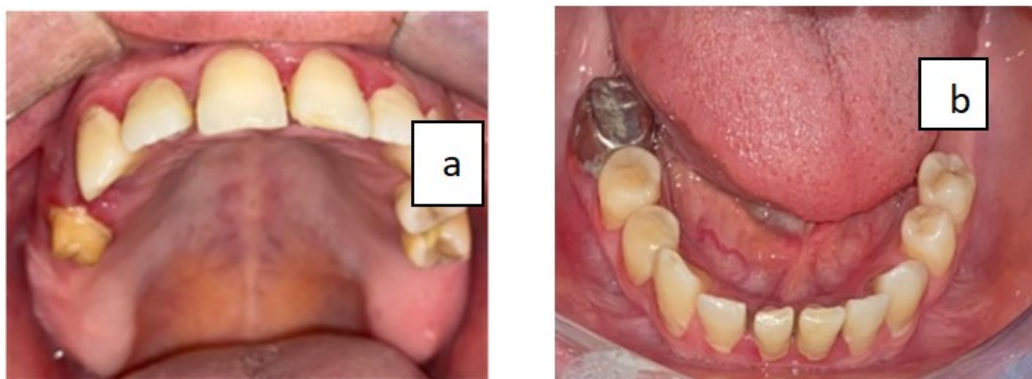


Figure 1: The initial state of the maxillary and mandibular arches, a: the maxillary arch, b: the mandibular arch

In the mandibular arch (figure 1b), the missing teeth were 48-36-37-38. Tooth 46 had a metallic crown with a defective denture--tooth junction, insufficient endodontic treatment, and a periapical lesion. The ridge was moderately high and wide, covered with adherent fibro-mucosa.

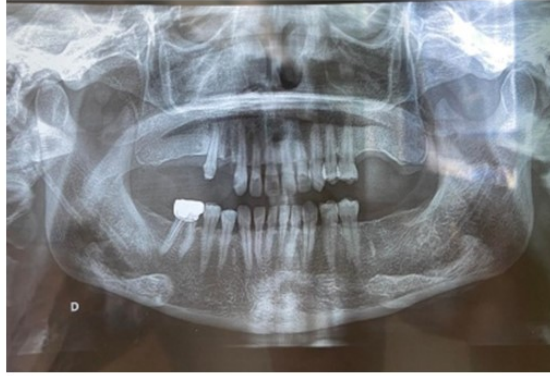

Figure 2: The Panoramic Radiograph

The panoramic radiograph (Figure 2) showed a crown-to-root ratio (CR/RR) of <1 for all maxillary and mandibular teeth.

Mounting of the preliminary casts on the articulator during the study phase revealed sufficient available prosthetic space (figure 3).



Figure 3: Examination of the casts on the articulator reveals sufficient available prosthetic space.

The prosthetic decision was to fabricate, in the maxillary arch (figure 4), a metal framework with a radicular post equipped with an axial attachment at tooth 15, and a metal framework RPD replacing the missing teeth. In the mandibular arch (figure 5), a metal framework RPD was planned with an evolving design considering the poor prognosis of tooth 46.

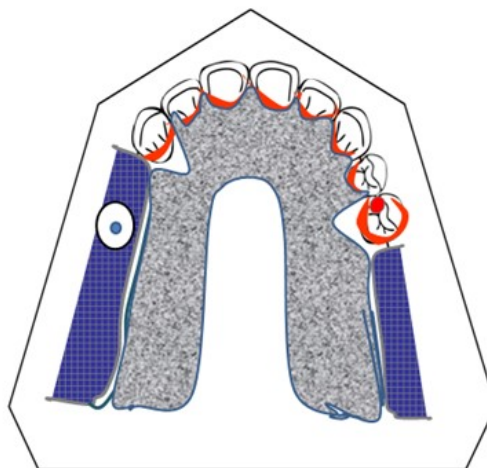


Figure 4: The maxillary framework layout

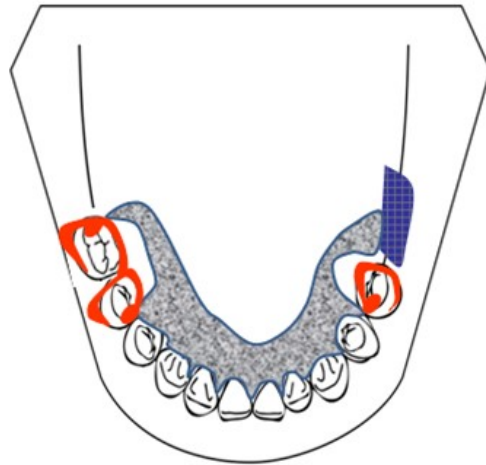


Figure 5: The mandibular framework layout

After performing pre-prosthetic treatments, including scaling, as well as endodontic treatment on tooth 15, the prosthetic fabrication process begins with enameloplasty to prepare the teeth for receiving the future prosthesis and facilitating its insertion.

These enameloplasties were carried out according to the previously established framework scheme. The crown of tooth 15 was sectioned 2 mm from the gingival level. Then, the preparation of the post space was performed on the two-thirds of the root height, ensuring a minimum of 3 to 5 millimeters of apical seal. The cervical limit of the preparation was a juxta-gingival peripheral bevel. The vestibular wall was oblique, while the palatal wall was horizontal. The vestibular wall featured a notch to prevent rotation of the coping (Figure 6).

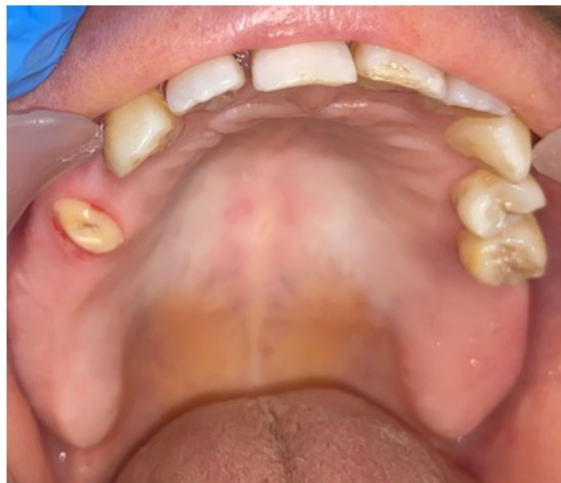

Figure 6: Richmond preparation of tooth 15

A global impression with the post in place was taken, as well as a terminal mandibular anatomical impression. The sculpting of parabolic copings and the positioning of the patrice of the attachment were carried out using a dental surveyor (Figure 7).

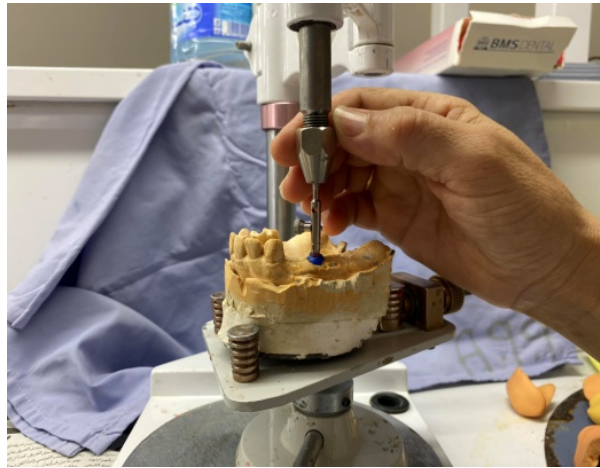

Figure 7: Placement of the patrice according to the insertion axis of the prosthesis

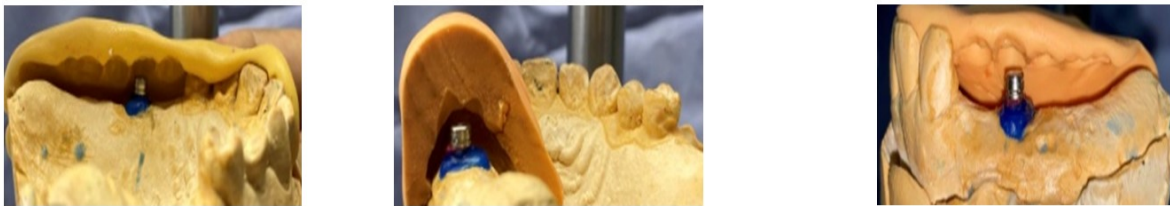

Figure 8: Use of silicone keys to check the feasibility of placing the axial attachment

After casting, the radicular post coping equipped with the axial attachment was tried in the mouth (Figure 8), and a pick-up dynamic impression was made using an individual impression tray and low-viscosity silicone (Figure 9a). Additionally, a terminal anatomical impression was made using a commercial impression tray and Class A alginate (Figure 9b) to obtain working models on which the metal framework sculptures were created (Figure 10).

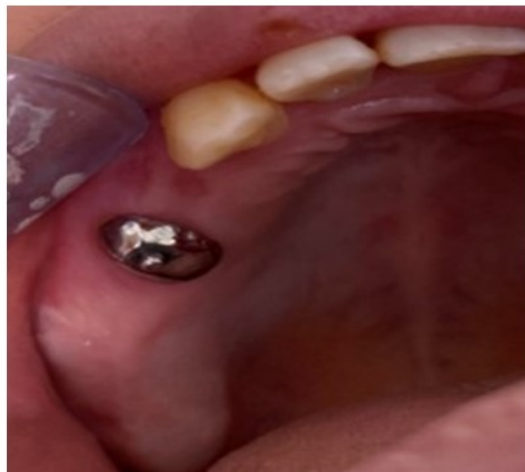

Figure 9: Fitting of the sub-root coping

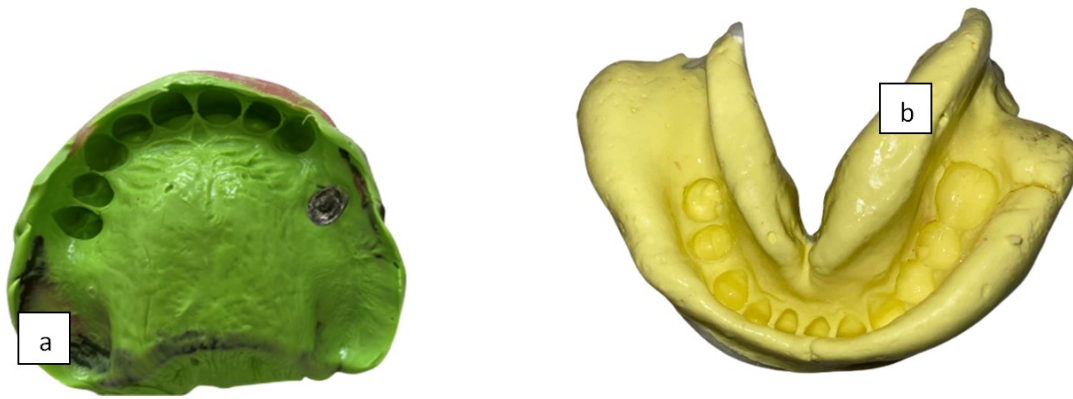

Figure 10: Upper and lower impressions, a: Maxillary dynamic pick up impression, b: Mandibular terminal anatomical impression

Wax-up of the cast framework was completed on the master cast (Figure 10), and the entire cast partial framework was cast in Co-Cr alloy (Figure 11).

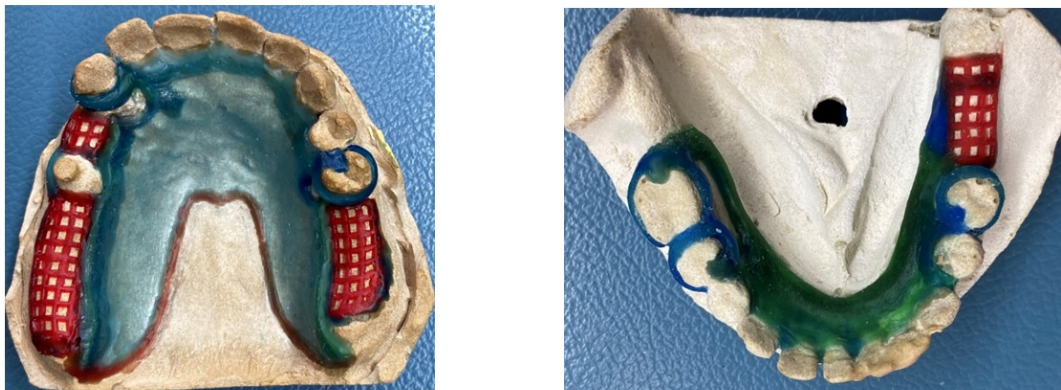


Figure 11: The wax model of the maxillary and mandibular framework

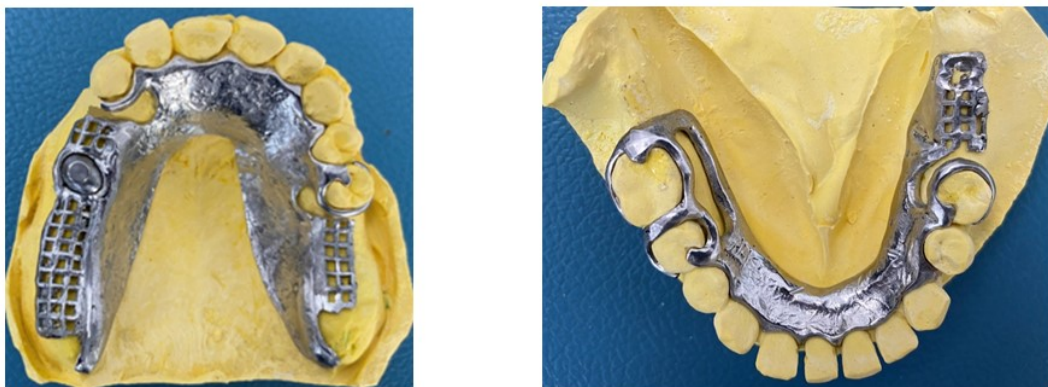


Figure 12: Maxillary and mandibular frameworks

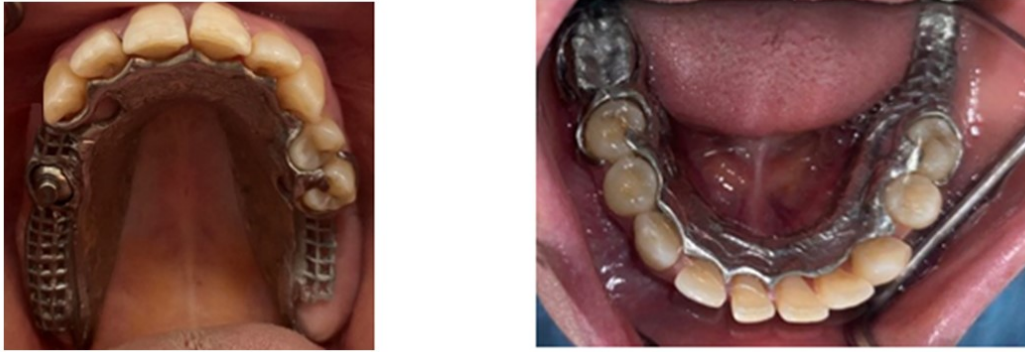

Figure 13: Fitting of the maxillary and mandibular frameworks in the mouth

After trying the metallic frameworks in mouth, (Figure 12) occlusal relation was recorded in centric relation at the correct occlusal vertical dimension and mounted on semi-adjustable articulator. (Figure 13) Teeth arrangement was done (Figure 14) and wax try also. Occlusion and esthetics were verified in patient's mouth. Cast partial denture was fabricated in heat cure denture base resin. (Figure 15)

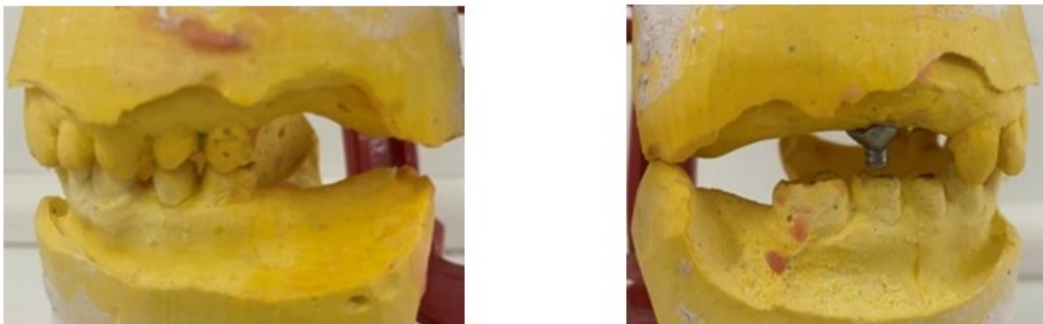

Figure 14: Recording of occlusion in correct CR (centric relation) and proper vertical dimension of occlusion (OVD)




Figure 15: Wax setup of the teeth

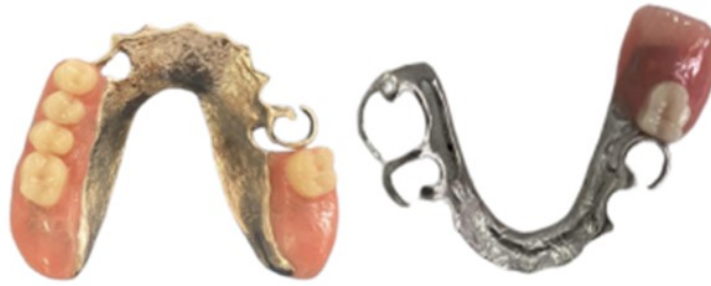

Figure 16: Polymerized maxillary and mandibular prosthesis

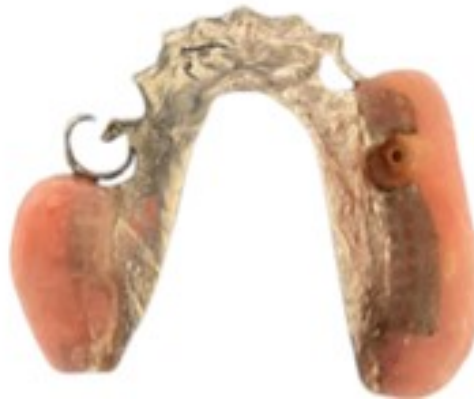

Figure 17: Female part of the axial attachment on the internal surface of the prosthesis

After polymerization, the coping with the axial attachment was sealed, and occlusal equilibration was performed. Subsequently, a spacing device in the form of a rubber dam sheet was placed, and the matrice part was integrated on the internal surface of the prosthesis (Figure 16) using self-polymerizing resin under occlusal pressure. This is a critical step because an incorrect positioning can result in a wrong fitting of the removable partial denture.

Results

The patient expressed immediate aesthetic satisfaction during the insertion session (Figure 17). A 48-hour follow-up was scheduled, during which a slight overextension of the anterior border of the maxillary prosthesis was adjusted.

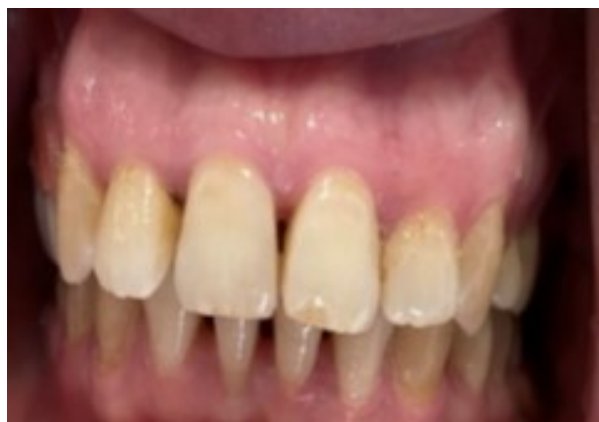

Figure 17: Final result

A monthly maintenance appointment schedule was planned to ensure any necessary occlusal or prosthetic adjustments.

Discussion

The integration of a supra-radicular axial attachment into a metal framework removable partial denture (RPD) is a precise and rigorous procedure that requires thorough and meticulous pre-analysis. Indeed, mounting study models on an articulator allows the setting of a diagnostic wax-up, which shows the prosthetic project, assesses the available prosthetic space for the placement of an axial attachment, presents its volume. Additionally, the diagnostic wax-up serves as an effective communication tool with the patient in terms of treatment explanation [5, 6].

One of the common challenges in fabricating a metal framework removable partial denture (RPD) with the integration of an axial attachment is the lack of occlusal and proximal prosthetic space, resulting in very thin denture resin that is less resistant to chewing forces. In this regard, the use of veneered teeth offers an effective solution for managing the available prosthetic space while ensuring adequate mechanical strength.

Veneered teeth help optimize the available space, thereby ensuring a balanced distribution of chewing forces and providing improved durability to the prosthesis [7].

However, the exploitation of residual roots is possible, provided that several criteria are met. These criteria include adequate intra-osseous root height. Additionally, it is essential that the residual roots exhibit no mobility or root caries, ensuring their stability and health. Another condition to consider is the presence of sufficient attached gingiva, which helps maintain the residual roots in place. Finally, it is important that the root axis is favorable for the preparation and reception of a retention system [2, 8].

In our case, the use of the axial attachment on tooth 15 has allowed, from a biological standpoint, to preserve the alveolar bone as well as the periodontal proprioception. From an aesthetic perspective, this has prevented the dissolution of the false gingiva and the removal of the vestibular arm of the anterior clasps. From a mechanical point of view, the integration of an attachment on tooth 15 has optimized the prosthetic balance in extensive edentulism [4, 9, 10].

In Kennedy-Applegate Class I, as it's presented in this case, parasitic movements are mainly characterized by vertical rotation around the axis passing through teeth bordering the edentulism. These movements, generated during various masticatory functions, lead to sinking of the prosthesis at the support structures. By using axial attachments, it was possible to reduce these movements.

However, this approach is not without challenges. Indeed, despite its advantages, the use of these systems presents implementation difficulties and requires regular follow ups to control the retention system [12].

It relies heavily on close cooperation from the patient, involving adherence to regular check-up sessions as well as following recommended prosthetic hygiene and maintenance rules [10].

Conclusion

The integration of the supra-radicular axial attachment into the metal framework of a removable partial denture represents a good therapeutic solution to overcome the biomechanical and aesthetic challenges posed by extensive edentulism. However, treatment success requires thorough preliminary study, a correct indication, and patient cooperation.

References

1. Karoubi A, Bueche S (2009) Canine maxillaire et prothèse amovible partielle. AOS, 245: 27-35
2. Bouraoui S, Mansour L, Trabelsi M, Chater N (2015) Exploitation of natural and artificial roots in removable prosthesis: clinical cases. AJDI, [S.l.], n, 5: 23-35.
3. Benyahia H, Fajri L, Rohkssi H, Merzouk N, Berrada S (2016) La prothèse composite dans la gestion esthétique et biomécanique d'un édentement unilatéral de grande étendue. Stratégie prothétique mai.juin, 16: 177-84.
4. Fajri L, Hamzaoui S, Berzouk N, Elmohtarim B (2021) Removable partial prosthesis from analysis to realization. AJDI, [S.l.], n. 19.
5. Leila Fajri, Saloua Hamzaoui, Nadia Berzouk, Bouabid Elmohtarim (2021) La réhabilitatin par prothèse amovible partielle: de l'analyse à la réalisation African Journal of Dentistry & Implantology, [S.l.], n. 19.
6. Schittly E (2001) Attachements et prothèses partielles amovibles métalliques. Encycl Méd.Chir, 23: 310-10.
7. Triki H, Bekri S, Sadouri I, Taktak N, Mansour L (2018) Domaines d'utilisation des contre plaques. AOS, 289: 2.
8. Abdelkoui A, Rokhssi H, Benfdil F, Merzouk N (2021) Maîtriser les facteurs d'échec en prothèse amovible complète supra.radiculaire. Strat Proth, 2021: 58-65.
9. Bagui M, Fajri L, Benfdil F, El Mohtarem B, Merzouk N (2016) La prothèse amovible partielle supra radicaire avec attachement axial: aspects théoriques et pratiques. Stratégie prothétique mai.juin, 16: 215-23.
10. Sabir S, Slaoui J, Merzouk N, Bentahar O (2020) L'intégration d'un attachement axial à une prothèse adjointe partielle métallique : Intérêts thérapeutiques. IAJD, 11: 24-32.
11. Fajri L, Benfdil F, El Mohtarim B, Abdedine A (2007) Attachement axial en prothèse amovible partielle: Réalisation clinique temps par temps. Les cahiers de prothèse, 139: 43-9.
12. Bekri S, Triki H, Bibi R (2016) La gestion esthétique et biomécanique d'un cas d'édentement de classe II de Kennedy. Int Arab J Dent, 7: 130-5.

Submit your next manuscript to Annex Publishers and benefit from:

- ▶ Easy online submission process
- ▶ Rapid peer review process
- ▶ Online article availability soon after acceptance for Publication
- ▶ Open access: articles available free online
- ▶ More accessibility of the articles to the readers/researchers within the field
- ▶ Better discount on subsequent article submission

Submit your manuscript at

<http://www.annexpublishers.com/paper-submission.php>