

Management of Needle Breakage Following Inferior Alveolar Nerve Block: Case Report

Ferrari S, Zito F*, Lanfranco D, Varazzani A. and Ferri A.

Maxillo-Facial Surgery Head and Neck Department, University of Parma, Italy

*Corresponding author: Zito F, Maxillo-Facial Surgery Head and Neck Department, University of Parma, Via Silvio Pellico, 10 Parma, Italy, Tel: +393409344374, E-mail: frazito90@gmail.com

Citation: Ferrari S, Zito F, Lanfranco D, Varazzani A., Ferri A. (2019) Management of Needle Breakage Following Inferior Alveolar Nerve Block: Case Report. J Dent Oral Care Med 5(1): 102

Received Date: February 15, 2019 **Accepted Date:** September 03, 2019 **Published Date:** September 05, 2019

Abstract

A needle breakage is a rare complication of an inferior alveolar nerve block, but it should represent an awkward experience both for the patient and the dentist. A broken needle in the pterygo mandibular region would be hard to remove and it may also have important medico-legal considerations. This is the case report of a 32-years old man, referred by his own dentist to the Maxillo-Facial department, after the needle broke during the routine administration of an inferior alveolar nerve block for a dental procedure. In this paper, authors present the successful removal of the fractured needle from the right pterygomandibular region under general anesthesia administration.

Keywords: Local Anesthesia; Complications; Oral Surgery; Needle Breakage

Introduction

The inferior alveolar nerve block is the most common type of anesthesia used for a dental procedure on the mandibular molar region. This technique has been used for a long time and is still the approach mostly used by dentistry and maxillo-facial surgeons, thanks to his advantages like obtaining the maximum anesthetic effect using a small dose of local anesthetic, usually without serious side effects. Augello, *et al.* reviewed the literature of 50 years before 2011 about needle breakage during local anesthesia in the oral cavity and reported that 70% of broken needles occurs in the pterygomandibular space [1,2].

The incidence of needle breakage could be barely estimated due to the elevate number of inferior alveolar nerve block executed by all dentists each day, as explicated from Pogrel who analysed 16 cases of needle breakage during a 25-year period in one academic institution. He estimates that, in northern California, one needle fracture occurs per 14 million inferior alveolar nerve blocks [3].

Nowadays, the incidence has significantly decreased due to the use of disposable needles made of modern and flexible alloys, but some cases are still reported [4].

Some dentists' habits could increase the possibility of needle breaking, like the reuse of the needle after bending the tip. Also, the sudden movement of the patient in the opposite direction of the needle could be responsible, more commonly in the pediatric patients [5].

The clinical presentation could be various. Mostly, the patient refers to the hospital complaining loco regional pain and trismus; dysphagia, hematoma or paresthesias are less common. On the other hand, the patient could refer to the doctor completely symptomless [6].

The psychological status of the patient has to be considered: he is upset for the unconventional situation and uncomfortable because of the knowledge of the foreign body inside his mouth; because of that his compliance to the attempts of retrieval in local anesthesia could be very low.

Although limited cases are reported, the migration of the needle inside the soft tissue of the neck towards vital structures, like vessels and nerves, can occur [7]. Therefore, the needle could migrate into deeper tissue spaces, like the lateral pharyngeal space, where the styloglossus muscle, the ascending pharyngeal artery and the external carotid artery all lie [8-10].

The aim of this study is to show the management of such unpredictable side effect, stressing the importance of the imaging to have a correct idea of the surgical approach needed. In fact, as no standardized protocol exists about the technique that has to be used and the imaging that can better guide surgical steps, the surgeon has to choose between different possibilities. It's essential

to identify the three-dimensional position of the fragment in the soft tissue and, moreover, to have an intra-operative instrument that can guide the surgeon in the retrieval. In fact, the fragment could move in the three dimensions of the space, as a consequence of the attempts to get closer. The technique chosen in this case was a first evaluation with a computed tomography scan (CT-scan) and 3D-reconstruction which defined the correct position better than a 2-dimensional Orthopantomography (Rx OPT).

Case Report

A 32-years old male patient was referred to the Emergency Room from his own dentist for a 21 mm 30 Gauge broken needle in the pterygo-mandibular right space. It occurred while his dentist was administering a loco regional anesthesia for a root canal obturation. Although the dentist immediately attempted to retrieve the fractured needle, his attempt failed; so the patient attended the hospital to evaluate the accident and secondly was sent to the Maxillo-facial Department for specialist evaluation. When the patient arrived to our attention, he complained pain during mouth opening but there wasn't limitation in his ability to open the mouth. So, a CT scan with 3D reconstruction was acquired, revealing that the fractured needle lied behind the 4.8 element, medial to the right ascending mandibular ramus and the lingual nerve, inside the internal pterygoid muscle and the lateral pharyngeal adipose tissue (Figure 1, 2 and 3).

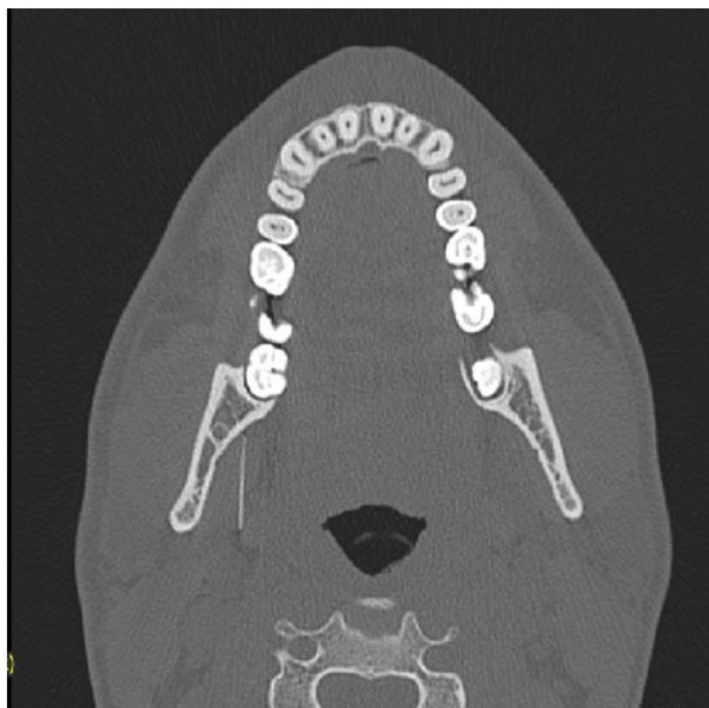


Figure 1: Axial CT-SCAN: the broken needle lies in the right pterygo-mandibular space

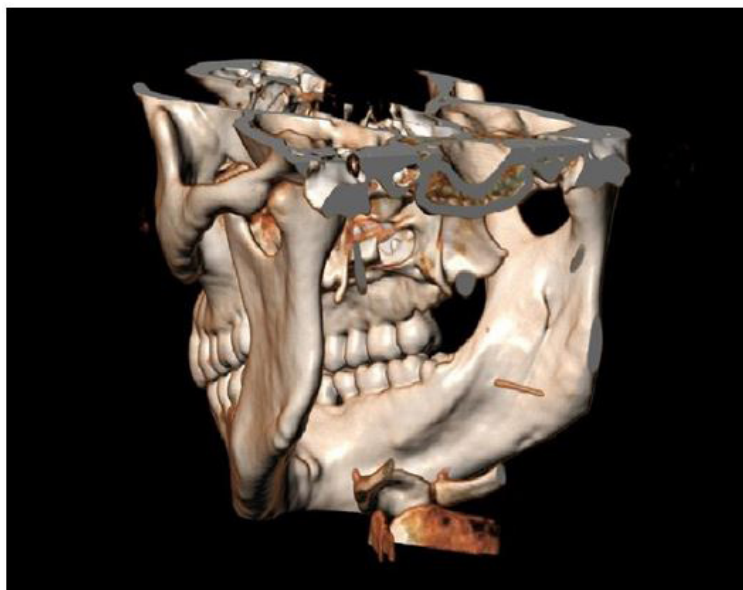

Figure 2: CT-SCAN 3D reconstructions, showing the position of the fragment in the right pterygo-mandibular space

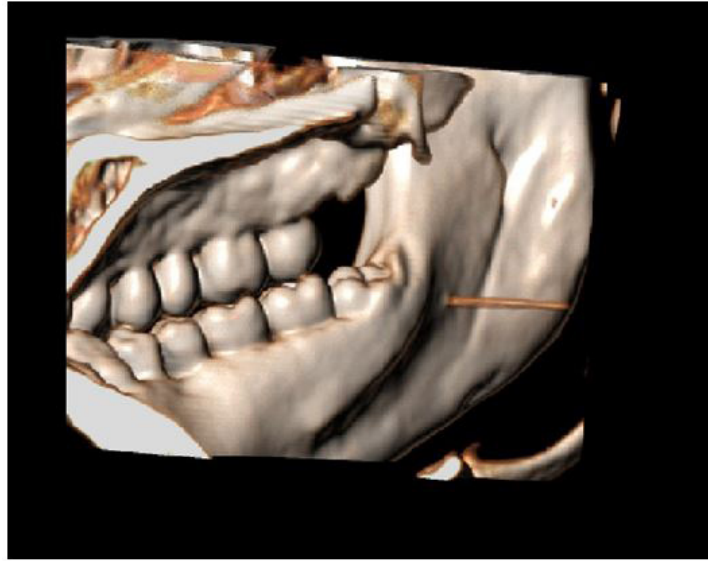


Figure 3: CT-SCAN 3D reconstructions, showing the position of the fragment in the right pterygo-mandibular space

Firstly, we had an attempt with loco-regional anesthesia that was unsuccessful; a vertical incision parallel to the anterior ramus of the mandibula was made but the fragment was not visible neither palpable with this kind of approach. Besides, the patient was not compliant after few minutes and started to complain pain and inability to maintain the mouth opened. We decided to proceed with surgery under general anesthesia, helped by intra-operative brilliance amplifier. The brilliance amplifier consists in an imaging device that can be used in the operating room, while the patient is under general anesthesia on the operating table, in order to obtain instantaneous X-Ray images of the anatomical area of interest. Before the surgical procedure, we have prescribed antibiotic and corticosteroid therapy, once the patient presented edema and pain after the local-anesthesia first approach: Amoxicillin Clavulanate 2.2 gr and Dexamethasone 8 mg by intravenous infusion were promptly administered. The patient underwent general anesthesia via nasotracheal intubation in the operating room of the Maxillo-Facial Department.

A mouth prop was used to fix the mouth in an open position, while an iron mouth gag would interfere with the brilliance images. Then, through the same access attempted with local anesthesia, a superficial blunt dissection of the pterygomandibular space was made, in order to minimize risk of damage to the mandibular division of the trigeminal nerve and associated blood vessels. We also needed to isolate the lingual nerve and to protect it with a malleable retractor because it laid very close to the position of the fragment. During surgery, the magnification with 3.5x surgical binocular loupes was essential to recognize the main structures of the pterygo-mandibular region and to proceed with the retrieval of the broken needle.

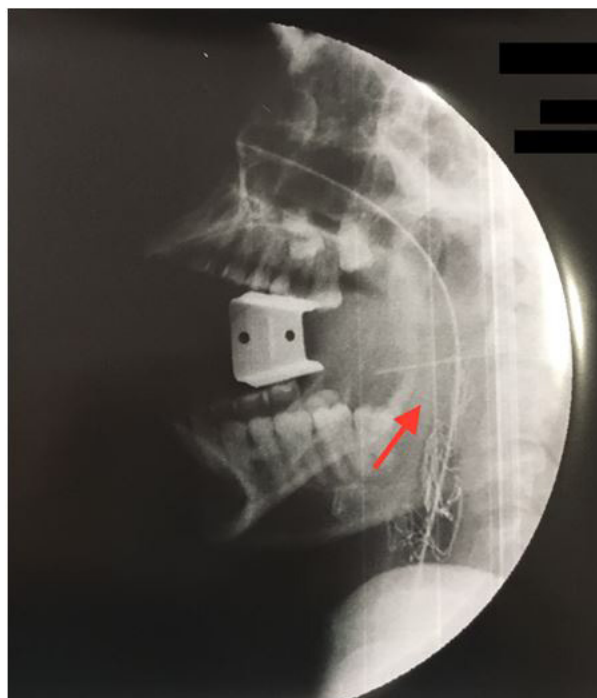


Figure 4: Intra-operative brilliance amplifier, sagittal view

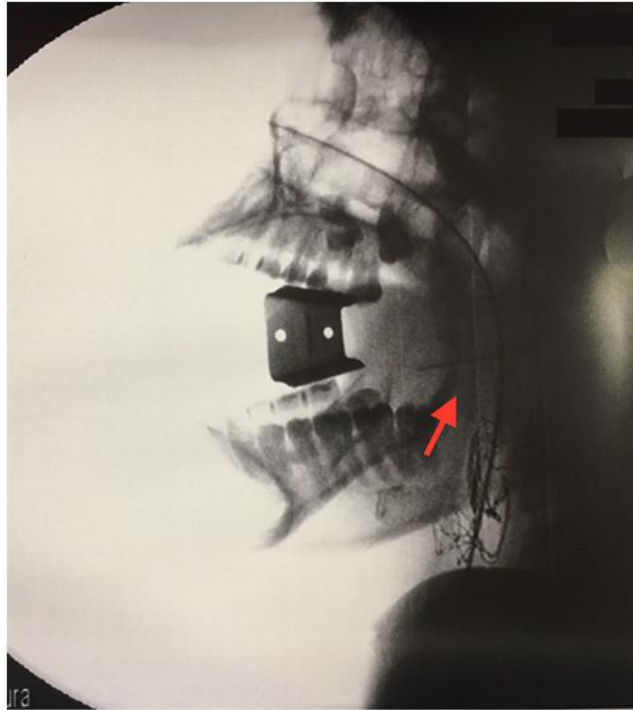


Figure 5: Intra-operative brilliance amplifier, sagittal view



Figure 6: The removed broken needle

The actual position of the needle was studied by intra-operative brilliance amplifier; the head of the patient was fixed, in order to have less bias on the X-Rays images (Figure 4 and 5). Sequential images were taken while we proceeded dissecting the pterigomandibular area, using a needle of 21-Gauge as a point of reference, as we want to know how the position of the fragment was changing due to our movements and how much we managed to get closer. The thickness and the length of the 21-Gauge needle provided a term of comparison and a practical static guide in the X-ray images, while the fragment of 30-Gauge was barely visible. We managed to retrieve it and remove the broken needle with a klemmer forceps. This fragment was approximately 20 mm long and bent (Figure 6). No other structures were injured during the procedure such as lingual nerve or major vessels. Total surgery time was about 1.5 hours.

The post-operative was regular and without complications; cold therapy helped to relief edema and pain. Post-surgery, the patient received antibiotic therapy with Amoxicillin Clavulanate 2.2 gr 3 times per day since he was in the hospital, paracetamol 1 gr and ketoprofen 100 mg intravenous infusion in order to manage post-operative pain. The patient was discharged from the hospital two days later, suggesting him to continue the antibiotic therapy with tablets for other two days. Once a week for one month, he was checked in our department. He didn't refer pain in the affected area after a week from surgery and the edema was significantly decreased. He referred trismus and hypoesthesia of the tongue from the side affected for 15 days after surgery, probably due to the temporary damage of the lingual nerve. Then, these symptoms completely disappeared and after one month from surgery the patient was completely recovered, without infections of the surgical wound or any other side effect.

Discussion

In the past years, needle breakage was a common side effect of a loco-regional anesthesia, as evidenced by Blum's report of 100 cases in 1928 and Fraiser-Modie's review of 26 cases in 1958 [11,12]. This was due to not disposable needles made by old alloys sterilized more times. Nowadays, it's mandatory to take some precautions in order to avoid this annoying kind of side effect.

Firstly, there is no evidence that the pain is associated with the diameter of the needle. The possibility of breakage rises when a 30 Gauge needle is used [13,14]. Unfortunately, a high percentage (76%) of dentists uses this kind of thin needles as shown by Augello *et al.* [2]. The stronger pressure of injection and the increased deflection of the needle with a 30-Gauge needle could be even more painful and could increase the likelihood of breakage. It's suggested to use at least a 27-gauge needle for an inferior alveolar nerve block [13,15].

Secondly, the practitioner should avoid to re-use the needle after bending or to bury the needle up to the hub-needle junction that is the weakest part of the needle [3].

When the breakage occurs, it's important to inform the patient and try to retrieve it immediately, if the tip is visible. On the other hand, if the fragment is not visualized in a short period of time, the patient has to be referred to a tertiary care centre as soon as possible. Although there are some reviews about the possibility of leaving small needles inside the soft tissue, as the consequent fibrosis around them should made them harmless, a quick removal of the foreign body is the best approach: firstly because of the possibility of migration towards vital structures or paravertebral space [6,8-10,16]. Secondly, because of the psychological discomfort lived by the patient [17].

The surgeon could be helped in his work with different kind of images. The cheaper, safer and faster imaging that we can take is an Rx OPT, linked to a lateral and posterior-anterior skull view [18]. Unfortunately, this imaging has the disadvantage of a static 2D-visualization. CT-scan and 3D reconstruction are surely better as a pre-operative study of the patient. When the patient undergoes surgery in general anesthesia, a real-time imaging is required. The electromagnet approach is nowadays out of order because the new needles used are no paramagnetic anymore [6].

Even the intra-oral ultrasonography is dismissed, as the oral cavity offers a limited space to reach a useful imaging. In literature, there are reports about the use of fluoroscopy guidance, peri-operative cone beam CT or exploration of the pterygo-mandibular space using a microscope [18-20]. Recently, Gerbino, *et al.* reported the use of intraoperative navigation as guidance for the actual localization of the broken needle [21].

Our personal experience with intra-operative brilliance amplifier has been quite satisfying, in addition to the magnification obtained by ocular loupes. Nowadays, if a surgical miscount occurs, the brilliance amplifier is a common tool used to check the patient body after or during surgery for the retrieval of the missing foreign body [22]. We found in literature that a 17 mm needle is the smallest size surgical needle seen by X-rays, so we decided to adopt this useful imaging technique for the needle fragment retrieval, helped by the guidance of the static 21-Gauge needle. We managed to control the movements of the broken needle using the 21-Gauge needle as a point of reference, even though while we got closer, the fragment deepens in the soft tissues [23].

Conclusion

Needle breakage is a rare but possible complication to be aware of. Prompt removal of a broken needle represents the gold standard of treatment. Despite the perfect knowledge of the pterygomandibular region anatomy is required in this kind of surgery, it could not be enough. Imaging provides a primary guidance through the pre-operative and intra-operative study of the case. The maxillo-facial specialist has to consider both these two aspects as guide-lines of this uncommon and quite hard type of surgery.

References

1. Khalil H (2014) A basic review on the inferior alveolar nerve block techniques. *Anesth Essays Res* 8: 3-8.
2. Augello M, von Jackowski J, Grätz KW, Jacobsen C (2011) Needle breakage during local anesthesia in the oral cavity - a retrospective of the last 50 years with guidelines for treatment and prevention. *Clin Oral Investig* 15: 3-8.
3. Pogrel MA (2009) Anthony Broken Local Anesthetic Needles: A Case Series of 16 Patients, With Recommendations, *J Am Dent Assoc* 140: 1517-22.
4. Ethunandan M, Tran AL, Anand R, Bowden J, Seal MT, et al. (2007) Needle breakage following inferior alveolar nerve block: implications and management. *Br Dent J* 202: 395-7.

5. You JS, Kim SG, Oh JS, Choi HI, Jih MK (2017) Removal of a fractured needle during inferior alveolar nerve block: two case reports J Dent Anesth Pain Med 17: 225-9.
6. Moore UJ, Fanibunda K, Gross MJ (1993) The use of a metal detector for localisation of a metallic foreign body in the floor of the mouth. Br J Oral Maxillofac Surg 31: 191-2.
7. Rahman N, Clarke M, Stassen LFA (2013) Case report: management of broken dental needles in practice. J Irish Dent Assoc 59: 241-5.
8. McDonogh T (1996) An unusual case of trismus and dysphagia. Br Dent J 180: 465-6.
9. Faura-Solé M, Sanchez-Garcés MA, Berini-Ayres L, Gay-Escoda C (1999) Broken anaesthetic injection needles: Report of 5 cases. Quintessence Int 30: 461-5.
10. Moore K, Khan NR, Michael LM, Arthur AS, Hoit D (2017) Endovascular retrieval of dental needle retained in the internal carotid artery. J Neurointerv Surg 9: e26.
11. Blum T (1928) A report of 100 cases of hypodermic needles broken during the administration of oral local anaesthesia. Dent Cosmos 70: 865-74.
12. Fraser-Moodie W (1958) Recover of broken needles. Br Dent J 105: 79-85.
13. Bedrock RD, Skigen A, Dolwick MF (1999) Retrieval of a broken needle in the pterygomandibular space. J Am Dent Assoc 130: 685-7.
14. Cameron M, Phillips B (2006) Facial infection secondary to occult foreign body. Int J Oral Maxillofac Surg 35: 373-5.
15. Aldons JA (1968) Needle deflection: a factor in the administration of local anaesthetics. J Am Dent Assoc 77: 602-4.
16. Sahin B, Yildirimturk S, Sirin Y, Basaran B (2017) Displacement of a broken dental injection needle into the perivertebral space. J Craniofac Surg 28: 474-7.
17. Marks RB, Carlton DM, McDonald S (1984) Management of a broken needle in the pterygomandibular space: report of case. J Am Dent Assoc 109: 263-4.
18. Lee J, Park MW, Kim MK, Kim SM, Seo KS (2015) The Surgical Retrieval of a Broken Dental Needle: A Case Report, J Dental Anesth Pain Med 15: 97-100.
19. RifKind JB (2011) Management of a Broken Needle in the Pterygomandibular Space Following a Vazirani-Akinosi Block: Case Report. J Can Dent Assoc 77: b64.
20. Kim JH, Moon SY (2013) Removal of a broken needle using three-dimensional computed tomography: a case report. J Korean Assoc Oral Maxillofac Surg 39: 251-3.
21. Gerbino G, Zavattero E, Berrone M, Berrone S (2013) Management of needle breakage using intraoperative navigation following inferior alveolar nerve block. J Oral Maxillofac Surg 71: 1819-24.
22. Walter WR, Amis ES Jr, Sprayregen S, Haramati LB (2015) Intraoperative Radiography for Evaluation of Surgical Miscounts. J Am Coll of Radiol 12: 824-9.
23. Macilquham MD, Riley RG, Grossberg P (2003) Identifying lost surgical needles using radiographic techniques. AORN J 78: 73-8.

Submit your next manuscript to Annex Publishers and benefit from:

- ▶ Easy online submission process
- ▶ Rapid peer review process
- ▶ Online article availability soon after acceptance for Publication
- ▶ Open access: articles available free online
- ▶ More accessibility of the articles to the readers/researchers within the field
- ▶ Better discount on subsequent article submission

Submit your manuscript at

<http://www.annepublishers.com/paper-submission.php>