

Management of Traumatic Dental Injuries Presenting to the Emergency Department

Djema! S and Patel K*

King's College Dental Institute, Denmark Hill, London, SE5 9RS, United Kingdom

*Corresponding author: Djema! S, King's College Dental Institute, Denmark Hill, London, SE5 9RS, United Kingdom, E-mail: Serpil.djema!@nhs.net

Citation: Djema! S, Patel K (2018) Management of Traumatic Dental Injuries Presenting to the Emergency Department. J Emerg Med Care 1(1): 104

Received Date: July 20, 2018 **Accepted Date:** September 12, 2018 **Published Date:** September 14, 2018

Abstract

Background: Traumatic Dental Injuries (TDI's) commonly present to emergency departments with up to 48% of all patients suffering from facial trauma presenting with associated TDI's. As not all secondary care settings benefit from an affiliated dental hospital or a dedicated Maxillofacial department, it can often be difficult for the ED team to manage TDI's effectively. Emergency dental treatment is dictated by the type of TDI as classified by the World Health Organisation and is categorised into four sub-sections.

Objectives: The authors propose a set of guidelines with the aim of providing staff working in Emergency Departments with information and therefore confidence in managing dental trauma with the right treatment, at the right time and in the right environment.

Guidance Summary: All avulsed teeth should ideally be re-implanted immediately (within 5 minutes) at the scene of the accident. All displacement injuries which pose an airway risk and avulsion injuries where the tooth has not been immediately re-implanted should be treated on an urgent basis. All other fracture and displacement injuries can be treated on a delayed basis (over 60 minutes).

Conclusion: The adherence and dissemination of this guidance will increase ED teams' awareness of TDI's whilst concurrently allowing for a more efficient patient pathway through the ED. Patient outcomes for their dental injury will be improved by providing the correct treatment by the most appropriate clinician, in the most appropriate setting and timeframe.

Keywords: Dental; Trauma; Emergency Department; Traumatic Dental Injury; Guideline

Introduction

Traumatic Dental Injuries (TDI's) and their management have been reported extensively and guidelines have been published on best practice given the evidence [1-3]. TDI's have a high prevalence in the United Kingdom and worldwide, and it has been reported that 12% of 12 year old and 10% of 15 year old have suffered TDI's [4,5]. It is therefore crucial that all members of the dental team, allied healthcare professionals and the general public know what they can do to optimise outcomes and ensure patients get timely management and referrals to the appropriate team.

Teaching of dental trauma to undergraduate dental students is minimal in their 5-year curriculum and non-existent in medical training [6,7]. There is therefore, a lack of awareness of how to manage TDI's amongst doctors in hospital [6-10]. It has been reported that 15-48% of all facial trauma patients seen in an Emergency Department (ED) present with TDI's [11,12]. Some knowledge of the personnel available or the management required as well as the urgency of the situation would help patients get the care that they need.

The literature is plentiful in proposed guidelines to assist in the management of TDI's, but is lacking in any guidance as to who and when to refer these patients [1-3]. Andreasen and colleagues have suggested that not all TDI's need to be managed immediately, or acutely, which they defined as within 3 hours [13]. They proposed that certain TDI's can be treated within 24 hours (sub-acute management), or sometime after 24 hours following the injury (delayed management). This would enable the patient to try and get the best possible treatment, by the most appropriate clinician in the optimal environment. This article will propose a dental trauma patient pathway that can be used to enable healthcare professionals to manage and refer TDI's efficiently and appropriately.

Classification of Traumatic Dental Injuries

There have been many attempts to classify TDI's and these vary from simple to more detailed. Sweet proposed one of the first classification systems in 1955 and a good overview has been summarised by Pagadala and Tadikonda [14,15]. The most widely used classification in the literature to classify TDI's was first proposed by the World Health Organisation (WHO) in 1994, and is largely based on the work by Andreasen. A summary of this classification system can be seen in Table 1, and this classification will be referred to in this guidance [16].

Type of Injury	Description of injury
Injuries to the dental hard tissues and the pulp*	
Enamel infraction	Incomplete fracture (crack) of enamel without loss of tooth substance
Enamel fracture	Loss of tooth substance confined to enamel
Enamel-dentine fracture	Loss of tooth substance confined to enamel and dentine, not involving the pulp
Complicated crown fracture	Fracture of the enamel and dentine exposing the pulp
Uncomplicated crown-root fracture	Fracture of the enamel, dentine, and cementum but not involving the pulp
Complicated crown-root fracture	Fracture of enamel, dentine, and cementum exposing the pulp
Root fracture	Fracture involving dentine, cementum, and pulp Can be sub-classified to apical, middle, and coronal (gingival) thirds
Injuries to the periodontal tissues**	
Concussion	No abnormal loosening or displacement but marked reaction to percussion
Subluxation (loosening)	Abnormal loosening but no displacement
Extrusive luxation (partial avulsion)	Partial displacement of tooth from socket
Lateral luxation	Displacement other than axially with comminution or fracture of alveolar socket
Intrusive luxation	Displacement into alveolar bone with comminution or fracture of alveolar socket
Avulsion	Complete displacement of tooth from socket
Injuries to supporting bone	
Comminution of mandibular or maxillary alveolar socket wall	Crushing and compression of alveolar socket found in intrusive and lateral luxation injuries
Fracture of the mandibular or maxillary alveolar socket wall	Fracture confined to the labial or lingual/palatal socket wall.
Fracture of the mandibular or maxillary alveolar process	Fracture of the alveolar process which may or may not involve the tooth sockets
Fracture of the mandible or maxilla	May or may not involve the alveolar socket
Injuries to the gingiva or oral mucosa***	
Laceration of the gingiva or oral mucosa	Wound in the mucosa resulting from a tear
Contusion of gingiva or oral mucosa	Bruise not accompanied by a break in the mucosa; Usually causes submucosal haemorrhage
Abrasion of gingiva or oral mucosa	Superficial wound produced by rubbing or scraping the mucosal surface

Table 1: A table to summarise the classification of traumatic dental injuries as per the World Health Organisation (16)

Glossary:

Pulp = the nerve and blood vessels in the middle of the tooth

Periodontal tissues = thin membrane surrounding the root of the tooth

Gingival = gum

Oral mucosa = moveable soft tissues inside the mouth including the lips

Scope of this guidance

This guidance aims to provide healthcare professionals, both in primary and secondary care settings, advice on who and when to refer patients presenting with TDI's as well as to raise awareness of what members of the public can do to help themselves immediately following a TDI. There are four subsections to the WHO classification of TDI's [16]. This guidance will account for injuries confined to the teeth only and will include displacement injuries (teeth knocked out of position) and tooth fractures (broken teeth). The intention is that the application of this guidance will improve confidence in the management of patients who sustain a traumatic dental injury.

When should TDI's be treated?

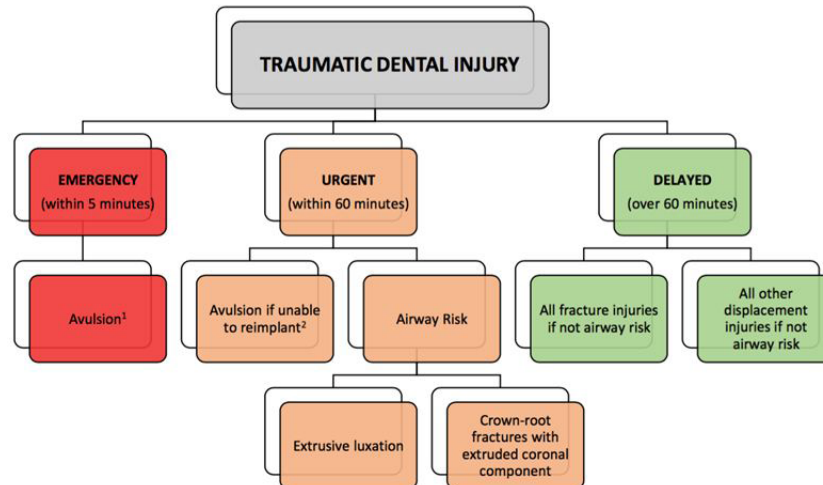
The management of TDI's can be categorised into three pathways depending on the time-frame following dental trauma:

1. **Emergency:** when injuries should be managed ideally **within 5 minutes**
2. **Urgent:** when injuries should be managed ideally **within 60 minutes**
3. **Delayed:** when injuries ideally can **wait more than 60 minutes**

The authors propose that *all* displacements and fractures of teeth can be managed on a **delayed** basis **except** in the following cases:

1. Avulsions (when a tooth is knocked clean out of the mouth). These should be managed as an **emergency**: ideally **within 5 minutes**
2. Avulsions if not re-implanted immediately should be managed **urgently**: ideally **within 60 minutes**
3. Any displacement injury that poses an airway risk (extrusive luxations and root fractures with an extruded coronal fragment) should be managed on an **urgent basis**: ideally **within 60 minutes**.

Figure 1 provides a diagram to illustrate this.



1. First responders, including both healthcare and non-healthcare professionals, should aim to re-implant the avulsed permanent tooth within 5 minutes of the dental trauma occurring.

2. If unable to re-implant the avulsed permanent tooth immediately, a healthcare professional should aim to do so within 60 minutes of avulsion. In the interim, the tooth should be stored in milk and only handled by the crown

Figure 1: A flow diagram to illustrate patient pathways following traumatic dental injuries

Contraindications to re-implanting avulsed teeth

The only true emergency in dental trauma is an avulsion (when a tooth is knocked clean out of the mouth). Although members of the public and healthcare professionals should aim to re-implant all avulsed teeth regardless of the maturity of the root. There are however some important exceptions:

Unconscious patients, those with head injuries or cervical spine injuries: If the patient requires further investigations for severe head trauma (e.g. head CT), this understandably takes priority and avulsed teeth are not considered a priority. In these cases, a chest x-ray is mandatory to rule out inhalation of the avulsed tooth/teeth or tooth fragments.

Medical emergency: A medical emergency should also take priority over re-implanting avulsed teeth.

Primary/deciduous/baby teeth: Adult front teeth erupt around 6 years of age. If dental trauma occurs in an individual below this age, it is likely to be a baby tooth and should not be re-implanted as it may damage the adult tooth developing beneath it. If in doubt, place the tooth in milk and direct the patient to a dental professional.

Poor oral health: In a patient with poor oral hygiene, severe gum (periodontal) disease and multiple decayed (carious) teeth, avulsed teeth should not be re-implanted. Figure 2 illustrates such a neglected dentition. If in doubt, the tooth should be placed in milk and the patient directed to a dental professional. Other storage mediums such as Hank's Balanced Salt Solution and Hartmann's can be ideal storage media.

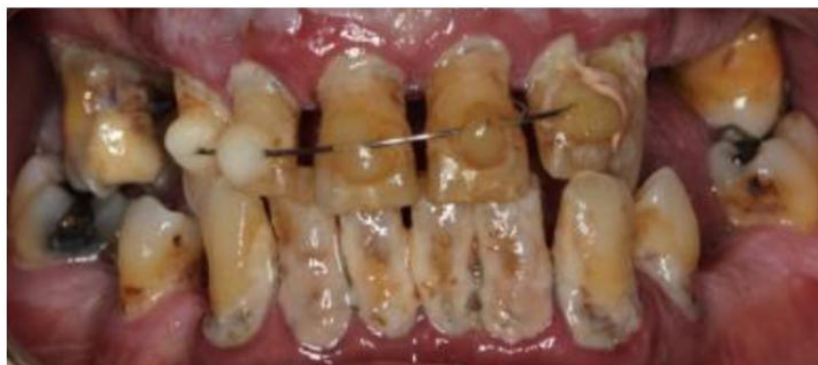

Figure 2: A clinical photograph to illustrate a mouth with poor oral hygiene, severe periodontal disease and multiple carious lesions.

What should we tell patients?

Whilst it is important for patients suffering from TDI's to be treated within the correct timeframe and in the correct environment, it may be helpful and supportive of Emergency Departments to inform patients of what treatment they are likely to receive. In general, displaced teeth may be repositioned under local anaesthesia and then splinted to the adjacent teeth to immobilise them. Fractured teeth may either be built up with a tooth-coloured filling material or if the tooth fragment is available, this may be secured back in position under local anaesthetic. Maintaining meticulous oral hygiene is of paramount importance to aid healing of soft tissues immediately after a TDI. Gentle tooth brushing leading up to normal tooth brushing should be advised for all patients. In a few cases where this is not possible, adjunctive use of diluted chlorhexidine mouthwash for a few days can be helpful.

Patients should be advised not to bite on their traumatised front teeth for two weeks and if required, to take analgesics.

Case Examples

Case 1: Delayed- Fracture Injury

Figure 3 shows a clinical photograph of a patient and their permanent dentition, suffering from a dental fracture injury. This type of injury can be treated on a delayed basis as the tooth is still in position and the injured tooth does not pose an airway risk. Eventual treatment may include nerve treatment and the use of tooth-coloured filling material. It might be prudent to ask the patient if they have the fragment and advise to keep it safe, or indeed enquire if they have any breathing difficulties to exclude the possibility of inhalation of the fragment.

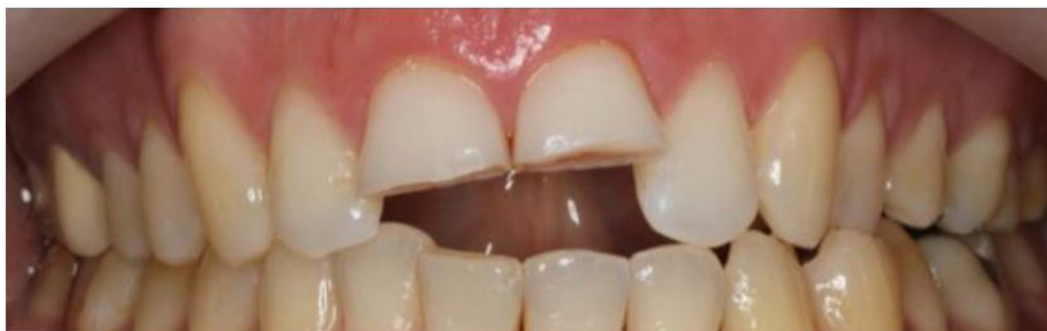

Figure 3: A clinical photograph illustrating complicated crown fractures of permanent upper central incisor teeth

Case 2: Urgent- Displacement Injury

Figure 4 illustrates a displacement injury (extrusion) of the permanent upper right central and lateral incisor teeth (UR1 & UR2 or 11 & 12). These teeth have been displaced towards the palate. If they are mobile, they may pose an airway risk and should be treated on an urgent basis. If patients present in an ED setting with Oral & Maxillofacial Surgery support, they can be called upon for further assistance. If this is not possible, then the patient should be directed to a dental professional. The treatment of loose, displaced teeth may include repositioning the displaced teeth under local anaesthetic and placing a wire splint to immobilise them as seen in Figure 5.

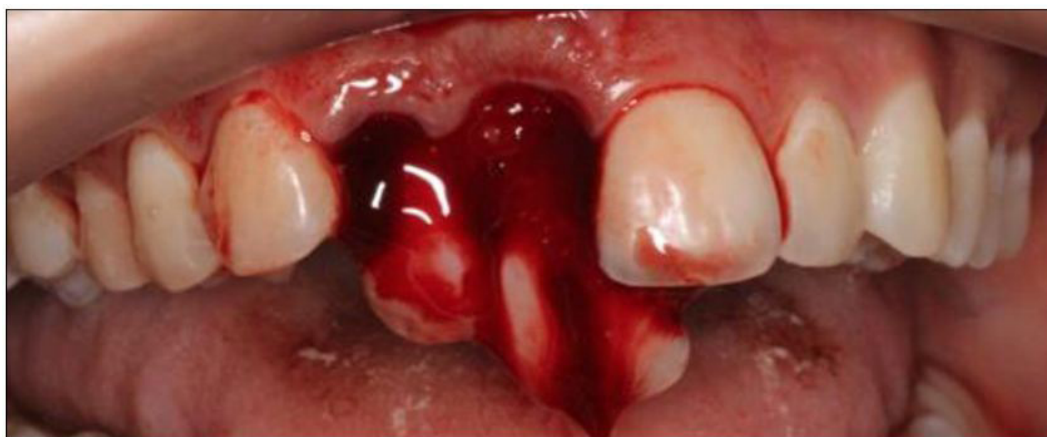

Figure 4: A clinical photograph illustrating a lateral luxation injury with an extrusive component of permanent central and lateral upper right lateral incisor teeth

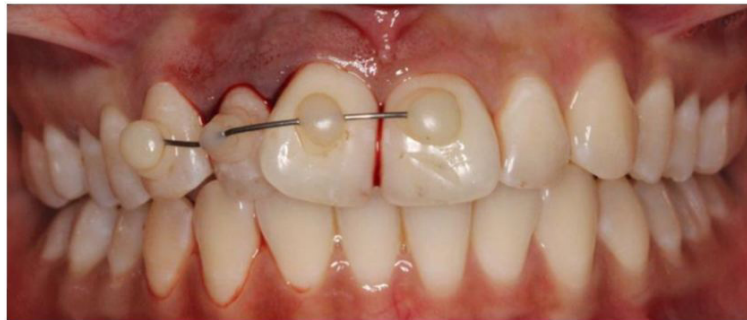

Figure 5: A clinical photograph indicating how displaced permanent teeth are repositioned back into their original place and splinted to allow healing of tissues

Case 3: Emergency- Avulsion injury

Figure 6 demonstrates an avulsion injury where one tooth has been avulsed from its position. A video demonstrating a real case can be seen on the Dental Trauma UK website (www.dentaltrauma.co.uk). In such cases, the teeth should ideally be re-implanted immediately (within 5 minutes) as an emergency at the scene of the accident. If this is not possible, the avulsed tooth/teeth should be placed in a suitable storage medium (e.g. milk or Hartmann's solution) and the patient should go to their dentist as an emergency. In an Emergency Department setting, the ideal treatment would be to re-implant the tooth immediately without delay. The patient should then be referred to the Oral and Maxillofacial team to check the position of the injured or traumatised teeth and splint them. If re-implantation is not possible, then placing the avulsed tooth/teeth into Hartmann's solution until they can see a dentally qualified practitioner would be ideal. If there are any associated jaw fractures, the Oral and Maxillofacial team should be called to manage the patient. Figure 7 illustrates the ideal management of a patient with an avulsed tooth and this can be provided

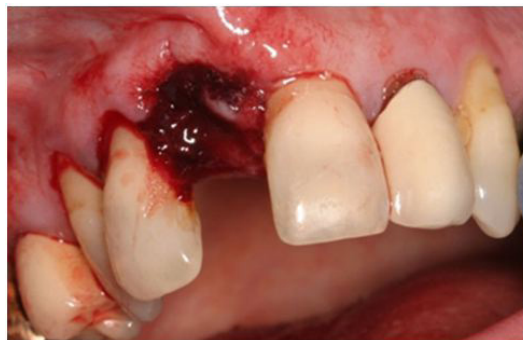

Figure 6: A clinical photograph illustrating an avulsion injury of the upper right central incisor tooth

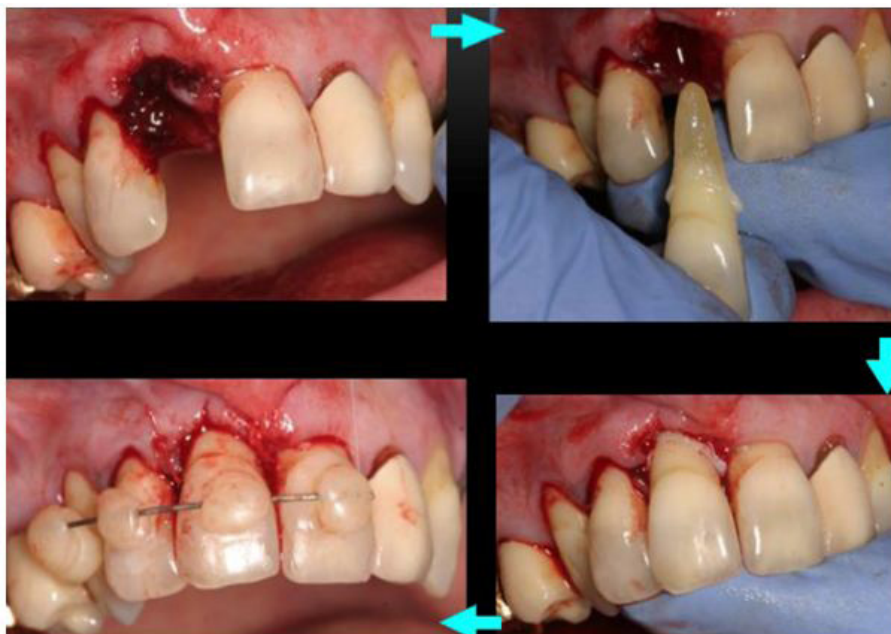


Figure 7: A set of clinical photographs illustrating the sequence of events undertaken to re-implant an avulsed tooth. The ED staff member should carry out the first three steps and the dentist or member of the Oral and Maxillofacial team will finally splint the tooth, as illustrated by the final stage.

at the scene of the accident (best prognosis), in the ED or within the dental surgery. Although the best outcomes would be achieved if a member of the nurse streaming (triage) team could re-implant avulsed teeth minimising delay, this may not be possible due to lack of knowledge or experience in such cases. Placing the tooth/teeth into the storage media mentioned previously would be the next best thing. The Oral and Maxillofacial team can then be called (if there is one) or the patient can be directed to a dental professional.

Implications of this guidance

Emergency Department: Not all hospitals benefit from a dedicated Oral and Maxillofacial surgery unit or an affiliated dental hospital. Subsequently, there may not be a qualified dentist on site to manage dental trauma. The aim of this guidance is to try and provide staff working in Emergency Departments with information and therefore confidence in managing dental trauma with the right treatment at the right time and in the right environment.

From the flow diagram (Figure 1) it is clear that the majority of traumatic dental injuries do not need to be treated as an emergency. The implications for this are that emergency treatment need not take place in a busy ED and would be best delivered in a better-equipped dental clinic. This not only helps ensure that patients get the best care possible following a TDI but also helps appropriate resource management in ED's. The authors stress the importance of immediate re-implantation of avulsed permanent teeth, and this guidance identifies many opportunities for this to be undertaken. The best place for immediate re-implantation is at the place of injury by first responders. If members of the public or paramedics are unable to re-implant at the site of injury, ED reception staff should aim to re-implant the tooth if at all possible. Certainly, if the reception staff are unable to re-implant, then it is of paramount importance that the patient gets priority to be assessed by the ED triage or streaming team (either nurse or doctor) who ideally should aim to re-implant the tooth and if this is also not possible, refer to the Oral and Maxillofacial team or General Dental Practitioner for further investigations and treatment (with the tooth in a suitable storage medium and not dry).

Emergency Department Summary:

- **Avulsed adult teeth** should be **immediately re-implanted** (ideally within 5 minutes)
- Everyone in the ED should be able to re-implant an avulsed adult tooth
- Management of displaced teeth which pose an inhalation risk should be prioritised
- All other fracture and displacement injuries can be treated on a delayed basis by the General Dental Practitioner or the Oral and Maxillofacial Surgery team

Public awareness:

Within the United Kingdom, there are many resources available to the public to raise awareness of dental trauma. Dental Trauma UK is a UK-based charity which provides a campaign promoting awareness of TDI's and their management. In the UK, the National Health Service (NHS) Choices website provides the public with basic advice on how to immediately manage dental trauma, the International Association of Dental Traumatology (IADT) also provides guidance for both the public and goes further to inform healthcare professionals. Such readily available information serves to promote and increase knowledge of treatment of TDI's, with the aim of improving the overall patient outcome and experience. It is the wish of the authors that this guidance, along with others that have been published, fosters an environment where people are confident in managing TDI's through an increased knowledge base. Widespread distribution of the patient pathway as proposed by Figure 1 will help with this goal. Working as a team with knowledge of basic first aid in the management of avulsed teeth should improve the number of teeth saved and reduce long term complications.

Acknowledgements

The authors are grateful to their patients for permitting the use of their clinical photographs.

References

1. Flores MT, Andreasen JO, Bakland LK, Feiglin B, Gutmann JL, et al. (2001) Guidelines for the evaluation and Management of traumatic dental injuries. *Dent Traumatol* 17: 193-8.
2. Flores MT, Andersson L, Andreasen JO, Bakland LK, Malmgren B, et al. (2007) Guidelines for the management of traumatic dental injuries. II. Avulsion of permanent teeth. *Dent Traumatol* 23:130-6.
3. DiAngelis AJ, Andreasen JO, Ebeleseder KA, Kenny DJ, Trope M, et al. (2012) Guidelines for the Management of Traumatic Dental Injuries 1. Fractures and luxations of Permanent Teeth. *Dent Traumatol* 28:2-12.
4. Pitts N, Chadwick B, Anderson T (2015) Children's Dental Health Survey 2013. Report 2: Dental Diseases and Damage in Children: England, Wales and Northern Ireland. Health and Social Care Information Centre.
5. Azami-Aghdash S, Ebadifard Azar F, Pournaghi Azar, Rezapour A, Moradi-Joo M, et al. (2015) Prevalence, aetiology, and types of dental trauma in children and adolescents: systematic review and meta-analysis. *Med J Islam Repub Iran* 29:234.
6. Subhashraj K (2009) Awareness of management of dental trauma among medical professionals in Pondicherry, India. *Dent Traumatol* 25: 92-4.
7. Qazi SR, Nasir KH (2009) First-aid knowledge about tooth avulsions amongst dentists, doctors and lay people. *Dent Traumatol* 25: 295-9.
8. Trivedy C, Kodate N, Ross A, Al-Rawi H, Jaiganesh T, et al. (2012) The attitudes and awareness of emergency department (ED) physicians towards the management of common dentofacial emergencies. *Dent Traumatol* 28: 121-6.

9. Abu-Dawoud M, Al-Enezi B, Andersson L (2007) Knowledge of emergency management of avulsed teeth among physicians and dentists. Dent Traumatol 23: 348-55
10. Patel KK, Driscoll P (2002) Dental knowledge of accident and emergency senior house officers. Emerg Med J 19: 539-41.
11. Gassner R, Bosch R, Tuli T, Emshoff R (1999) Prevalence of dental trauma in 6000 patients with facial injuries. Oral Surg Oral Med Oral Pathol Oral Radiol Endod 87: 27-33.
12. Da Silva AC, Passeri LA, Mazzonetto R, de Moraes M, Moriera RWF (2004) Incidence of dental trauma associated with facial trauma in Brazil: a 1-year evaluation. Dent Traumatol 20: 6-11.
13. Andreassen JO, Andreassen FM, Skeie A, Hjorting-Hansen E, Schwartz O (2002) Effect of treatment delay upon pulp and periodontal healing of traumatic dental injuries- a review article. Dent Traumatol 18: 116-28.
14. Sweet CA (1955) A classification and treatment for traumatized anterior teeth. ASDC J Dent Child 22:144-9.
15. Pagadala S, Tadikonda DC (2015) An overview of classification of dental trauma. IAIM 2: 157-64.
16. Andreassen JO, Andreassen FM (1994) Textbook and colour atlas of traumatic injuries to teeth, (3rd Edn.) Copenhagen Munksgaard, Copenhagen, Denmark, United Kindoms.

Submit your next manuscript to Annex Publishers and benefit from:

- ▶ Easy online submission process
- ▶ Rapid peer review process
- ▶ Online article availability soon after acceptance for Publication
- ▶ Open access: articles available free online
- ▶ More accessibility of the articles to the readers/researchers within the field
- ▶ Better discount on subsequent article submission

Submit your manuscript at

<http://www.annexpublishers.com/paper-submission.php>