

Adrenal Incidentalomas - From Diagnosis to Follow-Up: Endocrine and Imaging Features at Diagnosis and Over Time

Nunes JM^{1,2}, Rodrigues E^{1,2}, Esteves C^{1,2}, Correia R^{2,3}, de Almeida MF⁴, Carvalho D^{1,2} and Ramos I^{2,3}

¹Endocrinology, Diabetes and Metabolism Department, Centro Hospitalar S. João, Alameda Prof. Hernâni Monteiro, Porto, Portugal

²Faculty of Medicine of Porto University, Portugal, Alameda Prof. Hernâni Monteiro, Porto, Portugal

³Radiology Department, Centro Hospitalar S. João, Alameda Prof. Hernâni Monteiro, Porto, Portugal

⁴Clinical Pathology Department, Centro Hospitalar S. João, Alameda Prof. Hernâni Monteiro, 4200-319, Porto, Portugal

*Corresponding author: Nunes JM, MD, Endocrinology, Diabetes and Metabolism Department, Centro Hospitalar S. João, Alameda Prof. Hernâni Monteiro, 4200-319, Porto, Portugal, Tel: +351-916462294, E-mail: joana.maria.menezes@gmail.com

Citation: Nunes JM, Rodrigues E, Esteves C, Correia R, de Almeida MF, et al. (2018) Adrenal Incidentalomas - From Diagnosis to Follow-Up: Endocrine and Imaging Features at Diagnosis and Over Time. J Endocrinol Res Stu 1(1): 103

Abstract

Introduction: Adrenal incidentalomas (AIs) are frequent and although most of them are asymptomatic and benign, some do need treatment. The AIs follow-up has to be as sharp as to avoid missing pathology and to avoid harm and anxiety induced by the follow-up itself. It is, thus, a delicate medical condition for endocrinologists worldwide.

Methods: Retrospective analysis of AIs during 10 years of follow-up. Results of growth rate, hormonal behavior and surgical pathology were evaluated.

Results: Of 271 selected patients, 196 fitted our criteria: age at diagnosis 63.4±10.7years, 62.8% women, 95 left AI (average size: 20±7.7mm), 63 right AI (mean size: 23±10.4mm) and 38 bilateral. After the initial evaluation, six underwent adrenalectomy: four for hyperfunction and two for size >40mm, without malignancy. Of the remaining 190, 48 (25.3%) had imagiological re-evaluations at 4 ± 2 months (1st), 106 (55.8%) at 12 ± 3 months (2nd), 56 (29.5%) at 24 ± 3 months (3rd), 52 (27.4%) at 36 ± 3 months (4th), 30 (15.8%) at 48 ± 3 months (5th), 17 (8.9%) at 60 ± 3 months (6th), 4 (2.1%) at 72 ± 3 months (7th) and 8 (4.2%) at 84 ± 3 months (8th). The growth rate ≥5mm observed at the follow-up evaluations was 1st - 10.8%, 2nd - 9.5%, 3rd - 10.6%, 4th - 15.1%, 5th - 1.3%, 6th - 5.9%, 7th - 0.8%, 8th - 13.3%. Seven patients underwent adrenalectomy because of significant growth, four of them 2 years after diagnosis. None of the incidentalomas became definitely hyperfunctioning nor malignant.

Conclusion: We propose that imaging follow-up should be individualized according to the rate of growth and to the adrenal lesion size.

Keywords: Adrenal incidentalomas; Diagnosis; Follow-up

Introduction

Adrenal incidentalomas (AIs) are defined as adrenal masses measuring 10 mm or more in diameter, incidentally discovered on imaging exams performed for a non-adrenal disorder [1,2].

With improvements in health care services, continued advances in imaging technologies and its widespread availability in daily clinical practice [3], AIs diagnosis is increasing worldwide, representing a modern challenge for physicians. The reported prevalence of AIs is approximately 4-6% of the population [4-6] and slightly higher in patients with a known malignancy, ranging from 9 to 13% [7].

Although the malignancy rate in AIs is low, even in a patient with a known extra-adrenal malignancy [6], the discovery of AIs raises concerns about the potential risk of developing adrenal carcinomas and increased hormonal functionality. These important questions drive the evaluation, determine the therapy and advise the follow-up.

There is no doubt that hyperfunctioning masses and nodules with malignant features constitute surgical indications [3,6,8], but according to the latest European guideline [8] there should not be any further follow-up (imaging and hormonal work-up) in patients with AIs < 4cm with clear benign features and a normal hormonal work-up at initial evaluation, unless new clinical signs of endocrine activity appear or there is worsening of comorbidities (e.g. hypertension and type 2 diabetes). However, there are still some pitfalls regarding AIs management.

Although most of AIs are non-hyperfunctioning, 10 to 15% secrete excess amounts of hormones [9,10], even if episodically. Besides, previously, there was no consensus regarding the cut-off for cortisol level on the overnight dexamethasone suppression test, creating a new category - the so-called 'subclinical hypercortisolism', defined by endocrine abnormalities without signs and/or symptoms of overt cortisol hypersecretion [11]. This entity was as prevalent as 5-30% and up to 12% could develop it in a mean time of 3 years of follow-up [12-14], although progression to overt Cushing's syndrome was rare and a spontaneous normalization had been described [15]. Notwithstanding, the excess cortisol levels, even short-term, may aggravate co-morbidities and compromise health [16].

And so, the hormonal work-up interpretation has changed and nowadays post 1mg-dexamethasone cortisol levels are no longer a categorical variable (yes/no) but a continuous variable [8]: $\leq 50\text{nmol/L}$ ($\leq 1.8\mu\text{g/dL}$) excludes autonomous cortisol secretion; between 51 and 138 nmol/L (1.9-5.0 $\mu\text{g/dL}$) are interpreted as 'possible autonomous cortisol secretion' and $>138\text{nmol/L}$ (5.0 $\mu\text{g/dL}$) are considered as evidence of 'autonomous cortisol secretion'. Additional labs to confirm cortisol secretion might be required and depend on patient will, patient age and clinical evaluation of potentially cortisol-related comorbidities (namely hypertension and type 2 diabetes mellitus). In the presence of 'autonomous cortisol secretion' without signs of overt Cushing's syndrome, it is suggested annual clinical reassessment for related cortisol excess comorbidities and consideration of surgery if it may bring medical benefit [8].

The main reason for no further imagiological follow-up in adrenal masses <4cm with clear benign features at diagnosis has to do with no reports of malignancy development and, on the other hand, with risk of false-positive results and increased psychological and financial burden [8]. Besides, there were some papers pointing out the possible harm caused by extensive and prolonged follow-up of a condition with no reports of malignancy over time. Cawood TJ *et al.* [10] revealed increased concerns about the risk of malignancy due to radiation on follow-up imaging that may be similar to that of the adrenal lesion evolution by itself and argue that many series overestimate malignancy rates and hormonal hyperfunction due to several reasons: inclusion of surgical series, patients with suspicious radiological characteristics, small sample sizes, patients followed in tertiary centres, inclusion of patients with known malignancy, ultrasonography for tumour detection and exclusion of patients with small tumours or benign imaging features.

According to this, and as follow-up is designed to detect malignancy and/or hypersecretion, we aimed to investigate the clinical and imagiological characteristics at diagnosis and over time of subjects with AIs followed in our institution - a single tertiary-care and university hospital in Porto, Portugal (Centro Hospitalar São João).

Materials and Methods

Study design and patients' selection

The study consisted of a comprehensive retrospective analysis of a cohort of patients with adrenal lesions observed at our Centre. We searched for the terms "adrenal nodule(s)" and "adrenal incidentaloma(s)" in the requisitions and reports of all CTs and MRIs performed in our institution between 1st January 2004 and 1st January 2014 - a 10-year follow-up.

Results of hormonal and imaging work-up at diagnosis and overtime during follow-up were evaluated, in order to identify growth rates, malignancy and spontaneous development of hormonal hyperfunction.

Inclusion criteria were adult patients (age ≥ 18 years old), initial and follow-up imaging with computed tomography (CT) scan and/or magnetic resonance imaging (MRI) performed at our Radiology Department, at least two imaging exams available in our Radiology database and incidental diagnosis. To ensure the incidental detection of the adrenal nodule we checked out the medical reports of the patients and included just those with adrenal masses discovered during diagnostic testing or treatment for non-adrenal diseases. We excluded cases in which there were doubts regarding the cause that lead to imaging.

As there were patients with adrenal nodules detected during cancer staging, we performed a subgroup analysis for this particular subgroup.

The remaining patients that did not fit these criteria were excluded.

Assessment of hormonal hyperfunction

For hormonal evaluation, we considered the endocrine analyses performed just in our Clinical Pathology Department and excluded the ones performed in other laboratories. Serum adrenocorticotrophic hormone (ACTH) and cortisol and urinary free cortisol were measured by way of an electrochemiluminescent immunoassay using a Cobas® e411 automated analyser (Roche®). Renin was

measured by way of IRMA (radioimmunoassay method) and aldosterone was measured by way of competitive radioimmunoassay (RIA). Urinary metanephrines and normetanephrines were determined with high performance liquid chromatography (HPLC).

The cortisol cut-off value in overnight 1 mg-dexamethasone suppression test considered for hypercortisolism diagnosis was 5.0 µg/dL (138 nmol/L), in accordance with the American Association of Endocrine Surgeons Medical Guidelines for the management of adrenal incidentalomas [17]. We performed a sub-analysis for patients presenting with cortisol levels post dexamethasone between 1.8µg/dL (50nmol/L) and 5.0µg/dL (138nmol/L).

We collected data regarding baseline hormonal evaluation as well as during follow-up. Hormonal hypersecretion was defined as altered hormonal evaluation.

Assessment of imaging features

Adrenal incidentalomas were defined as adrenal masses measuring 10 mm or more in diameter incidentally discovered on imaging exams performed for a non-adrenal disorder.

The CT scanners of our Radiology Department are Siemens SOMATOM Sensation Cardiac 64[®] and Siemens SOMATOM Emotion Duo[®], and the MRI scanners are Siemens MAGNETOM Trio 3T[®] and Siemens Symphony 1,5T[®].

On MDCT a non-enhancing phase is done in order to measure spontaneous attenuation of the lesion. If the value is ≤10 Hounsfield units (HU) the diagnosis of adenoma is assumed. Otherwise, an enhancing study is performed with acquisitions at 60 seconds and 15 minutes (delayed phase). Then relative and absolute washouts can be calculated. Our MRI protocol to characterize adrenal lesions includes axial in and out of phase, coronal T2w HASTE and axial T2w fat-sat. If this doesn't allow correct characterization a dynamic enhancing study is performed.

Radiologists with a specialist degree or in-training radiologists with supervision by specialists from our Radiology Department reported the CT and MRI findings and displayed the images and the reports in the Radiology database system.

In cases of bilateral nodules, for analysis, we considered just the main AI.

We collected data regarding imaging features, namely size, increasing rate and time of follow-up.

Surgical indications and assessment of surgical pathology

Adrenalectomy was undertaken in patients with hormonal hypersecretion, diameter > 40 mm, significant growth (>20% in the largest diameter) and/or imaging characteristics suspicious for malignancy: irregular shape, inhomogeneous density on CT because of central areas of low attenuation due to tumour necrosis, tumour calcification, high unenhanced CT attenuation values (> 20HU), inhomogeneous enhancement on CT with intravenous contrast, delay in contrast medium washout, hypo intensity compared with liver on T1 weight MRI and high intermediate signal intensity on T2 weight MRI.

Adrenal histologies were analysed in our Pathology Department.

Statistical analysis

Statistical analysis was performed using SPSS[®] version 21.0 for Mac[®]. The data are presented as means ± standard deviations and relative frequencies. Univariate analyses were performed with parametric tests, as the population distribution was normal. Statistical significance was considered for p value < 0.05.

Ethical considerations

The Hospital Ethics Committee approved the study.

Results

From January/2004 to January/2014, 271 patients presented CT and/or MRIs reports referring to "adrenal nodule(s) / adrenal incidentaloma(s)". Several Departments requested these exams: Internal Medicine (n=153; 56.5%), Endocrinology (n=38; 14.0%), General Surgery (n=44; 16.2%), Urology (n=31; 11.4%), Nephrology (n=3; 1.2%) and Neurology (n=2; 0.7%).

The exam that first diagnosed the adrenal lesion was performed namely because of pulmonary and abdominal pathologies as well as emergency room admissions. The subsequent CTs and MRIs were performed not only for AIs follow-up but also because of other pathologies, namely other emergency room admissions and pulmonary diseases, renal and/or urologic problems, liver, gallbladder and/or pancreas pathologies.

Of the 271 patients, 75 were excluded: 15 had just one imaging exam performed at our institution, 10 presented adrenal thickening or hyperplasia, 31 had adrenal nodule detection on cancer staging and 19 underwent CT/MRI because of signs and/or symptoms

of adrenal disease – 9 Cushingoid features, 7 severe hypertension (2 with associated hypokalaemia) and 3 hirsutism/virilisation. And so, 196 patients fitted our criteria (Figure 1).

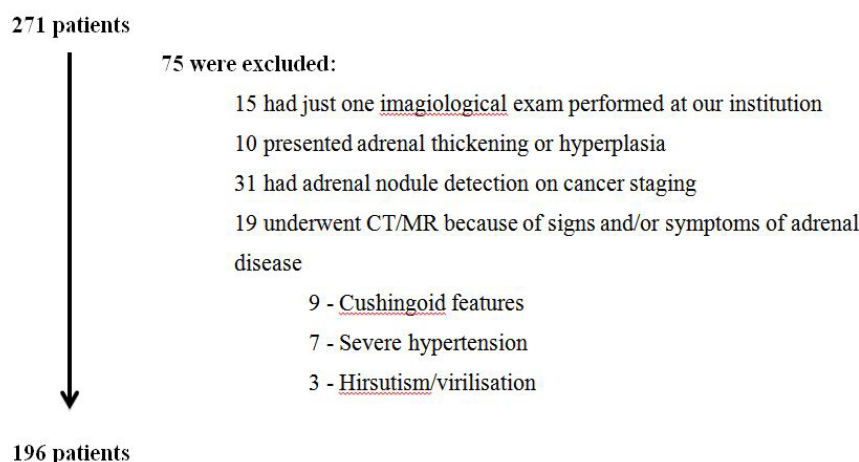


Figure 1: Patients' exclusion

Female patients represented the majority of the sample size representing 62.8% (123/196) with men accounting for 37.2% (73/196) (Table 1).

CHARACTERISTIC	N (%) OR MEAN \pm SD	<i>p</i> value
Sex:		
Male	73 (37.2%)	0.034
Female	123 (62.8%)	
Age at diagnosis (years)	63.4 \pm 10.7	-
Location of the tumour:		
Left	95 (48.5%)	0.029
Right	63 (32.1%)	
Bilateral	38 (19.4%)	
First imaging Technique		
CT	149 (76.0%)	0.022
MRI	47 (24.0%)	
Second imaging Technique		
CT	95 (48.5%)	0.127
MRI	101 (51.5%)	
Tumour size (widest diameter) (cm):		
Left	20 \pm 7.7 mm	0.971
Right	23 \pm 10.4 mm	
Nr of patients with more than 1 tumour	56	-
Follow up (months)		
minimum	43.5 \pm 23.4	-
maximum	5 106	
Growth		
Left incidentaloma	8.2 \pm 14.3 mm	0.81
Right incidentaloma	7.3 \pm 15.1 mm	

Table 1: Clinical Characteristics (N=196)

Ninety-five patients (48.5%) presented left AIs (*p*-value =0.029) with an average size of 20 \pm 7.7mm; 63 patients (32.1%) presented right AIs measuring 23 \pm 10.4mm; and 38 patients (19.4%) presented bilateral ones. We found no statistical differences on adrenal incidentalomas' size, regarding side of presentation (*p*-value =0.971) (Table 1).

The first imaging performed was the CT scan in 76% of the patients (n=149 versus n=47 MRIs – *p*-value =0.022) and the second technique requested by the physicians was the CT scan in 95 patients (48.5%) and the MRI in 101 patients (51.5%) (*p*-value =0.127) (Table 1). All of the patients that first performed a MRI were re-evaluated also by MRI and 54 of the patients first evaluated by CT scan were re-evaluated by MRI.

Overall, mean time of follow-up was 43.5 \pm 23.4months and the observed growth concerning the left incidentaloma was 8.2 \pm 14.3mm versus 7.3 \pm 15.1mm concerning the right one (*p*-value =0.81; CI95% [-1,23; 1,57]) (Table 1). In 6 patients there was complete regression of the incidentalomas previously reported (dimensions ranging from 11mm to 13 mm; 4 initially diagnosed by CT scan

and re-evaluated by MRI and 2 diagnosed and re-evaluated by CT scan) and 22 developed another adrenal nodule during follow-up: 10 on the same side and 12 on the contralateral adrenal gland. All of these newly diagnosed adrenal incidentalomas were non-hyperfunctioning, benign and presented an overall growth rate of 4.5±11.4mm.

Of the 196 patients, 2 patients presented hypercortisolism, 2 patients presented hormonal alterations compatible with pheochromocytoma and 6 patients did not undergo hormonal work-up.

After the initial evaluation, 6 patients underwent adrenalectomy: 4 for hyperfunction and 2 for size >40 mm (both presenting <10HU, regular and homogeneous lesions and one of the two with imaging features suggesting a myelolipoma and measuring 56mm). Histologies revealed four cortical adenomas, one benign oncocytoma (the adrenal nodule with imaging characteristics of myelolipoma) and one pheochromocytoma (Table 2).

EVALUATION AND MANAGEMENT AT DIAGNOSIS	N (%)
Endocrine evaluation	
Not performed	6 (3.1%)
Non-hyperfunctioning	190 (96.9%)
Hyperfunctioning	4 (2.0%)
Hypercortisolism	2
Catecholamine overproduction	2
Imagiological evaluation	
> 40 mm	2 (0.1%)
< 40 mm	194 (98.9%)
Management	
Follow up	190 (96.9%)
Surgery	6 (3.1%)
hyperfunction	4
size > 40 mm	2
Histologies	
Cortical adenoma	4
Oncocytoma	1
Pheochromocytoma	1

Table 2: Endocrine and Imagiological Evaluations at Diagnosis and Its Clinical Management

Of the remaining 190, 48 (25.3%) had imaging re-evaluations at 4±2months (1st), 106 (55.8%) at 12±3months (2nd), 56 (29.5%) at 24±3months (3rd), 52 (27.4%) at 36±3months (4th), 30 (15.8%) at 48±3months (5th), 17 (8.9%) at 60±3months (6th), 4 (2.1%) at 72±3months (7th) and 8 (4.2%) at 84±3months (8th). A growth rate ≥5mm (compared to the initial scan) observed at the follow-up evaluations was 1st - 10.8%, 2nd - 9.5%, 3rd - 10.6%, 4th - 15.1%, 5th - 1.3%, 6th - 5.9%, 7th - 0.8%, 8th - 13.3% (Table 3). Because the reason for imaging was in many cases not related to AIs follow-up, especially after the 2 preconized years after diagnosis, the ones scanned at interval 4th were not the same patients scanned at other timings.

Time (months)	N	%	Growth rate ≥ 5mm
4±2	48	25.3	10.8%
12±3	106	55.8	9.4%
24±3	56	29.5	10.4%
36±3	52	27.4	14.6%
48±3	30	15.8	0%
60±3	17	8.9	5.9%
72±3	4	2.1	0%
84±3	8	4.2	12.5%

Table 3: Imagiological Re-Evaluations at 6 and 12 Months and Each Year after (Comparing To The First Exam)

As this is a retrospective study that reports to a maximum period of follow up of 106 months and many of these patients underwent several imaging exams performed not because of the AIs management but for other medical unrelated reasons, we also analysed the growth rate within the time between the performed imaging (Table 4).

Over time, 7 patients were submitted to adrenalectomy because of significant growth (>20% diameter). In 4 patients, the growth that led to surgery occurred two years after diagnosis (one patient at 4th year of follow-up; two patients at 4.5 years of follow-up and one other patient at 5 to 5.5 years of follow-up). In all cases, the nodules kept benign imaging characteristics and surgical pathology revealed cortical adenomas. In our series, none of the adrenal incidentalomas became malignant.

Exams	Time Between the imagiological exams (months) mean \pm SD	Main left adrenal incidentaloma		Main right adrenal incidentaloma	
		Growth (mm) mean \pm SD [min; max]	Mean growth %	Growth (mm) mean \pm SD [min; max]	Mean growth %
1 st – 2 nd exams	15.1 \pm 9.87	0.24 \pm 3.03 [-8.0; 15.0]	2.7%	0.19 \pm 2.40 [-10.0; 6.0]	0.8%
1 st – 3 rd exams	30.2 \pm 13.72	0.33 \pm 3.37 [-10.0; 15.0]	4.6%	0.62 \pm 3.58 [-10.0; 10.0]	3.3%
1 st – 4 th exams	43.5 \pm 13.38	0.14 \pm 3.63 [-10.0; 9.0]	3.6%	0.34 \pm 3.63 [-10.0; 9.0]	3.2%
1 st – 5 th exams	60.1 \pm 16.73	0.31 \pm 4.39 [-10.0; 10.0]	4.3%	0.36 \pm 3.73 [-10.0; 9.0]	2.9%
2 nd – 3 rd exams	15.7 \pm 9.00	0.31 \pm 3.02 [-13.0; 15.0]	3.4%	0.55 \pm 2.71 [-10.0; 10.0]	3.2%
3 rd – 4 th exams	15.3 \pm 7.74	0.30 \pm 2.46 [-9.0; 9.0]	2.9%	-0.15 \pm 2.05 [-8.5; 4.0]	0.0%
4 th – 5 th exams	19.2 \pm 11.13	0.69 \pm 2.55 [-2.0; 13.0]	3.8%	0.30 \pm 1.65 [-5.0; 4.0]	1.8%

Table 4: Imagiological Exams Performed Over Time and Observed Growth

Regarding endocrine follow-up, the 6 patients who lacked initial hormonal analyses also did not have further hormonal evaluation. Of the remaining 190 patients (as 6 were submitted to surgery), 141 (74.2%) did it every year after and in 49 patients (25.8%) up to 8 years. None of them became hormonally active.

Considering the cortisol level post dexamethasone $>5.0\mu\text{g/dL}$ (138nmol/L) 2 were diagnosed with hypercortisolism and so initially submitted to adrenalectomy. Considering the cortisol level post dexamethasone of $>1.8\mu\text{g/dL}$ (50nmol/L) and $<5.0\mu\text{g/dL}$ (138nmol/L), we found 34 patients with at least one positive test (without overt Cushing's syndrome), 9 patients on the initial hormonal work-up and the remaining over time.

In what concerns the subgroup analysis for the 31 patients that had adrenal nodule detection during cancer staging, 16 patients (51.6%) were referred to Endocrinology for hormonal evaluation and the remaining did not performed endocrine work-up in our Hospital. None of the evaluated nodules revealed hypersecretion, the AIs imaging features were benign and none of the patients were submitted to adrenalectomy. Fifteen patients presented left adrenal nodule and the remaining on the right side and the overall growth of these lesions was $0.6\pm 0.2\text{cm}$ in a mean time of 26 ± 14.2 months.

Discussion

In our series, we found AIs significantly more prevalent in female gender (in accordance to what has been described and assumed as a result of a referral bias [1]) and being diagnosed more often in the 7th decade of life, also concordant with other reports [1] and maybe related with the increasing diagnostic procedures with ageing.

Curiously, several case series describe an increased incidence of AIs on the right adrenal gland [9]. We found AIs to be statistically significant more frequent on the left adrenal gland. Actually, there is no explanation for an eventual mechanism behind this observed tendency.

On initial hormonal work-up, only 4 (2.0%) were hyperfunctioning, in accordance with other studies [14,18-20], reinforcing that the majority of AIs are non-functioning. And on initial imaging evaluation, 2 patients underwent adrenalectomy because of the size ($>40\text{mm}$, the threshold size found to have the highest sensitivity for differentiating adrenocortical carcinoma from benign lesions and thus limiting unnecessary surgery without missing malignancy [21-23]). It has to be considered that this is a cut-off value proposed by retrospective studies with other thresholds being proposed but with less evidence [6,24] and that the assessment of the lipid content and wash-out of contrast should be taken in consideration when assessing an adrenal mass [8,22-25].

The resected incidentalomas were benign, as in other series [18,19]: 4 adrenocortical adenomas, 1 pheochromocytoma so far without metastasis and 1 benign oncocytoma.

Regarding AIs imaging behaviour, they did increase in size after 4 years of follow-up, nevertheless the great majority without formal indication for surgery (diameter $>40\text{mm}$; significant growth rate $>20\%$ largest diameter and/or suspicious imaging features). It has been reported that an adrenal mass enlargement of at least 1cm after a follow-up period of 4 years occurs in 5-20% of the patients [26] and indeed some authors propose individualized imagiological follow-up and algorithms [25]. In our series, despite growth, there was no observed malignancy and/or hyperfunction, in accordance other reports [6,8,10,18,19,27,28].

In what concerns hypercortisolism evaluation, we also considered (in 2014) the post dexamethasone cortisol threshold (overnight 1mg dexamethasone suppression test) advocated by the American guideline [17] published in 2009 – a diagnosis cut-off value of $5.0\mu\text{g/dL}$ (138 nmol/L), in accordance with the initial proposed in 2002 by the National Institutes of Health (NIH) state-of-the-science conference panel recommendation [29]. However, many papers [11-16] suggested that there could be periods of possible autonomous cortisol secretion without overt Cushing's syndrome and Barzon *et al.* [30] reported that approximately 8% of 130 patients with AIs developed hypercortisolism (subclinical or overt) during long-term follow-up, especially those with baseline

hormonal alterations, masses ≥ 3 cm in size or exclusive radio cholesterol uptake. According to Terzolo *et al.* [31], most of the new hypothalamic pituitary adrenal axis abnormalities detected during follow-up do not have clinical relevance and may even disappear at a later stage. In our study, some AIs exhibited possible / autonomous hypercortisolism but none developed overt Cushing's syndrome none became definitely hyperfunctioning over time.

Considering this pitfall, the latest European guideline [8] recommends careful interpretation of cortisol levels, especially between the thresholds of 1.8 $\mu\text{g}/\text{dL}$ (50 nmol/L) and 5.0 $\mu\text{g}/\text{dL}$ (138 nmol/L). This approach is more suitable for detection of hypercortisolism but at a higher cost of more false-positive results and higher psychological and social burden. And it is also important to underline that the best standard of care has always to take into consideration the patient itself, its age and comorbidities [8].

Our study presents some limitations, namely being a retrospective, single centre one (in a tertiary centre) and because the imaging follow-up analysis was made with different imaging exams (CT scan; MRI) at different timings and without following a standard procedure. Nevertheless, it has a considerable number of patients, a long-term follow-up period and a subgroup analysis for patients harbouring cancer and for cortisol thresholds.

Conclusions

Initial hormonal and imaging evaluations are mandatory in order to establish malignancy and hyperfunction. In our series, we found no malignancy and no persistent hormonal hyperfunction during the follow-up, although we did find cortisol fluctuations over time. As we observed AIs growth after the two initial years and in four cases with surgical indication (although without malignancy), we propose that imaging follow-up should be individualized according to the rate of growth, to the adrenal lesion size and an eventual underlying malignancy of the patient. We also believe that endocrine follow-up should be performed and individualized according to the signs and/or symptoms of the patients (namely worsening of possible Cushing's syndromes comorbidities).

References

1. Terzolo M, Stigliano A, Chiodini I, Loli P, Furlani L, et al. (2011) AME Position Statement on adrenal incidentalomas. *Eur J Endocrinol* 164: 851-70.
2. Arnaldi G, Boscaro M (2012) Adrenal incidentaloma. *Best Pract Res Clin Endocrinol Metab* 26: 405-19.
3. Oh JY (2013) How to approach and follow adrenal incidentaloma? *Korean J Intern Med* 28: 541-3.
4. Boland GW, Blake MA, Hahn PF, Mayo-Smith WW (2008) Incidental adrenal lesions: principles, techniques and algorithms for imaging characterization. *Radiology* 249: 756-75.
5. Singh PH, Buch HN (2008) Adrenal incidentalomas: evaluation and management. *J Clin Pathol* 61: 1168-73.
6. Young Jr WF (2007) Clinical practice: the incidentally discovered adrenal mass. *N Engl J Med* 356: 601-10.
7. Bovio S, Cataldi A, Reimondo G, Sperone P, Novello S, et al. (2006) Prevalence of adrenal incidentalomas in a contemporary computerized tomography series. *J Endocrinol Invest* 29: 298-302.
8. Fassnacht M, Arlt W, Bancos I, Dralle H, Newell-Price J, et al. (2016) Management of adrenal incidentalomas: European Society of Endocrinology Clinical Practice Guideline in collaboration with the European Network for the Study of Adrenal Tumors. *Eur J Endocrinol* 175: G1-G34.
9. Mantero F, Terzolo M, Arnaldi G, Osella G, Masini AM, et al. (2000) A survey on adrenal incidentalomas in Italy. Study Group on Adrenal Tumors of the Italian Society of Endocrinology. *J Clin Endocrinol Metab* 85: 637-44.
10. Cawood TJ, Hunt PJ, O'Shea D, Cole D, Soule S (2009) Recommended evaluation of adrenal incidentalomas is costly, has high false-positive rates and confers a risk of fatal cancer that is similar to the risk of the adrenal lesion becoming malignant; time for a rethink? *Eur J Endocrinol* 161: 513-27.
11. Chiodini I (2011) Clinical review: Diagnosis and treatment of subclinical hypercortisolism. *J Clin Endocrinol Metab* 96: 1223-36.
12. Bernini GP, Moretti A, Oriandini C, Bardini M, Taurino C, et al. (2005) Long-term morphological and hormonal follow-up in a single unit on 115 patients with adrenal incidentalomas. *Br J Cancer* 92: 1104-9.
13. Yener S, Ertilav S, Secil M, Demir T, Akinci B, et al. (2010) Prospective evaluation of tumor size and hormonal status in adrenal incidentalomas and hormonal status in adrenal incidentalomas. *J Endocrinol Invest* 33: 32-6.
14. Comlekci A, Yener S, Ertilav S, Secil M, Akinci B, et al. (2010) Adrenal incidentaloma, clinical, metabolic, follow-up aspects: single centre experience. *Endocrine* 37: 40-6.
15. Vassilatou E, Vryonidou A, Michalopoulou S, Manolis J, Caratzas J, et al. (2009) Hormonal activity of adrenal incidentalomas: results from a long-term follow-up study. *Clin Endocrinol (Oxf)* 70: 674-9.
16. Androulakis II, Kaltsas GA, Kollias GE, Markou AC, Gouli AK, et al. (2014) Patients with apparently non-functioning adrenal incidentalomas may be at increased cardiovascular risk due to excessive cortisol secretion. *J Clin Endocrinol Metab* 99: 2754-62.
17. Zeiger MA, Thompson GB, Duh QY, Hamrahian AH, Angelos P, et al. (2009) American Association of Clinical Endocrinologists and American Association of Endocrine Surgeons Medical Guidelines for the Management of Adrenal Incidentalomas: executive summary of recommendations. *Endocrine Practice* 15: 450-3.
18. Bülow B, Jansson S, Juhlin C, Steen L, Thorén M, et al. (2006) Adrenal incidentaloma – follow-up results from a Swedish prospective study. *Eur J Endocrinol* 154: 419-23.
19. Dimitropoulos I, George R, Pickering E, Bower L, Waterson M, et al. (2011) Clinical outcomes of adrenal incidentalomas over a 3-year period: a retrospective analysis to evaluate a new referral pathway. *Endocrine abstracts* 25: Poster 188.
20. Muth A, Hammarstedt L, Hellström M, Sigurjónsdóttir HÁ, Almqvist E, et al. (2001) Cohort study of patients with adrenal lesions discovered incidentally. *Br J Surg* 98: 1381-91.
21. Terzolo M, Bovio S, Pia A, Reimondo G, Angeli A (2009) Management of adrenal incidentaloma. *Best Pract Res Clin Endocrinol Metab* 23: 233-43.

22. Kasperlik-Zaluska AA, Otto M, Cichocki A, Roslonowska E, Slowińska-Srzednicka J, et al. (2008) Incidentally discovered adrenal tumours: a lesson from observation of 1444 patients. *Horm Metab Res* 40: 338-41.
23. Sturgeon C, Shen WT, Clark OH, Duh QY, Kebebew E (2006) Risk assessment in 457 adrenal cortical carcinomas: how much does tumour size predict the likelihood of malignancy? *J Am Coll Surg* 202: 423-30.
24. Grumbach MM, Biller BM, Braunstein GD, Campbell KK, Carney JA, et al. (2003) Management of the clinically inapparent adrenal mass ('incidentaloma'). *Ann Intern Med* 138: 424-9.
25. Garrett RW, Nepute JC, Hayek ME, Albert SG (2016) Adrenal incidentalomas: controversies and modified recommendations. *AJR Am J Roentgenol* 206: 1170-8.
26. Morelli V, Reimondo G, Giordano R, Della Casa S, Policola C, et al. (2014) Long-term follow-up in adrenal incidentalomas: an Italian Multicenter Study. *J Clin Endocrinol Metab* 99: 827-34.
27. Song JH, Chaudhry FS, Mayo-Smith WW (2008) The incidental adrenal mass on CT: prevalence of adrenal disease in 1049 consecutive adrenal masses in patients with no known malignancy. *AJR Am J Roentgenol* 190: 1163-8.
28. Mansmann G, Lau J, Balk E, Rothberg M, Miyachi Y, et al. (2004) The clinically inapparent adrenal mass: update in diagnosis and management. *Endocr Rev* 25: 309-40.
29. National Institutes of Health (2002) National Institutes of Health State-of-the-Science Conference on management of the clinically inapparent adrenal mass ("incidentalomas") NIH Consens State Sci Statements, Press Release, USA.
30. Barzon L, Fallo F, Sonino N, Boscaro M (2002) Development of overt Cushing's syndrome in patients with adrenal incidentalomas. *Eur J Endocrinol* 146: 61-6.
31. Terzolo M, Reimondo G, Angeli A (2009) Definition of an optimal strategy to evaluate and follow-up adrenal incidentalomas: time for further research. *Eur J Endocrinol* 161: 529-32.

Submit your next manuscript to Annex Publishers and benefit from:

- ▶ Easy online submission process
- ▶ Rapid peer review process
- ▶ Online article availability soon after acceptance for Publication
- ▶ Open access: articles available free online
- ▶ More accessibility of the articles to the readers/researchers within the field
- ▶ Better discount on subsequent article submission

Submit your manuscript at

<http://www.annexpublishers.com/paper-submission.php>