

Ulcer with Fatal Perforation of a Gastric Blind Pouch: A Rare and Un-Expected Complication after a Salvage Reconstruction for Esophagus

Amoroso M^{1,2}, Agko M¹, Santecchia L^{1,3} and Chen H-C^{*1}

¹Department of Plastic and Reconstructive Surgery, China Medical University Hospital, Taichung, Taiwan

²University of Gothenburg, The Sahlgrenska Academy, Institute of Clinical Sciences, Department of Plastic Surgery, Sahlgrenska University Hospital, Göteborg, Sweden

³Plastic and Maxillofacial Surgery Unit, Bambino Gesù Children's Hospital, Rome, Italy

*Corresponding author: Chen H-C, Department of Plastic and Reconstructive Surgery, China Medical University Hospital, 2 Yuh- Der Rd, Taichung, Taiwan 40447, Republic of China, Tel: +46761169227, E-mail: d19722@mail.cmuh.org.tw

Citation: Amoroso M, Agko M, Santecchia L, Chen H-C (2025) Ulcer with Fatal Perforation of A Gastric Blind Pouch: A Rare and Un-Expected Complication After A Salvage Reconstruction for Esophagus. *J Gastroenterol Compl* 7(1): 102

Received Date: May 06, 2025

Accepted Date: May 20, 2025

Published Date: May 25, 2025

Abstract

We present a case of total esophageal reconstruction with a free Jejunal flap in a patient with a history of esophagectomy and two previous failed attempts at reconstruction. Despite the technique here described offers a reliable option when the stomach and colon are not available, the success of the reconstruction might be compromised by the onset of a perforated ulcer at the gastric blind pouch related to previous failed gastric pull-up (GPU) After a major reconstructive surgery of long hours, gastric pouch may develop ulcer with perforation and fatal empyema due to stress, although the severe complication is rare. Surgeons performing esophageal reconstruction should be aware of the risks related to the presence of the blind pouch. The indications and limits of the reconstructive technique used as well as the rapid development of this unexpected and severe complication are discussed.

Keywords: Gastric perforation; Esophageal reconstruction.

Introduction

Esophageal defects requiring either partial or total reconstruction can be traded with several well-described methods [1]. The stomach remains the most common conduit used in esophageal reconstruction and the gastric pull-up (GPU) is the technique frequently utilized as first attempt [2]. However, GPU is associated with significant morbidity and mortality due to potentially lethal complications [3,4]. Gastric tube perforation due to ulcer formation represents the most dangerous and insidious complication, because its often asymptomatic onset and course [5]. If not identified and managed properly, it can lead to devastating consequences such as mediastinitis, sepsis, and death. Literature is limited to short reports of gastric tube ulcer bleeding after primary GPU esophageal reconstruction. Herein, we present a complex case of esophageal reconstruction with extended jejunum complicated with a perforated ulcer in the gastric blind pouch. To the best of our knowledge, perforation of the gastric blind pouch has not been reported before.

Case Report

A 77-year-old man who underwent esophagectomy for esophageal carcinoma and two failed attempts at reconstruction. Initially, he underwent Ivor-Lewis esophagectomy and gastric pull-up, complicated by anastomotic leakage and right empyema. After debridement, the proximal end of the stomach was closed and left as a blind pouch in the thoracic cavity. A year later, a second attempt at reconstruction was undertaken with substernal colonic interposition. Postoperatively the patient developed cervical anastomotic leakage due to colon tip necrosis. The attempt to manage this complication with insertion of endoscopic metal stent failed. Subsequently the stent were removed and a cervical esophagostomy with closure of the colonic stump was performed. The patient was then referred to our institution for a cervical esophageal reconstruction. As the operative report described a gap of 3 cm between the cervical esophagus and proximal colon, we planned a free jejunal flap interposition. During the exploration we noticed that the proximal end of the previously interposed colon segment was not patent below the clavicle, therefore a total esophageal

reconstruction became necessary (Figure1). Via a midline laparotomy, extensive heterolysis was performed, a long free jejunal flap (30cm) based on the third jejunal vessels was harvested. The flap esophagus the flap was re-vascularized performing end-to-end microvascular anastomosis interposing a 15 cm saphenous vein graft between left thoracoacromial artery and the pedicle's artery. The left cephalic vein was transposed and used as a recipient vein (Figure 2). A large fascio cutaneous rotation flap was raised for

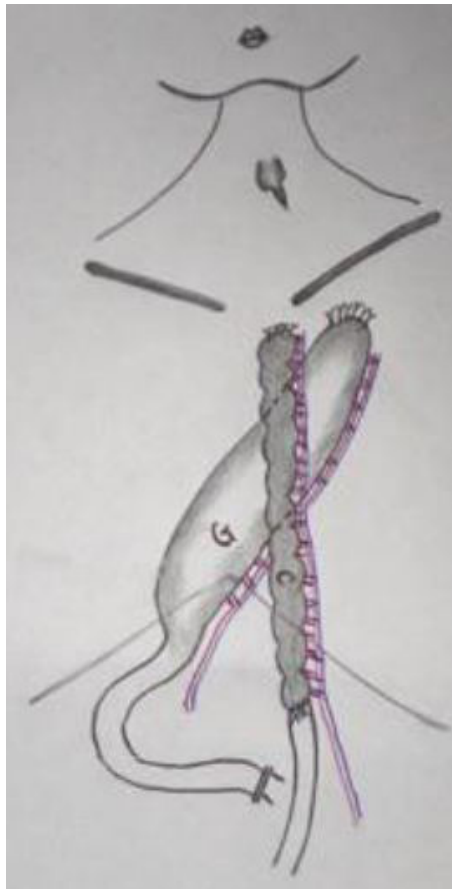


Figure 1: Illustration of the anatomy resulting after the first attempt of reconstruction with the stomach (GPU). The proximal end of the stoma was closed and left as a blind pouch in the thoracic cavity.

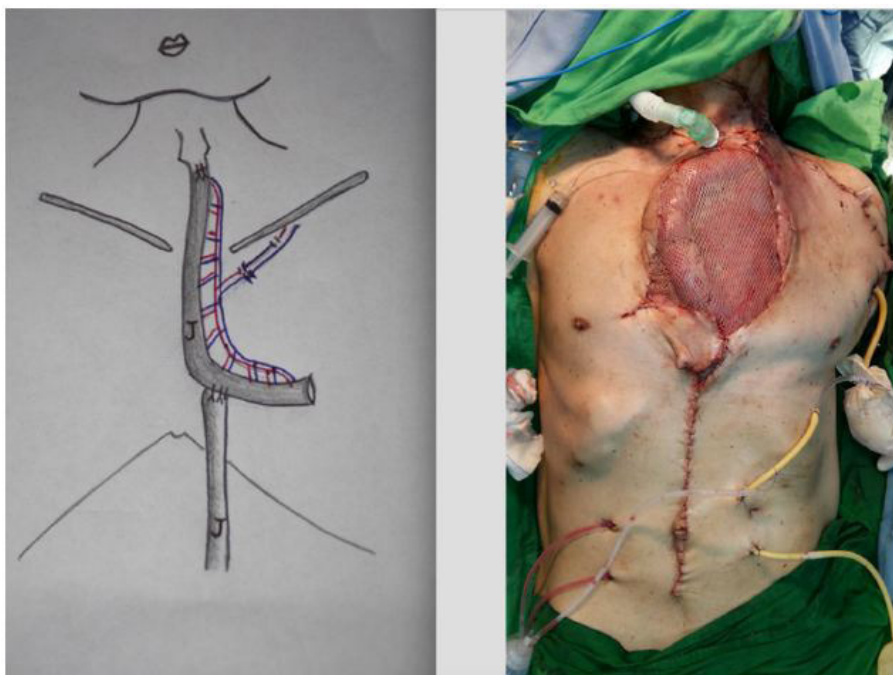


Figure 2: Illustration of the anatomy resulting after the reconstruction with the Jejunal flap (Left). At the cephalic end, the flap was sutured to the pharynx with 3-0 PDS sutures. At the caudal end, the Jejunal flap was sutured to the remaining distal part of the jejunum in an end-to-side fashion. On the donor site, a Jejuno-Jejunal anastomosis was performed in end-to-side fashion and the ascending limb was anastomosed to the caudal end of the free Jejunal flap. Immediate post operative foto (Right).

coverage of the vascular pedicle and part of the jejunal flap. The rest of the defect was covered with meshed skin graft to allow flap monitoring. Postoperatively esomeprazole was given to the patient to prevent ulcer formation in the gastric pouch. The wound healed well with complete survival of the flap. Despite the correct administration of ulcer prophylaxis with proton pump inhibitor (PPI), two weeks after the procedure, the patient developed gastrointestinal bleeding with tarry content from the jejunostomy and tarry stool. A bleeding due to gastric tube ulcer was suspected. The angiography confirmed the presence of the ulcer and its location on the posterior wall of the gastric blind pouch, left in the thorax during the previous GPU (Figure 3). A massive right hemothorax was noted on CT scan. The patient was first stabilized with aggressive blood component therapy and high dose PPI. When perforation and empyema occurred the chest surgeon was afraid that the surgical intervention might cause more risk to the patient and decided to treat conservatively. The bleeding was then controlled with trans-arterial embolization (TAE) and the hemothorax was drained with chest tubes. The surgical repair of the fistula was postponed in light of the poor general status of the patient. Patient's blood test results showed an overall deterioration of patient's condition, with a high C-reactive protein level, low albumin level (lower than 2.5 g/dL), increasing creatinine (2.1 mg/dL) and bilirubin level (7 mg/dL). The severe septic status evolved in septic shock and subsequently multi-organ failure that caused the death of the patient on the 18th postoperative day.

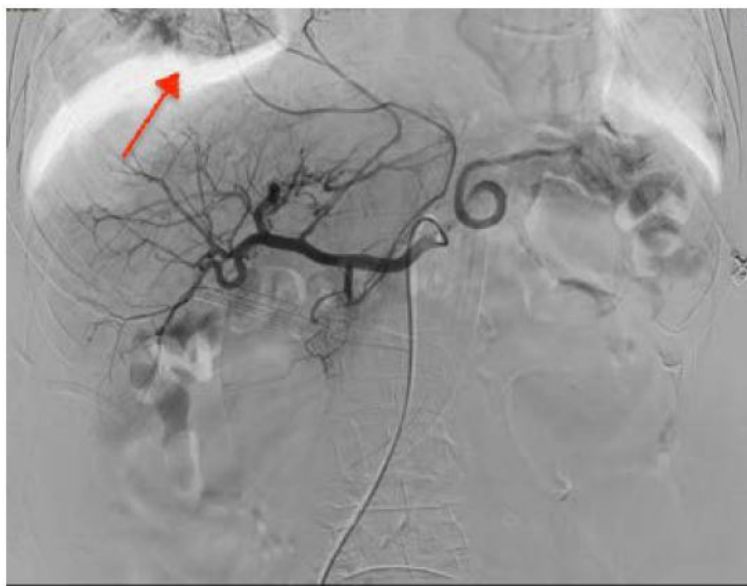

Figure 3: Angiography that shows bleeding point of the gastric pouch. showing shows bleeding point the perforated ulcer at the gastric blind pouch.

Discussion

The GPU procedure is widely used as first-line method in primary esophageal reconstruction. The GPU procedure is widely used as first-line method in primary esophageal reconstruction due to several advantages as shorter operating time required and reduced morbidity if compared with microsurgical reconstruction with intestinal flaps. However, critical complications associated with the GPU procedure are not rare events and their incidence is reported from 0 % to 33% [3]. Esophageal reconstruction following GPU failure is best addressed using intestinal flaps, because of their properties and lower complication rate compared with myocutaneous or fasciocutaneous free flaps [2]. However, if the stomach and colon have been already sacrificed, esophageal reconstruction can be extremely challenging, because of the limited available options and the anatomical impairment related to previous surgeries. In these cases, an extended jejunum flap could be used for the creation of a new food pathway, as the success of this procedure requires extensive experience and a meticulous technical execution. In addition to that, it is important to remember the existence of possible life-threatening complications related to previous failed GPU reconstruction. In the case presented here, in spite of the successful esophageal reconstruction, the bleeding ulcer formation in the gastric blind pouch led to a gastric perforation and hemothorax (Figure 3). Literature on peptic ulceration after GPU is limited with only short reports of cases after primary esophageal reconstruction. Studies report an incidence of gastric tube ulcer of 6.6%-19.4% [5]. Ulcers developed 1-44 months after surgery, but cases have been reported up to 150 months after surgery [5]. Such ulcerations are thought to be secondary to excessive acid production, anatomical impairment, lack of stress ulcer prophylaxis or use of non-steroidal anti-inflammatory drugs. Due to lack of consensus on how to manage this complication, several management approaches have been suggested [6]. Successful healing of a gastric tube ulcer can be obtained by conservative PPI treatment in selected cases [5]. Trans-arterial embolization (TAE) has been previously used to control bleeding from ulcer perforating into the intercostal artery [7]. Resection of the ulcer and surgical repair is usually advocated for intrathoracic perforations [4]. However, the risks related to the presence of the blind pouch are persistent, unless the gastric tube is removed. One case of laparoscopic resection of the entire gastric pouch has been reported for the treatment of a refractory anastomotic ulcer [8]. We believe that in order to avoid risk related with the presence of a gastric pouch in the thorax, its resection might represent an option in selected cases when GPU procedure already failed. When the gastric pull-up fails, the surgeon may consider removal of the blind pouch. If removal is difficult, the other option is to leave

it alone in the chest, but if ulcer and massive bleeding develop in the blind pouch (such as this case) no room for procrastination and a combined procedure of open surgery and endoscopic hemostasis for the bleeders should be performed promptly to avoid further complications.

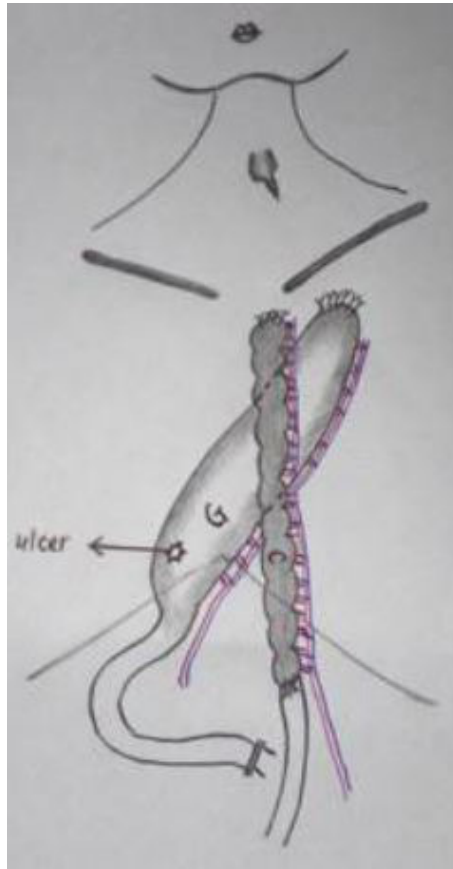


Figure 4: Illustration of the anatomy resulting after the first attempt of reconstruction with the stomach (GPU) with a posterior mediastinal route showing the perforated ulcer at the gastric blind pouch.

References

1. Chen H-C, Tang Y-B (2000) Microsurgical reconstruction of the esophagus. *Semin Surg Oncol* 19: 235-45.
2. Sacak B, Orfanotis G, Nicoli F, Liu EW, Ciudad P, et al. (2016) Back-up procedures following complicated gastric pull-up procedure for esophageal reconstruction: Salvage with intestinal flaps. *Microsurgery* 36: 567-72.
3. Butskiy O, Anderson DW, Prisman E (2016) Management algorithm for failed gastric pull up reconstruction of laryngopharyngectomy defects: Case report and review of the literature. *J Otolaryngol Head Neck Surg* 45:41.
4. Uchida Y, Tomonari K, Murakami S, Hadama T, Shibata O, et al. (1987) Occurrence of peptic ulcer in the gastric tube used for esophageal replacement in adults. *Jpn J Surg* 17: 190-4.
5. Ubukata H, Nakachi T, Tabuchi T, Nagata H, Takemura A, et al. (2011) Gastric tube perforation after esophagectomy for esophageal cancer. *Surg Today* 41: 612-9.
6. Park S, Kim JH, Lee YC, Chung JB (2010) Gastropericardial fistula as a complication in a refractory 135 gastric ulcer after esophagogastrectomy with gastric pull-up. *Yonsei Med J* 51: 270-2.
7. Kim WJ, Choi EJ, Oh YW, Kim KT, Kim CW (2006) A case of successful embolotherapy for gastric ulcer bleeding from the intercostal artery after oesophagectomy and gastric reconstruction. *Br J Radiol* 79: e96-8.
8. Steinemann DC, Schiesser M, Clavien PA, Nocito A (2011) Laparoscopic gastric pouch and remnant resection: a novel approach to refractory anastomotic ulcers after Roux-en-Y Gastric Bypass: Case report. *BMC Surg* 11:33.

Submit your next manuscript to Annex Publishers and benefit from:

- ▶ Easy online submission process
- ▶ Rapid peer review process
- ▶ Online article availability soon after acceptance for Publication
- ▶ Open access: articles available free online
- ▶ More accessibility of the articles to the readers/researchers within the field
- ▶ Better discount on subsequent article submission

Submit your manuscript at
<http://www.annexpublishers.com/paper-submission.php>