

# Post-Thymectomy Onset of Morvan Syndrome in a Patient with Preexisting Isaac's Syndrome: A Case Report and Literature Review

Nithisha Thatikonda<sup>1,\*</sup>, Fnu Komal<sup>2</sup>

<sup>1</sup>Department of Neurology, University of Texas Medical Branch Galveston, Texas, 77555, United States of America

<sup>2</sup>Assistant professor, Department of Neurology, University of Texas Medical Branch Galveston, Texas, 77555, United States of America

\***Corresponding Author:** Nithisha Thatikonda, PGY-3, Department of Neurology, University of Texas Medical Branch Galveston, Texas, 77555, United States of America, Tel.: 409-919-0428, E-mail: nithatik@utmb.edu

**Citation:** Nithisha Thatikonda, Fnu Komal (2024) Post-Thymectomy Onset of Morvan Syndrome in a Patient with Preexisting Isaac's Syndrome: A Case Report and Literature Review, J Neurol Neurol Disord 10(2): 203

**Received Date:** November 26, 2024 **Accepted Date:** December 26, 2024 **Published Date:** December 30, 2024

## Abstract

Anti-voltage-gated potassium channel (VGKC) complex antibodies are associated with a spectrum of neurological disorders involving both the peripheral and central nervous systems. Isaacs' syndrome predominantly manifests with peripheral symptoms such as neuromyotonia due to peripheral nerve hyperexcitability. In contrast, Morvan syndrome encompasses a combination of neuromyotonia, encephalopathy, and autonomic dysfunction. Anti-VGKC complex antibody disorders are often paraneoplastic, with thymoma detected in approximately one-third of cases. Thymectomy is the standard treatment in such cases. We present the case of a 49-year-old female who experienced muscle spasms and twitches in all four extremities for three years. Electromyography revealed neuromyotonia. Serum analysis confirmed the presence of anti-VGKC complex antibodies, establishing the diagnosis of Isaacs' syndrome. Further investigation uncovered a type B3 thymoma, and the patient subsequently underwent thymectomy. Unexpectedly, one week after thymectomy, the patient developed Morvan syndrome, presenting with new-onset encephalopathy and autonomic dysfunction. These symptoms were successfully managed with plasmapheresis. This case is noteworthy as it highlights a potential link between thymectomy and the emergence of Morvan syndrome, suggesting that thymectomy may exacerbate or trigger this condition in certain patients. While the underlying mechanism remains unclear, this observation underscores the importance of careful patient selection, thorough preoperative counseling, and vigilant postoperative monitoring. To provide further context, we include a comprehensive literature review of studies reporting the development of Morvan syndrome following thymectomy. This analysis aims to enhance understanding of the potential risks and outcomes associated with thymectomy in the context of anti-VGKC complex antibody disorders.

**Keywords:** Anti- voltage-gated potassium channel complex antibodies; Isaacs' syndrome; Morvan syndrome; Thymectomy; Neuromyotonia; Plasmapheresis

**List of Abbreviations:** VGKC: voltage-gated potassium channel; CASPR2-Ab: contactin-associated protein-like 2 antibodies; LGI1-Ab: leucine-rich glioma inactivated protein 1 antibodies; EMG: electromyography; IVIG: intravenous immunoglobulin; EEG: Electroencephalogram

## Introduction

Anti-voltage-gated potassium channel (VGKC) complex antibodies, such as contactin-associated protein-like 2 antibodies (CASPR2-Ab) and leucine-rich glioma inactivated protein 1 antibodies (LGI1-Ab), have been linked to a range of neurological symptoms affecting both the peripheral and central nervous systems [1]. CASPR2 is expressed predominantly in the peripheral nervous system, whereas LGI1 is found predominantly in the central nervous system.

The pathophysiology centers on the disruption of voltage-gated potassium channel (VGKC) function, leading to increased nerve excitability and repetitive discharges in peripheral nerves [2]. When VGKC antibodies bind to these channels, they interfere with proper repolarization of the nerve, causing prolonged depolarization of the nerve membrane and heightened nerve excitability. This disruption also affects neurotransmitter release at the neuromuscular junction, contributing to abnormal electrical activity, muscle contractions, and related symptoms [2-4].

CASPR2, a transmembrane cell adhesion protein of the neurexin superfamily, regulates the localization of Kv1.1 and Kv1.2 VGKC subunits at the juxtaparanodal region of myelinated axons, which is essential for proper electrical conduction [2, 5]. The production of CASPR2 auto-antibodies disrupts this function, leading to peripheral nervous system hyperexcitability. This manifests clinically as painful muscle cramps, myokymia, and neuromyotonia, collectively known as Issac's syndrome.

LGI1 is a secreted cell surface protein complex predominantly expressed in the cornu ammonis (CA) 1 and 3 regions of the hippocampus, as well as the diencephalon and brainstem [2, 6]. The monoaminergic nuclei within the diencephalon and brainstem play a crucial role in regulating arousal and autonomic homeostasis. The production of LGI1 auto-antibodies disrupts synaptic function and neurotransmitter release, leading to disturbances in arousal and autonomic homeostasis. This results in a range of central nervous system manifestations, including insomnia, confusion, behavioral changes, myoclonus, hallucinations, and encephalopathy [2, 7]. Additionally, dysautonomia may develop, likely originating in the hypothalamus and raphe nuclei, and presenting as hyperhidrosis, constipation, labile blood pressure, hemodynamic instability, and cardiac arrhythmias [2, 7]. In Morvan syndrome, both LGI1 and CASPR2 auto-antibodies are present giving rise to both central and peripheral nervous system manifestations.

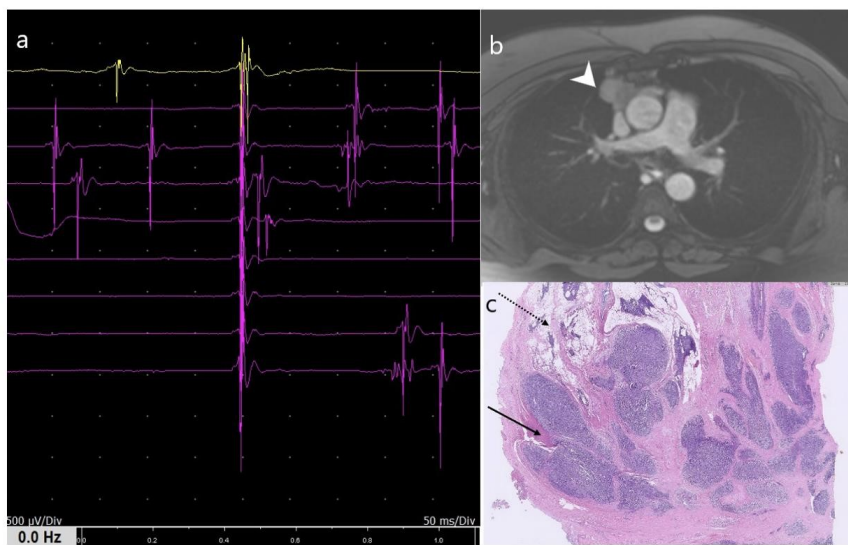
Anti-VGKC complex antibody disorders are often paraneoplastic, with thymoma present in roughly one-third of cases [1, 8-9]. Although thymectomy remains the standard treatment, some studies report that post-thymectomy patients experience either worsening of Morvan syndrome or, in some instances, new onset of the condition [10-16]. In this report, we discuss a notable case of Isaacs syndrome that progressed to Morvan syndrome following thymectomy. Alongside this case, we aim to deliver an extensive literature review on studies that highlight the development of Morvan syndrome in patients post-thymectomy, thereby enhancing our understanding of post-thymectomy outcomes.

## Case Description

A 49-year-old Caucasian woman with past medical history of stage 2 breast cancer s/p mastectomy and sarcoidosis presented with pain and muscle twitches in all four limbs, along with leg muscle spasms and cramps that had begun 2-3 years before this presentation. She reported no sensory symptoms, cognitive changes, or sphincter dysfunction. Neurological examination revealed normal mental status and cranial nerve function, with no muscle bulk abnormalities. However, frequent muscle twitches were observed in her limb muscles, and she displayed poor muscle relaxation in her arms and legs without clear signs of spasticity or rigidity. Sensory examination was normal, deep tendon reflexes were 2+ throughout, and her gait was slightly stiff and antalgic. Romberg's test was negative. Based on the clinical presentation and examination, peripheral nerve hyperexcitability syndromes, including cramp fasciculation syndrome, Isaac's syndrome, and Morvan syndrome, were considered the top differential diagnoses. Muscle disorders characterized by stiffness, such as Schwartz-Jampel syndrome, rippling muscle disease, and stif-

f-person syndrome, were also evaluated as potential considerations.

Electromyography (EMG) showed myokymic discharges in the form of doublets, as well as fasciculations in all limbs (Figure 1a). Serum analysis indicated positive LGI1 (1:640, reference range <1:10) and CASPR2 antibodies (>1:2560, reference range <1:10), subtypes of VGKC complex detected through indirect immunofluorescence assay, confirming the diagnosis of Isaacs syndrome. Treatment was initiated with a 5-day course of intravenous immunoglobulin (IVIg) at 0.4 mg/kg/day alongside carbamazepine. A thorough search for underlying neoplasms was conducted. Thoracic CT revealed an anterior mediastinal mass measuring 29 x 25 x 46 mm<sup>3</sup>, consistent with a thymoma (Figure 1b). She was diagnosed with type B3 thymoma with invasion into surrounding structures per the Masaoka staging system, and thymectomy was performed two weeks later, involving resection of the mediastinal pleura and pericardium, which pathologically revealed a type B3 thymoma according to the World Health Organization criteria (Figure 1c). Concurrent myasthenia gravis was ruled out with negative anti-acetylcholinesterase antibodies.



**Figure 1:** An EMG study of left biceps muscle showing fasciculations and doublets. Note the same unit, firing repeatedly (a). Chest contrast-enhanced MRI showing a thymoma (b, arrowhead). Histopathological findings of thymoma abundant lymphocytes and neoplastic epithelial cells invading into surrounding mediastinal structures (c, solid arrow) and normal thymic tissue (c, dotted arrow).

One-week post-thymectomy, the patient developed new symptoms, including confusion, memory disturbances, visual hallucinations, insomnia, diaphoresis, and labile blood pressure. She continued to display fasciculations and myokymia upon examination. Electroencephalogram (EEG) findings showed moderate diffuse encephalopathy. Given the onset of neuropsychiatric and autonomic symptoms alongside peripheral neuromyotonia, she was diagnosed with Morvan syndrome in a post-thymectomy patient with preexisting Isaac's syndrome. Treatment with a 5-day course of plasmapheresis was administered, resulting in gradual symptom improvement over the following two weeks. The patient was discharged from the hospital four weeks after thymectomy. At her two-month follow-up, her muscle twitches had improved, though she still experienced intermittent confusion. Repeat anti-VGKC antibody titers were negative; LGI1 was 1:5 (reference range <1:10) and CASPR2 was 1:1 (reference range <1:10), indicating disease remission.

## Discussion

Anti-VGKC complex antibody-mediated disorders exhibit a broad range of neurological symptoms affecting both the peripheral and central nervous systems. These include Isaacs syndrome, marked by peripheral nerve hyperexcitability, and Morvan syn-

drome, which is characterized by a combination of peripheral nerve hyperexcitability, encephalopathy, and autonomic dysfunction [1, 8]. The presence of anti-LGI1 antibodies is often linked to neuropsychiatric symptoms, while anti-CASPR2 antibodies are known to be paraneoplastic, mostly secondary to thymoma or small cell lung cancer [1, 8]. Nevertheless, both anti-LGI1 and anti-CASPR2 antibodies can be positive in cases of Isaacs or Morvan syndrome [1, 11].

Our patient initially presented with diffuse fasciculations and myokymia, along with positive anti-VGKC complex antibodies, leading to a diagnosis of Isaacs syndrome. Shortly after undergoing thymectomy, the patient developed central nervous system symptoms, including confusion, hallucinations, agitation, and insomnia, as well as dysautonomia symptoms characteristic of Morvan syndrome. Plasmapheresis was subsequently administered, resulting in symptom improvement. Morvan syndrome occurs as a paraneoplastic process in up to one-third of cases, most often linked to thymoma and, less commonly, small cell lung cancer [1]. Thymectomy is the standard treatment, though some studies indicate that post-thymectomy patients may experience worsening or even new onset of Morvan syndrome (10-16). Similar to our patient, one recent study documented a 49-year-old Japanese male with Isaacs syndrome who, after thymectomy, developed Morvan syndrome two months later [11]. Other reports also note symptom exacerbation following thymectomy in Morvan syndrome cases [10, 12].

This phenomenon is not exclusive to peripheral hyperexcitability syndromes. Thymoma is also associated with a broad range of autoimmune paraneoplastic syndromes (PNSs) like myasthenia gravis, limbic encephalitis, good's syndrome, autoimmune thyroid disorders, autoimmune hepatitis, and various cutaneous autoimmune diseases [14]. In many cases, patients with these autoimmune PNSs developed typical Morvan syndrome symptoms post-thymectomy [13-16]. Table 1 summarizes studies reporting onset/worsening of Morvan syndrome after thymectomy.

**Table 1:** Case studies which reported post-thymectomy onset of Morvan syndrome.

Case	Age/Sex	Indication for thymectomy	Stage	Interval between thymectomy and onset/worsening of Morvan syndrome	Treatment received	Improvement in symptoms (in days)
Our case	42/F	Issac's syndrome	3B	1 week	PLEX	2 weeks
Suzuki et al. <sup>11</sup>	49/M	Issac's syndrome	2B	8 weeks	mPSL, PLEX	4 weeks
Cottrell DA et al. <sup>10</sup>	70/M	Thymoma	NA	6 weeks	mPSL, PLEX	2 weeks
Maskery M et al. <sup>12</sup>	74/M	Morvan syndrome	AB	1 week	mPSL, PLEX, IVIG, azathioprine	12 weeks
Oh S et al. <sup>13</sup>	67/M	Myasthenia gravis	NA	16 weeks	Gabapentin, carbamazepine	No improvement, palliative care
Liu H et al. <sup>14</sup>	49/M	Myasthenia gravis	2B	24 weeks	IVIG, Rituximab	4 weeks
Galie E et al. <sup>15</sup>	35/M	Thymoma	4A	4 weeks	IVIG	NA

Banks KC et al. <sup>16</sup>	40/M	Thymoma	3B	NA	IVIG, Rituximab	NA
-------------------------------------	------	---------	----	----	-----------------	----

Abb: PLEX- plasmapheresis; mPSL-methylprednisolone; IVIG-intravenous immunoglobulins.

The mechanisms underlying the development of Morvan syndrome following thymectomy remain unclear. One hypothesis suggests that thymectomy might expose hidden antigens or alter the immune environment, leading to elevated levels of pathogenic antibodies such as anti-LGI1 and anti-CASPR2 [10, 12]. Previous literature reports indicate that low titers (< 1:400) of anti-VGKC antibodies are associated with peripheral nervous system manifestations, whereas higher titers are typically observed in Morvan syndrome [9, 10]. Therefore, it is plausible to hypothesize that thymectomy could trigger the release of anti-VGKC antibodies during the procedure, resulting in elevated serum antibody titers and subsequently leading to the onset of Morvan syndrome. Therefore, when selecting candidates for thymectomy, it may be advisable to prioritize patients with low antibody titers or to reduce antibody levels through immunotherapy prior to the surgery."

Additionally, the thymus plays a critical role in immune regulation, and its removal could disrupt immune tolerance, potentially increasing autoantibody production [10, 12].

While it's unclear if thymectomy directly triggers new or worsened cases of Morvan syndrome, published case reports indicate that this risk cannot be ignored. Patients should be informed of the potential for developing or worsening Morvan syndrome symptoms post-thymectomy. Clinicians should remain vigilant, as symptoms in preexisting cases may intensify or new cases may emerge, potentially requiring repeated immunotherapy and ICU support. Early identification and treatment with immunotherapies, such as plasmapheresis or intravenous immunoglobulin, can improve outcomes and help prevent severe complications.

## Conclusions

Peripheral hyperextensibility syndromes are often associated with paraneoplastic processes. However, the presence of an existing cancer, such as breast cancer in our patient, should not prevent further investigation for an additional underlying tumor. In this case, the peripheral hyperextensibility syndrome was linked to a thymoma rather than the pre-existing breast cancer. While thymectomy is the standard treatment for thymoma-associated conditions, there is evidence suggesting it may precipitate or worsen Morvan syndrome in some patients. The exact mechanism remains unclear, but the potential risk underscores the need for careful patient selection, thorough preoperative discussions, and vigilant postoperative care.

## Acknowledgments

None

## Financial Disclosures

Authors declare that they have no conflicts of interest

## References

1. Sawlani K, Katirji B (2017) Peripheral Nerve Hyperexcitability Syndromes. *Continuum (Minneapolis, Minn)* 23: 1437-50.
2. Masood W (2024) *Morvan Syndrome*, Treasure Island (FL): StatPearls Publishing, NIH, USA
3. Paterson RW, Zandi MS, Armstrong R, Vincent A, Schott JM (2014) Clinical relevance of positive voltage-gated potassium channel (VGKC)-complex antibodies: experience from a tertiary referral centre. *J Neurol Neurosurg Psychiatry*, 85: 625-30.
4. Liguori R, Vincent A, Clover L, Avoni P, Plazzi G et al. (2001) Morvan's syndrome: peripheral and central nervous system and cardiac involvement with antibodies to voltage-gated potassium channels. *Brain*, 124: 2417-26.
5. Comperat L, Pegat A, Honnorat J, Joubert B (2022) Autoimmune neuromyotonia. *Curr Opin Neurol*, 35: 597-603.
6. Ramirez-Franco J, Debreux K, Extremet J, Maulet Y, Belghazi M et al. (2022) Patient-derived antibodies reveal the subcellular distribution and heterogeneous interactome of LGI1. *Brain*, 145: 3843-58.
7. Ludewig S, Salzburger L, Goihl A, Rohne J, Leyboldt F et al. (2023) Antibody Properties Associate with Clinical Phenotype in LGI1 Encephalitis. *Cells*, 12: 282.
8. Ma D, Xiang Q, Mo Z, Du Q, Tang Y et al. (2024) A case series: Three cases of Morvan's syndrome as a rare autoimmune disorder with anti-Caspr2 antibody. *Medicine (Baltimore)*, 103: e40159.
9. Fleisher J, Richie M, Price R, Scherer S, Dalmau J et al. (2013) Acquired neuromyotonia heralding recurrent thymoma in myasthenia gravis. *JAMA Neurol*, 70: 1311-4.
10. Cottrell DA, Blackmore KJ, Fawcett PR, Birchall D, Vincent A et al (2004) Sub-acute presentation of Morvan's syndrome after thymectomy. *J Neurol Neurosurg Psychiatry*, 75:1504-5.
11. Suzuki D, Suzuki Y, Sato D, Kikuchi K, Kanauchi N et al. (2022) Morvan Syndrome Converted from Isaacs' Syndrome after Thymectomy with Positivity for Both Anti-LGI1 and Anti-CASPR2 Antibodies. *Intern Med*, 61:1443-5.
12. Maskery M, Chhetri SK, Dayanandan R, Gall C, Emsley HC (2016) Morvan Syndrome: A Case Report with Patient Narrative and Video. *Neurohospitalist*, 6: 32-5.
13. Seong-il Oh, Mi-Ri Kang, Ki-Hwan Ji (2022) Morvan syndrome presenting with agrypnia excitata in post-thymectomy myasthenia gravis: a case report. *J Neurocrit Care*, 15: 57-60.
14. Liu H, Dong Z, Zhang M, Pang R, Xu J et al. (2022) Case report: Complex paraneoplastic syndromes in thymoma with nephrotic syndrome, cutaneous amyloidosis, myasthenia gravis, and Morvan's syndrome. *Front Oncol*, 12: 1002808.
15. Galié E, Renna R, Plantone D, Pace A, Marino M et al. (2016) Paraneoplastic Morvan's syndrome following surgical treatment of recurrent thymoma: A case report. *Oncol Lett*, 12: 2716-9.
16. Banks KC, Hsu DS, Velotta JB (2022) Extrapleural pneumonectomy for recurrent thymoma diagnosed after return of paraneoplastic Morvan syndrome. *J Surg Case Rep*, 2022: rjab636.

Submit your next manuscript to Annex Publishers and benefit from:

- ▶ Easy online submission process
- ▶ Rapid peer review process
- ▶ Online article availability soon after acceptance for Publication
- ▶ Open access: articles available free online
- ▶ More accessibility of the articles to the readers/researchers within the field
- ▶ Better discount on subsequent article submission

Submit your manuscript at

<http://www.annexpublishers.com/paper-submission.php>