

Should Asymptomatic Urachal Remnants in Adults Be Excised? a Scoping Review

Arya Bahadori^{1*}, Gerard Bray²

¹Royal Brisbane and Women's health Hospital, Brisbane, Queensland, Australia

²Redcliffe Hospital, Redcliffe, Queensland, Australia

***Corresponding Author:** Arya Bahadori, Royal Brisbane and Women's health Hospital, Brisbane, Queensland, Australia, E-mail: arya.bahadori@health.qld.gov.au

Citation: Arya Bahadori, Gerard Bray (2025) Should Asymptomatic Urachal Remnants in Adults Be Excised? a Scoping Review, J Surg Oper Care 10(1): 101

Received Date: April 02, 2025

Accepted Date: April 15, 2025

Published Date: April 19, 2025

Abstract

Introduction: Historical approaches to managing urachal anomalies in adult patients have shown a lack of definitive consensus between conservative and surgical management strategies. Our objective was to assess and consolidate existing literature regarding the diagnosis and treatment of asymptomatic urachal anomalies in adult patients.

Methods: We performed a scoping literature review of PubMed/Medline and WebOfScience from conception to August 2023.

Results: 6 publications were selected for inclusion in this analysis. 738 unique studies were identified with 6 studies meeting inclusion criteria. There were a total of 60 patients, 16 underwent conservative management and 44 had surgical excision using different techniques including open, laparoscopic, and robotic assisted. Only 1 patient had adenocarcinoma while the rest of the histology were benign. None of the patients with conservative treatment went on to develop adenocarcinoma.

Conclusions: Once meticulously conducted prospective studies identify statistically significant patient factors that indicate the need for surgical intervention over observation, it may become feasible to establish treatment algorithms.

Keywords: Urachal Remnant; Urachal Sinus; Urachal Cyst; Patent Urachus; Urachal Diverticulum

Abbreviations: UA: Urachal Anomaly; US: Ultrasound; CT: Computed Tomography; MRI: Magnetic Resonance Imaging; Urc: Urachal Carcinoma

Introduction

In early stages of embryonic development, the urinary bladder is continuous with the allantois, which is a tubular structure that links the foetal bladder to the umbilical cord for drainage. Normally, the urachal canal, which is a part of the allantois, closes as the bladder moves down into the foetal pelvis. It forms a fibrous connection with the front wall of the abdomen, known as the median umbilical ligament. This closure process typically happens during late foetal development or in the early months of infancy (<6-months) [1].

If the urachal closure process doesn't occur as expected, it can lead to four different embryonic malformations: a patent urachus, an umbilical-urachal sinus, a vesicourachal diverticulum, or a urachal cyst. A patent urachus means that the urachal canal remains open and allows the bladder to drain into the umbilicus. Individuals with an umbilical-urachal sinus have a single blind opening that may connect to the umbilicus. In the case of a vesicourachal diverticulum, urachal tissue remains open at the lower end and creates a pouch-like structure on the top of the urinary bladder. Failure of the urachal obliteration process can result in the presence of a retained urachal cyst along the median umbilical ligament (Figure 1)[2].

Many of these conditions can be diagnosed during early infancy. By the age of two, about 80% of these defects resolve on their own. However, in some cases, they may persist and require surgical intervention due to recurrent infections related to urachal remnants. When patients become symptomatic, they may experience symptoms such as fever, discharge from the umbilicus, and a tender mass below the navel. Although rare, urachal remnants may go unnoticed until adulthood and present with abdominal symptoms that resemble appendicitis, Meckel's diverticulum, or a hernia. In such cases, abdominal Ultrasound (US) or Computed Tomography (CT) imaging is useful for identifying urachal abnormalities and understanding their relationship with the urinary bladder and nearby structures [3].

Urachal remnant has the potential of malignant transformation to adenocarcinoma. Although usually asymptomatic, the urachal remnant may be associated with an increased risk of urinary tract infections, intraurachal stone formation, and an increased prevalence of carcinoma after puberty. There are no set guidelines regarding management of urachal remnants but when symptomatic, surgical management is warranted [4]. There are also no established guidelines surrounding surveillance or management of asymptomatic urachal remnants which are found incidentally. In this study, we aim to review the literature and identify current management strategies for adult patients with asymptomatic urachal remnants.

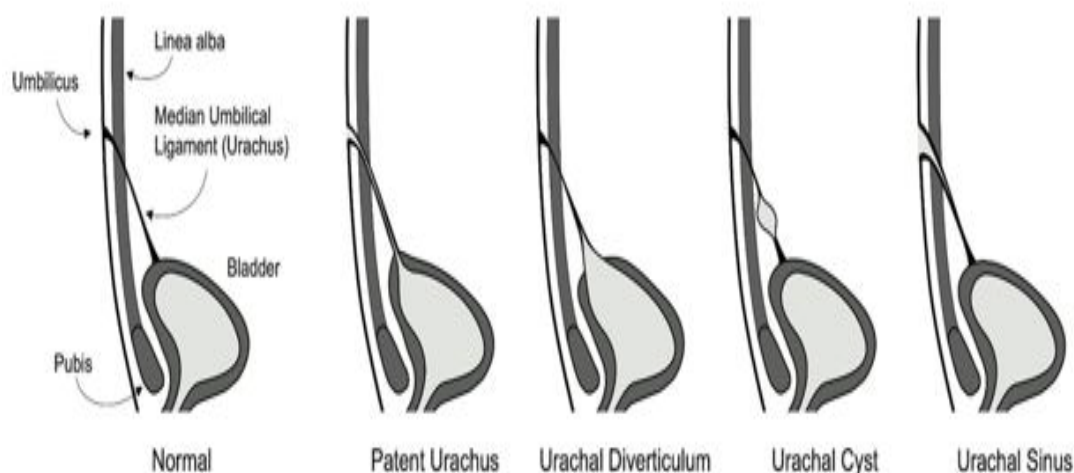


Figure 1: Illustration of a normal fully developed bladder with urachus and four of the most common urachal anomaly subtypes including patent urachus, vesicourachal diverticulum, urachal cyst, and umbilical-urachal sinus.

Material and Methods

We carried out a literature review using the databases Pub-Med (MEDLINE), Scopus and Web of Science. The literature review search process was undertaken by A.B. The following key words; “urachal remnant” or “excision” or “asymptomatic” or “urachal adenocarcinoma” or “allantoic remnant” or “Urachal cyst” were used to extract relevant papers. Timeframe was from database conception to August 2023. The included articles’ reference list were also examined for additional relevant papers.

Inclusion/Exclusion Criteria

Two authors independently extracted the data into Microsoft Excel. Studies were included if they reported on a case of excision of asymptomatic urachal remnant in adults. Duplicates and papers in Non- English languages were then removed. Symptomatic urachal remnants such as infected cysts were excluded. Published original research was analysed to evaluate diagnosis and management of urachal anomaly in adult patients. Of the 430 studies identified through the initial literature search 6 were included in this review as seen in figure 2.

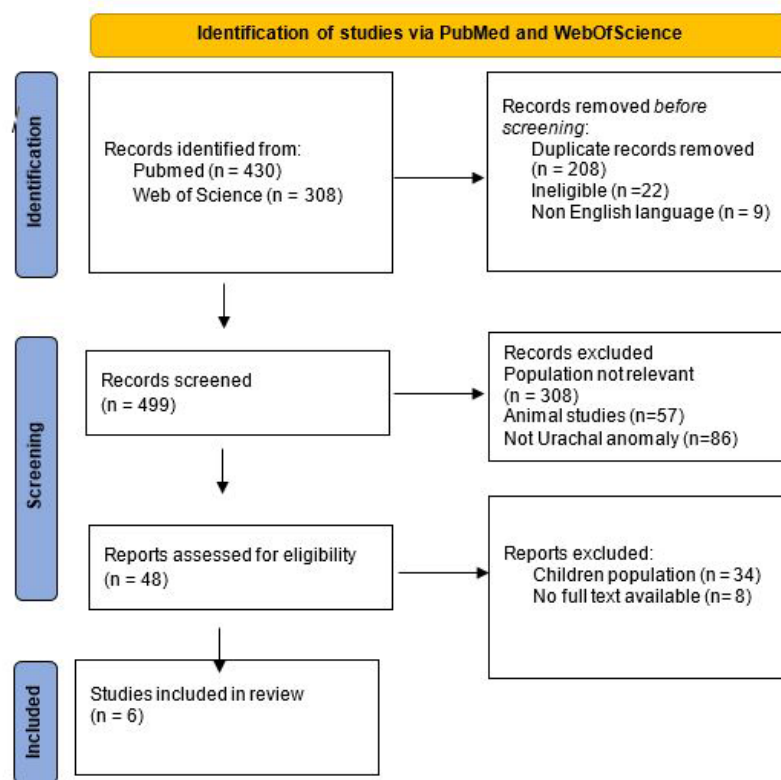


Figure 2: Flowchart of identification, screening, eligibility, and inclusion in final analysis

Results

A retrospective analysis was conducted by Hassabhai et al on the medical records and imaging data of 45 patients, with a mean age of 54.6 years and an average age of 54.6 years (ranging between 17-90 years old), who were diagnosed with urachal anomalies at a single urology tertiary centre between January 2005 and December 2016. The study assessed patients who underwent surgical treatment and those managed non-surgically, with an average follow-up period of 31 months. The majority of the cases were incidental findings reported in 30 (66.7%) patients. Of those that were symptomatic, the most common feature was haematuria (n= 5, 11.1%). All incidental findings were diagnosed with either ultrasound or CT scan. In the asymptomatic cohort, 22 patients had a urachal remnant, 5 patients had a urachal cyst and 1 patient with a urachal mass concerning for adenocarcinoma who underwent partial cystectomy. Three asymptomatic patients underwent cystoscopy had bladder biopsies done as nodular lesions (n= 2) or cys-

tic structures (n= 1) were seen. In all three cases, initial histology revealed cystitis, but only the latter underwent surgery in the form of partial cystectomy, with final histology showing cysts in the mucosa and muscularis consistent with a urachal remnant [5].

No immediate complications following surgery or instances of bladder leaks were reported. Among the 25 patients who underwent repeated imaging, the urachal anomalies remained unchanged. The average and median follow-up durations were 31 and 26 months, respectively. The longest follow-up period recorded was 7.6 years, with 17 patients being monitored for at least 2 years. Patients received follow-up care with repeated ultrasound scans every 6 to 12 months. The study acknowledged limitations including the small sample size, limited follow-up duration, and the retrospective design [5].

Ashley et al. conducted one of the largest retrospective studies to date focusing on urachal anomalies, involving 176 patients observed between 1951 and 2005. Among these patients, urachal remnants were detected in 130 adults (86 men and 44 women). Adults presented at a median age of 54.5 years (range 17 to 89 years old). The most prevalent urachal lesion observed among these adults was urachal carcinoma (UrC), identified in 66 cases (51%). Twenty-three patients (13%) were incidentally discovered through imaging or intraoperative findings. Twelve patients had conservative management and eleven underwent surgical excision. All asymptomatic patient who underwent surgical excision had benign histology. For adults diagnosed with benign lesions for conservative management, the median follow-up period was also 2.8 years (ranging from 1 month to 44 years) [6].

Garcia et al. performed a retrospective analysis of all patients diagnosed with various types of urachal remnants at Nuestra Señora de Candelaria University Hospital in Tenerife, Spain, between 2006 and 2020. The study included twenty-three cases of urachal pathology. The average age at presentation was 32 years, ranging from birth to 78 years. Among the patients, 73.9% (17/23) were male, and 26.1% (6/23) were female. A majority of cases, 65% (15/23), were diagnosed in adults aged over 18 years, with 40% (6/15) of these cases being incidental findings [7].

The primary diagnostic modalities utilised were abdominal ultrasound and CT scans, each employed in 43% of cases, with both tests being combined in two cases. Other diagnostic combinations included US with magnetic resonance imaging, and CT with cystoscopy. The most common clinical diagnosis was urachal cyst, accounting for 60.9% of cases. Adenocarcinoma was only clinically suspected in one case (0.04%), with uncertainty regarding a differential diagnosis with urachal diverticulum [7].

Among the six asymptomatic patients, one was female (16.6%) and five were male (83.4%), ranging in age from 29 to 75 years. Four patients were diagnosed with a urachal cyst, one with a patent urachus, and one with a urachal diverticulum. Only one patient underwent cystoscopy, while four patients underwent CT scans, and one patient underwent both CT and abdominal US. Three patients were managed conservatively, while one underwent partial cystectomy, and one underwent laparoscopic excision of the urachal remnant, with inconclusive histology results. None of the asymptomatic patients who underwent surgery were found to have malignancy [7].

There were also 3 case reports of simple urachal cysts in asymptomatic adults, and they were all excised laparoscopically. A 38-year-old Chilean man with incidental finding of a 1.9 cm cystic lesion during a routine abdominal ultrasound. Subsequent abdominal CT-scan identified a 2 cm calcified nodule on the bladder dome. The patient opted for surgery. The laparoscopic excision lasted 75 minutes, and he was discharged from the hospital on the fifth day after surgery. The final pathological analysis confirmed the presence of a non-complicated partially calcified urachal cyst. During an 8-month follow-up, there was no recurrence or complication [8].

A 32-year-old female was unexpectedly diagnosed with an asymptomatic urachal cyst during pregnancy through a routine ultrasound. The cyst was monitored for 12 months, maintaining a consistent size of 1.5 x 1.5 cm. She underwent laparoscopic excision with operating time of 160 minutes. She was discharged day 6 with no complication. The histology showed a benign urachal cyst [9].

Similarly, another 32-year-old female from Spain was incidentally found to have a urachal remnant during routine ultrasound during pregnancy. She also underwent laparoscopic excision with benign histology [10].

Discussions

The current literature with regards to management of asymptomatic urachal anomalies in adulthood is limited. There is a lot more extensive data available for those detected in children and symptomatic adults. However regardless of age, there is no conclusive consensus on management of urachal remnants specially those diagnosed incidentally.

Urachal anomalies are thought to be associated with an increased risk of bladder adenocarcinoma in adults, and urachal adenocarcinoma has an estimated incidence of 0.18 per 100,000 individuals yearly. These cases account for 0.1% to 0.3% of all bladder malignancies and 20% to 39% of bladder Adenocarcinomas. The natural history of asymptomatic urachal anomalies is unknown. However, a study from the Mayo Clinic postulated that urachal lesions can provide a source of chronic infection/ inflammation, often associated with a carcinogenic state if left untreated [11].

Originally, it was believed that the obliteration of the urachus occurred exclusively during prenatal development, and any persistence of this structure was considered abnormal. Early reports from the 1970s recommended removing all remnants of the urachus, even if found incidentally, as it was thought to pose risks of infection or cancer later on in life. This recommendation persisted into the early 2000s, where surgical removal was advised regardless of symptoms. Even in 2006, Choi et al. advocated for surgical resection irrespective of symptoms due to the perceived risks of infection or cancer development [12].

However, in recent decades, the increased use of advanced imaging techniques, like ultrasound and CT, has led to more incidental diagnoses of urachal anomalies. These studies have shown that many urachal anomalies are asymptomatic and carry a low risk of cancer. Studies in the late 1990s and early 2000s showed spontaneous involution of urachal remnants in newborns and young children, leading to a shift towards conservative management. By 2003, recommendations for non-invasive management for both symptomatic and asymptomatic cases were being made. However, in subsequent years, there were conflicting recommendations regarding management, with some advocating for surgical removal and others for conservative approaches. From 2010 onwards, there has been a focus on reconciling these inconsistencies in management recommendations. Recent studies consistently support conservative management for asymptomatic cases [13].

Further research has shown that urachal remnants typically have benign pathological findings, and the risk of adenocarcinoma formation is low, Gleason et al reporting the number needed to be excised to prevent a single case of urachal adenocarcinoma was 5721. Therefore, conservative observation is often recommended. Laparoscopic and robotic approaches have emerged as safe and effective alternatives to open surgery, offering cosmetic benefits [11].

Overall, the management of urachal anomalies involves a balance between conservative and surgical approaches, with no clear guidelines on when to transition from conservative to surgical management.

There has not been a comprehensive review on urachal anomalies thus far. This review highlights recent trends favouring non-surgical approaches for asymptomatic adult patients given low risk of malignancy. However, there's insufficient evidence to confirm if this management preference applies universally, regardless of factors such as the type of UA, gender, or specific age. We currently lack the ability to identify specific patient profiles that might necessitate surgical intervention. Due to this lack of clarity, it is challenging to establish clear criteria for determining which patients should undergo surgery and which ones should be monitored without intervention.

Furthermore, the absence of randomised controlled trials and prospective studies in the existing literature makes it difficult to establish an optimal conservative management strategy along with appropriate follow-up timelines. Therefore, conducting a large-

scale, multi-site prospective study that examines demographic data, UA subtypes alongside various treatment protocols is necessary to determine the most effective approach for managing this condition.

Conclusions

Based on the available data patients who underwent excision of their urachal anomaly all had benign histology and patients who underwent surveillance were not found to have malignant transformation however longer surveillance period in these studies are recommended. Although rare, urachal remnants have potential for malignant transformation most commonly adenocarcinoma. Urachal cancers are usually locally advanced tumours at diagnosis. There is a paucity of data available on the management of urachal remnants in the adult population. Without sufficient data from prospective studies, the authors are unable to provide a worthwhile management algorithm.

Acknowledgement

This research did not receive any specific grant from funding agencies in the public, commercial, or not-for-profit sectors.

References

1. Ueno T, Hashimoto H, Yokoyama H, Ito M, Kouda K, et al. (2003) Urachal anomalies: Ultrasonography and management. *J Pediatr Surg*, 38: 1203-7.
2. Blichert-Toft M, Nielsen OV (1971) Congenital patent urachus and acquired variants. diagnosis and treatment. Review of the literature and report of five cases. *Acta Chir Scand*, 137: 807-14.
3. Schubert GE, Pavkovic MB, Bethke-Bedurftig BA (1982) Tubular urachal remnants in adult bladders. *J Urol*, 127: 40-2.
4. Szarvas T, Módos O, Niedworok C, Reis H, Szendrői A, et al. (2016) Clinical, prognostic, and therapeutic aspects of urachal carcinoma—a comprehensive review with meta-analysis of 1,010 cases. *Urol Oncol*, 34: 388-98.
5. Hassanbhai D, Ng F, Koh L (2018) Is excision necessary in the management of adult urachal remnant?:a 12-year experience at a single institution. *Scand J Urol*, 52: 432-6.
6. Ashley R, Inman B, Routh J (2007) Urachal anomalies:A longitudinal study of urachal remnants in children and adults. *J Urol*, 178: 1615-8.
7. Garcia L, Ballesto B, Talavera J (2022) *Urol int*, 106: 195-8.
8. Castillo OA, Vitagliano G, Olivares R, Sanchez-Salas R (2007) Complete excision of urachal cyst by laparoscopic means: a new approach to an uncommon disorder. *Arch Esp Urol*, 60: 607-11.
9. Permpongkosol S, Bella AJ, Suntiseevee S, Leenanupunth C, Stoller ML (2011) Laparoscopic excision of urachal cysts in elderly men and woman following pregnancy. *J Med Assoc Thai*, 93: 132.
10. Donate Moreno MJ, Giménez Bachs JM, Salinas Sánchez AS, Lorenzo Romero JG, Millán H, et al. (2005) Urachal pathology: an overview review and report of three clinical cases. *Actas Urol Esp*, 29: 332-6.
11. Gleason JM, Bowlin PR, Bagli DJ, Lorenzo AJ, Hassouna T, et al. (2015) A comprehensive review of pediatric urachal anomalies and predictive analysis for adult urachal adenocarcinoma. *J Urol*, 193: 632-6.
12. Ghattas Y, Gelikman D, Ibanez K, Ellsworth P, Seth A (2023) *Front. Urol*, 1159439.
13. Orbatu D, Alaygut D (2020) Evaluation and management of urachal remnants in children. *Pediatr Int*, 62: 1158-61.

Submit your next manuscript to Annex Publishers and benefit from:

- ▶ Easy online submission process
- ▶ Rapid peer review process
- ▶ Online article availability soon after acceptance for Publication
- ▶ Open access: articles available free online
- ▶ More accessibility of the articles to the readers/researchers within the field
- ▶ Better discount on subsequent article submission

Submit your manuscript at

<http://www.annexpublishers.com/paper-submission.php>