

Triple Synchronous Colon Tumors Causing Large Bowel Obstruction

Pataki I*, Soultan TG, Mohos Gy, Al-Hamadi M and Chanis W

Magyar Imre County Hospital, Ajka, Korányi F. u. 1, 8400, Hungary

*Corresponding author: Pataki I, Magyar Imre County Hospital, Ajka, Korányi F. u. 1, 8400, Hungary, E-mail: kolozsvar@chello.hu

Citation: Pataki I, Soultan TG, Mohos Gy, Al-Hamadi M, Chanis W (2016) Triple Synchronous Colon Tumors Causing Large Bowel Obstruction. J Surg Oper Care 1(2): 201. doi: 10.15744/2455-7617.1.201

Received Date: December 02, 2015 **Accepted Date:** January 20, 2016 **Published Date:** January 22, 2016

Abstract

We would like to present two patients with triple localized, synchronous colon tumors who underwent emergency operations for obstruction. The second and third localizations were discovered during the operation.

Keywords: Triple synchronous tumors; Bowel obstruction

Introduction

Using PubMed we found a diversity of publications referring to multiple colon tumors. Some of them defined synchronous tumors as affected large bowel sites alternating with healthy sections. The triple localization of colon tumors is a very rare condition.

Case presentation

In 2011, a 55 year old male patient was examined at the Internal Medicine Ward for diffuse abdominal cramps felt for already six months. He complained of fatigue, and moderate anemia was found. Other laboratory findings were irrelevant. A colonoscopy was performed and a stenotic tumor was found at 20 cm from the anal verge. The endoscope could not be passed through the tumorous site. Bowel obstruction symptoms developed a couple of hours after the examination.

We performed an emergency midline laparotomy. Beside the known stenotic tumor, we found another tumor expansively growing on the caecum. A right hemicolectomy and a segmental resection of the recto-sigmoid tumor were performed. During the mobilization of the descending colon we found the third tumor hiding in the splenic flexure. We removed it by another segmental colectomy. Bowel continuity was established by ileo-transversostomy and two end to end colo-colic anastomosis (Figure 1). The elongated sigmoid colon was very helpful in the reconstruction process. We finished the operation with a loop-ileostomy in order to avoid anastomotic leakage. The patient was discharged on the ninth postoperative day. His histological finding concluded pT3N1Mx, Dukes C, Astler-Coller C2 staging. As for genetics, mutation on the KRAS gene, exon 2 was described. Our patient underwent chemotherapy and after 8 months, and then he was readmitted to the surgical ward. His chest and abdominal CT's, tumor markers and colonoscopy findings showed normal parameters, so we suspended the loop-ileostomy. He continued chemotherapy (altogether 12 sessions with FOLFOX) and had colonoscopy and CT every year. He has been tumor free for almost 4 years.

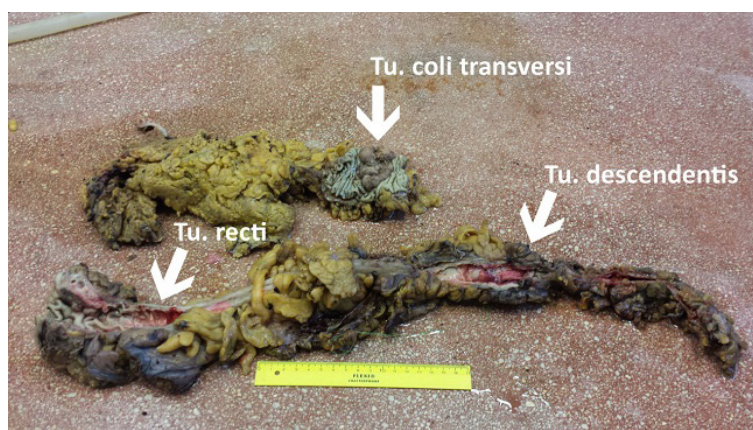


Figure 1: The pathological findings of the second patient

Another male patient was examined at the Internal Medicine Ward in 2014. The 62 year old man was known as an alcohol consuming, cirrhotic patient. Laboratory findings confirmed this status. A colonoscopy was performed in order to verify his mild abdominal complains. The tumors were localized at 5 cm and 50 cm from the anal verge. The latter one was stenosing. Also, a couple of hours later, symptoms of bowel obstruction developed, forcing us to perform an emergency midline laparotomy. A left hemicolectomy was done, closing the anal canal using Hartmann's procedure. After removing the gases and feces from the proximal colon site, we found the third tumor near the hepatic flexure, which was also removed. The ascending large bowel served for colostomy. His histological finding corresponded to pT3N2Mx, Dukes C, Astler-Coller C2 stage. A mutation on KRAS gene exon 2 was also found. We discharged this patient on the 13th postoperative day. His follow-up was difficult due to social problems. He died one month later in a hospice. On autopsy, liver metastasis was confirmed, and the staging became pT3N2M1.

Conclusions

The occurrence of double localization of colon tumors is estimated at around 1-8% [1-4], but triple synchronous tumors are rarer conditions [5]. The second tumor site is discovered mainly during emergency laparotomy [2]. Precise diagnosis localizing synchronous tumor sites can be made only when bowel obstruction is imminent. (wait and see) PET-CT colonography may be very helpful when total colonoscopy is not available or stenosing lesion is found [6]. As far as we know, these cases are the first ones published from Hungary.

References

1. van Leersum NJ, Aalbers AG, Snijders HS, Henneman D, Wouters MW, et al. (2014) Synchronous colorectal carcinoma: a risk factor in colorectal cancer surgery. *Dis Colon Rectum* 57: 460-6.
2. Gomez Iglesias S, Cunat Albert E, Torregrosa Puerta S, Lozano Requena JA, Tovar Gomez O, et al. (1989) Synchronous multiple carcinomas of the colon and rectum. Presentation of 18 cases and review of the literature. *Rev Esp Enferm Apar Dig* 76: 316-20.
3. Moreaux J, Catala M (1985) Multiple cancers of the colon and rectum. Incidence and results of surgical treatment *Gastroenterol. Clin Biol* 9: 336-41.
4. Bartha I, Bodrogi T, Sápy P (1989) Multiple primary cancer of the colon and rectum. *Orv Hetil* 130: 2077-80.
5. Yeh CC, Hsi SC, Chuu CP, Kao Yh (2013) Synchronous triple carcinoma of the colon and rectum. *World J Surg Oncol* 11: 66.
6. Nagata K, Ota Y, Okawa T, Endo S, Kudo SE (2008) PET/ CT colonography for the preoperative evaluation of the colon proximal to the obstructive colorectal cancer. *Dis Colon and Rectum* 51: 882-90.

Submit your next manuscript to Annex Publishers and benefit from:

- ▶ Easy online submission process
- ▶ Rapid peer review process
- ▶ Online article availability soon after acceptance for Publication
- ▶ Open access: articles available free online
- ▶ More accessibility of the articles to the readers/researchers within the field
- ▶ Better discount on subsequent article submission

Submit your manuscript at

<http://www.annepublishers.com/paper-submission.php>