

Single Stage Surgical Management of an Adult Patient with Crouzon Syndrome

Walecha K*, Nanda V, Sharma M and Agarwal A

Department of Plastic Surgery, Artemis Hospital, Gurgaon, India

*Corresponding author: Walecha K, MDS, Fellow in Facial Trauma, Cleft and Orthognathic Surgery, Registrar in Plastic Surgery Department, Artemis Hospital, Gurgaon, India, E-mail: dr.khushboo9@gmail.com

Citation: Walecha K, Nanda V, Sharma M, Agarwal A (2020) Single Stage Surgical Management of an Adult Patient with Crouzon Syndrome. J Surg Oper Care 5(1): 102

Received Date: April 25, 2020 Accepted Date: December 19, 2020 Published Date: December 22, 2020

Abstract

Crouzon syndrome is an autosomal dominant disorder characterized by fusion of coronal and sagittal sutures. There is arrested growth of the maxilla and zygoma resulting in shallow orbits with ocular proptosis, hypertelorism and maxillary hypoplasia. Hereby, we present a case report of a 20-year-old Jamaican female with Crouzon syndrome, who had multiple facial deformities including midfacial hypoplasia, short upper lip and hypertelorism. Keeping the patient's concern and circumstances in mind, a treatment plan was formalized and consisted of rhinoplasty, Abbe flap and right medial canthopexy as a single stage surgical intervention. The outcome was aesthetically pleasing. Given the variation of symptoms in this syndrome, an individualized treatment plan focusing on patient's concern is important.

Keywords: Crouzon Syndrome; Rhinoplasty; Abbe Flap

Introduction

Craniosynostosis is a group of rare hereditary disorders characterized by premature fusion of one or more cranial sutures in the embryonic period or during early childhood. Crouzon syndrome is an autosomal dominant disorder and is caused by mutation in Fibroblast growth factor receptor-2 (FGFR2) gene. It has a prevalence of approximately 1 in 25,000 live births and constitutes 4.8% of all craniosynostosis cases. The disease is characterized by premature fusion of coronal and sagittal sutures resulting in abnormal skull growth, affecting development of the orbits and the maxillary complex. Arrested growth of maxilla and zygoma results in midface hypoplasia and shallow orbit leading to severe proptosis. Narrow, high, or cleft palate can also be associated [1,2].

It was first described by Louis Edouard Octave Crouzon in 1902 who described it as craniofacial dysostosis with the triad of calvarial deformities, facial anomalies and exophthalmos in a woman and her son implying its genetic basis [3]. Craniosynostosis, maxillary hypoplasia, shallow orbits with ocular proptosis and hypertelorism are the cardinal features of crouzon syndrome. A class III malocclusion is reported in 75% of the patients with this syndrome. The etiology is generally due to short and retrusive maxilla with relative mandibular prognathism [4]. In cases with bilateral cleft lip and palate, there is depressed nasal tip, deficient columellar height and flared alar bases. Abbe flap is the most widely used flap for secondary correction of a cleft lip deformity. When combined with cosmetic cleft rhinoplasty, it offers a simple solution to midfacial deformity [5].

We present a case of 20-year-old female demonstrating the classical features of crouzon syndrome who was managed by multiple surgical corrections in a single stage.

Case Report

A 20-year-old female patient presented to the plastic surgery department for the aesthetic improvement of the mid-face. Surgical history included bilateral cleft lip repair at 1.5 year of age. At 7 years, she underwent craniotomy for cranial vault remodelling and box osteotomy right orbit for correction of right orbital dystopia and hypertelorism. General examination showed enlarged cranial vault with frontal bossing, maxillary hypoplasia, right side telecanthus, squint in the eye, short and tight upper lip, short columella, depressed nasal tip. She had scar on the upper lip from the previous surgery of bilateral cleft lip repair (Figure 1A and B).

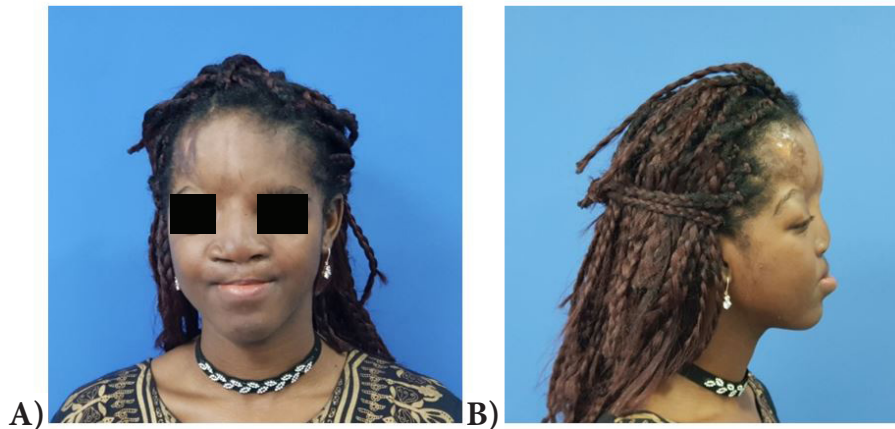


Figure 1: (A) Preoperative frontal view showing frontal bossing, depressed nasal tip, right side hypertelorism, scar on upper lip; (B) Lateral profile showing depressed nasal tip, maxillary hypoplasia

Intraoral examination revealed anterior and posterior crossbite, V shaped maxillary arch with high arch palate. Three-dimensional computed tomogram showed fused coronal and anterior half sagittal suture, protrusive pre-maxillary segment, maxillary hypoplasia with shallow orbits (Figure 2). No digital abnormalities were present. Systemic examination was found to be normal. Routine haematological and biochemical tests were within normal limits.

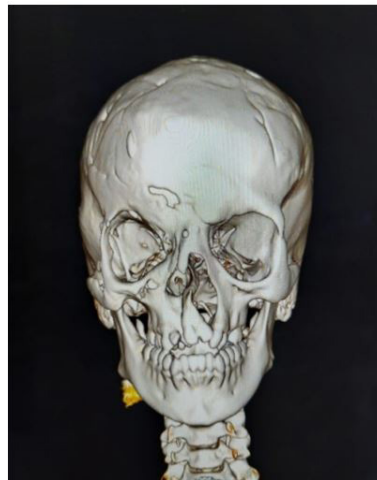

Figure 2: Three-dimensional computed tomogram showing protrusive premaxilla, fused coronal and anterior half of sagittal suture

Keeping in mind the patient's concern, an individualized treatment plan was formalized. Right medial canthopexy was done to correct right side telecanthus. Rhinoplasty was done by utilizing tissue from philtrum and using calvarial bone graft and conchal cartilage graft. Maxillary hypoplasia was camouflaged by an Abbe flap from the lower lip.

Surgical Technique and Post-Surgical Evaluation

Nasal dorsum augmentation and tip elevation was achieved by a cantilever calvarial bone graft as patient was not willing for scar due to costal cartilage harvest. Conchal cartilage graft was used to support lower lateral cartilages. Columella was lengthened by utilizing tissue from the philtrum of the upper lip and the residual defect in the upper lip was filled by an Abbe flap from the lower lip. Medial canthopexy was done on the right side. The surgical techniques for the various procedures are elaborated as follows:

Medial Canthopexy on the Right Side

A double opposing Z plasty was planned. After dissection, medial orbital wall was exposed and medial canthal tendon was identified. Two holes were drilled in the postero-superior part of posterior lacrimal crest. Prolene 3-0 suture was passed through the medial canthal tendon and traction was applied to ensure pulling it and then sutured to the drilled holes. Closure was done in layers.

Harvesting the Split Calvarial Bone Graft

A curved incision was given over the proposed graft site over the left parietal bone (Figure 3). Subperiosteal flap was raised to expose the proposed site. Marking was done 2 cm lateral to the sagittal suture. Osteotomy was done through the outer table and 5 cm x 1 cm of bone strip was removed and kept in normal saline. The edges of donor site were rounded off. After proper haemostasis, closure was done in layers.

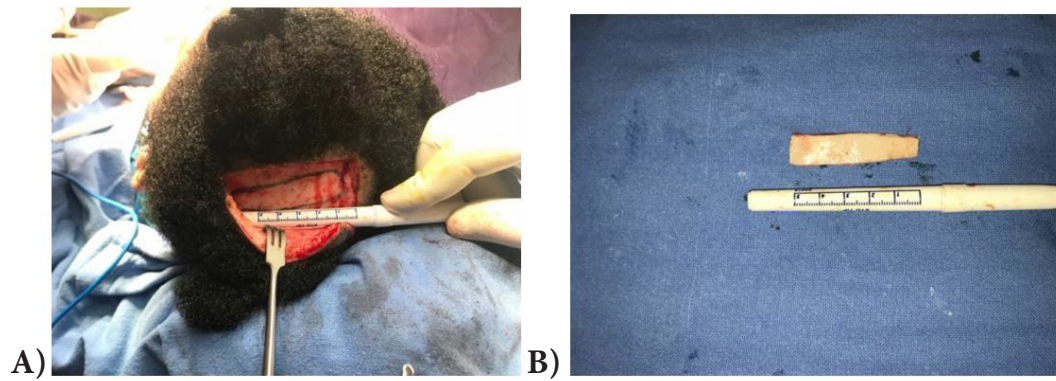


Figure 3: (A) Intraoperative picture of harvesting calvarial graft; (B) 5 cm x 1 cm of harvested calvarial graft

Harvesting the Conchal Cartilage

Retroauricular incision was given on the left side. Blunt dissection was done over the area to be resected, followed by subperichondrial dissection to harvest the conchal cartilage. Closure was done in 2 layers. Tie over dressing was given.

Rhinoplasty

Incision started over philtral base and then extended upwards just adjacent to columella laterally, extending to nasal mucosa. Subperichondrial dissection was done. A pocket was created over the nasal dorsum to place the graft. The harvested calvarial graft was shaped to reproduce the contour of nasal dorsum and was put in the created pocket. A stab incision was given at the root of the nose to fix the graft to the nasal bone with a 6 mm screw. Interdomal sutures were put with non-resorbable sutures to approximate alar cartilages. Harvested conchal cartilage was used as columella strut and to support the lower lateral cartilages. Philtrum was used to lengthen the columella (Figure 4).

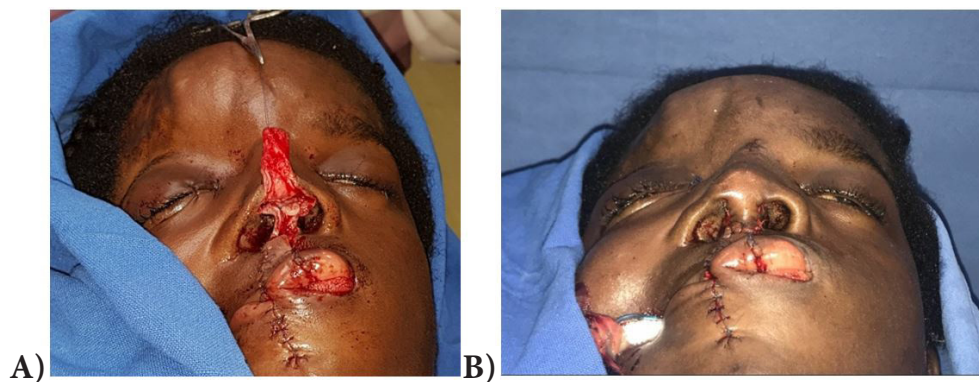


Figure 4: (A) Intraoperative picture showing Abbe flap and columellar strut graft; (B) Immediate postoperative picture showing lengthening of the columella using philtral tissue

Abbe Flap

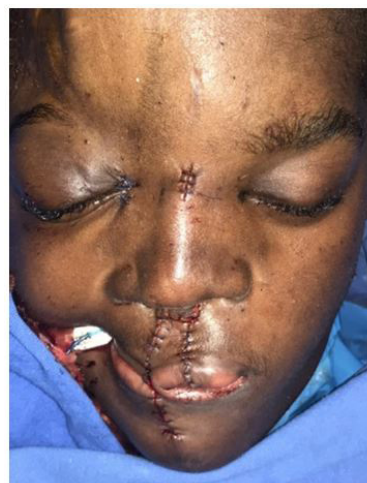

Figure 5: Immediate post-operative picture showing Abbe flap rotated upwards to reconstruct philtrum

Abbe flap was designed on the central portion of the lower lip to fill the defect in the philtrum column. Abbe flap based on the left inferior labial artery was elevated and a cuff of muscle was left around the pedicle. Flap was then rotated upwards and placed into the residual defect of the upper lip philtral area and sutured to the lateral segments (Figure 5). Donor defect of the lower lip was closed in layers. In the second stage, Abbe flap was detached and final inseting was done in under local anaesthesia after 3 weeks.

No nasal packing was used in post-operative period. The patient was discharged on 2nd postoperative day. There was no peri-operative complication such as airway obstruction, bleeding, infection, wound disruption, flap necrosis, alopecia. Post-operative recovery was uneventful.

An improvement in patient's profile was achieved. Patient expressed satisfaction with the final lip/nose appearance.

Follow up- At 2 years postop, we noticed hypertrophic scar of the previous operated site at the upper lip, for which 2 intralesional injection of Triamcinolone acetonide were given, following which there was improvement of the scar. She has started using eyebrow pencil to match the opposite eyebrow. Patient has been referred to an orthodontist for teeth alignment (Figure 6).

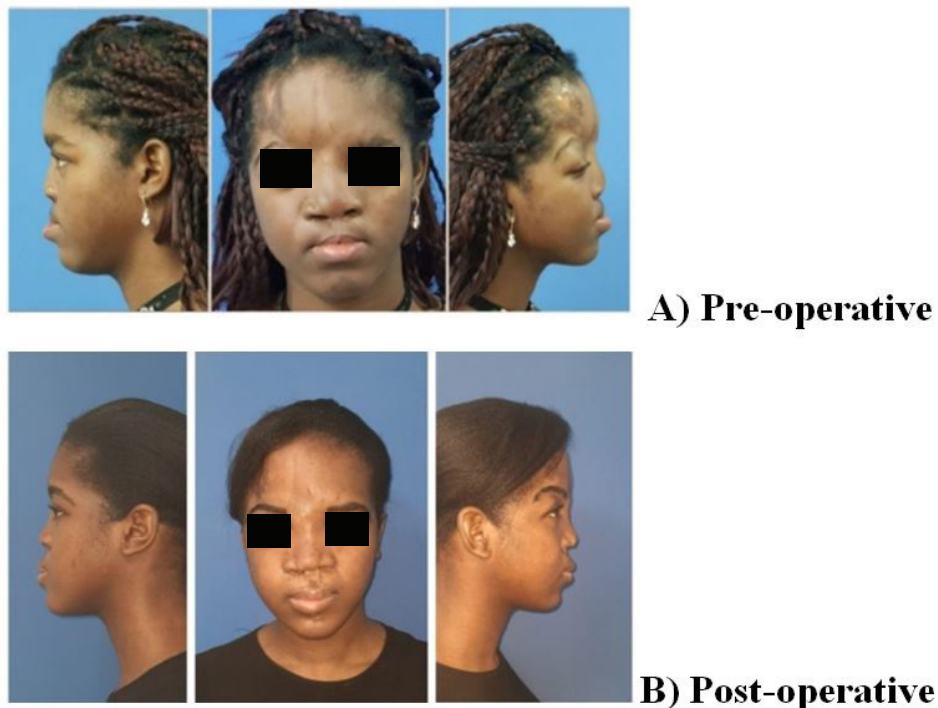


Figure 6: (A) Pre-operative and (B) Post-operative (2 years postop) Lateral and Frontal profile of the patient showing improved profile of the patient, improved nasal profile, and reduced hypertelorism

Discussion

Crouzon syndrome is an autosomal dominant disorder caused by mutation in the fibroblast growth factor receptor 2 (FGFR2) gene. This gene enables coding of a protein called fibroblast growth factor receptor-2. This protein is one of the four FGFR's responsible for the formation of blood vessels, wound healing, embryonic evolution and regulation of cellular division, growth and maturation. FGFR binds to fibroblast growth factors with higher affinity and plays an important role in signal pathways which function in the fusion process of skull bones [6].

The differential diagnosis includes Apert syndrome, Pfeiffer syndrome, Carpenter syndrome. An important feature discerning Crouzon syndrome from other related disorders is normal hands and feet found in a Crouzon patient. In Apert syndrome, symptoms are more severe and there is syndactyly of the extremities. Pfeiffer syndrome is characterized by the craniosynostosis along with enlarged thumbs and toes. In the present case, there was no such anomaly of the extremities [7].

Crouzon syndrome is characterized by premature fusion of the coronal and sagittal suture. Lambdoidal sutures are occasionally involved [8]. Multiple sutural synostosis extends to the premature fusion of the skull base leading to arrested growth of maxilla and zygoma which result in shallow orbits with resulting bilateral severe proptosis [2]. Proptosis is the most common feature and may be severe with vision-threatening corneal exposure which may require reconstructive surgery earlier than usual. There may be associated chronic papilledema causing optic atrophy. The appearance of a patient with crouzon syndrome can vary from mild midface deficiency to more severe form exhibiting multiple fused cranial sutures and marked midface and orbital anomalies [9].

For the successful management of Crouzon syndrome, early diagnosis at the right age is the single most important prognostic factor. The surgical treatment consists of two phases. The first phase takes place in the first year of life, when cranial vault remodelling is done to release the fused sutures of the skull to prevent increase in cranial pressure and allow adequate cranial volume for brain growth and expansion. Cleft lip and palate are repaired in this phase. Fronto-orbital advancement and reshaping inclusive of cranial vault remodelling, strip craniectomy is done between 6 months to 4 years. Our patient gave a history of bilateral cleft lip repair at 1.5 year and cranial vault remodelling at 7 years of age.

The midfacial advancement is done in the second phase, which takes place between 4-12 years. Generally, Lefort III osteotomy or distraction osteogenesis is required [10]. But in cases with mild midface hypoplasia, as in our case, midface hypoplasia can be very well camouflaged by balancing the soft tissues between upper and lower lips.

Crouzon syndrome patients demonstrate large variability in the symptoms and each patient requires a customized treatment plan as per the underlying abnormality. Our patient had mild maxillary hypoplasia which was camouflaged well by restructuring the soft tissues, resulting in an aesthetically pleasing face. Tissue from philtrum was used to lengthen the columella and the residual defect was filled by Abbe's flap. The "Abbe flap" was introduced by Dr. Robbert Abbe as "Lip switch" procedure in 1898 for secondary correction of a cleft lip deformity. In this technique, tissue is taken from the lower lip and transposed to the upper lip philtral area giving it fullness and creating a balance of tissues between upper and lower lip. The versatility of Abbe flap to correct bilateral cleft lip deformity is a time-tested modality. When combined with cosmetic cleft rhinoplasty, it offers a better solution to midface deformity [5]. So, considering the concerns of the patient, a well formalized treatment plan was made, by which we could correct maxillary hypoplasia, cleft nasal deformity and right sided telecanthus.

The therapy of Crouzon syndrome is complex and long lasting. In most of the children, it starts immediately after birth and ends with complete cessation of growth and development, after all therapeutic and corrective interventions. The diagnosis and treatment of this disease requires collaboration of a multidisciplinary team in collaboration with neurosurgeon, plastic surgeon, ophthalmologist, neurologist, orthodontist and pedodontist. Surgical reconstruction has to be thoughtfully sequenced and staged with consideration for specific malformations and craniofacial growth patterns. This guarantees adequate and timely observation and treatment of such patients. Orthodontic evaluation should also begin at an early age, as this would help in the correction of developing anterior crossbite, development of class III deformity, and associated functional abnormalities. In our patient, there is crowing in the maxilla for which she has been referred to an orthodontist.

Surgeon should explain to the parents the goals and the way of treatment, in order to establish adequate co-operation with parents, which ultimately improves the outcome of the treatment.

Conclusion

Every child with crouzon syndrome should be thoroughly evaluated. It requires careful planning and staged management in collaboration with the various members of the craniofacial team and the family. The treatment plan depends on the extent of the deformity and should be customized after discussing the pros and cons of the various options with the patient and his family. The midface hypoplasia can be satisfactorily managed by nasal correction and lip switch procedure and this can avoid formal bony procedures in the maxilla. These patients need multiple procedures staged over many years and hence, long term followup with the craniofacial team is crucial.

References

1. Morshed J, Mutanabbi M, Hafiz MG (2017) Crouzon syndrome: an experience of surgical intervention at Bangabandhu Sheikh Mujib Medical University, Bangla J Unexplored Med Data 2: 48-51
2. Padmanabhan V, Hedge AM, Rai K (2011) Crouzon's syndrome: A review of literature and case report. *Contemp Clin Dent* 2: 211-14.
3. Hariri F, Rahman ZAA, Bahuri NFA, Azmi MN, Abdullah NA, et al. (2018) Crouzon Syndrome: A case series of craniomaxillofacial distraction osteogenesis for functional rehabilitation. *J Oral Maxillofac Surg* 76: 646.e1-646.e12.
4. Ahmed I, Afzal A (2009) Diagnosis and evaluation of Crouzon syndrome. *J Coll Physicians Surg Pak* 19: 318-20.
5. Balaji SM (2018) Cleft rhinoplasty columellar lengthening: Comparison of techniques. *Ind J Dent Res* 29: 26-33.
6. Koca TT (2016) Apert syndrome: A case report and review of the literature. *North Clin Istanbul* 3: 135-9.
7. Gopal KS, Sundaram MS, Kumar PM (2017) Crouzon syndrome- A case report of Rare Genetic Disorder with Review of Literature. *SAJ Case Report* 4: 105.
8. Saraswathi GK, Amala K (2018) Crouzon syndrome- A rare genetic disorder. A case report and a detailed review of literature. *Int J Adv Case Reports* 5: 27-32.
9. Abdullah AM (2019) Crouzon syndrome: Variability in clinical severity at a presentation- A clinic-radiological evaluation. *Ophthalmol Case Rep* 3: 2-8.
10. Kyprianou C, Chatzianni A (2018) Crouzon syndrome: A comprehensive review. *Balk J Dent Med* 1-6.

Submit your next manuscript to Annex Publishers and benefit from:

- ▶ Easy online submission process
- ▶ Rapid peer review process
- ▶ Online article availability soon after acceptance for Publication
- ▶ Open access: articles available free online
- ▶ More accessibility of the articles to the readers/researchers within the field
- ▶ Better discount on subsequent article submission

Submit your manuscript at
<http://www.annexpublishers.com/paper-submission.php>