

Application of CCASNS with iVNS in The Treatment of Cerebral Palsy with Drug-Refractory Epilepsy

Wu Y, Gao D, Guo Y, Xie J, Shan Q, Du N and Wang X*

The Fifth Affiliated Hospital of Zhengzhou University, Zhengzhou city, Henan Province, China

*Corresponding author: Wang X, postal address: 5th Affiliated Hospital of Zhengzhou University, 3 Kangfuqian Street, Erqi District, Zhengzhou City, Henan Province, China

Citation: Wu Y, Gao D, Guo Y, Xie J, Shan Q, et al. (2021) Application of CCASNS with iVNS in The Treatment of Cerebral Palsy with Drug-Refractory Epilepsy. J Surg Oper Care 6(1): 101

Abstract

The aim of this study was to investigate the safety and feasibility of common carotid artery sympathetic nerve network stripping (CCASNS) combined with implanted vagus nerve stimulation (iVNS) for seizure control in children with cerebral palsy with refractory epilepsy. We reviewed the medical records of children with cerebral palsy with drug-refractory epilepsy treated at the Fifth Affiliated Hospital of Zhengzhou University from September 2015 to June 2019. The children were divided into two groups according to whether they received CCASNS or not. The clinical data and the efficacy of the procedure were analyzed statistically in both patient groups. The operative time and hospital costs differed significantly between the two groups. The score on the Modified Ashworth Scale in the combined group differed significantly from those in the preoperative and iVNS groups, and seizure control was better in the combined group than in the iVNS group. The quality-of-life score was also higher in the combined group than in the iVNS group. CCASNS combined with iVNS is safe, feasible, and effective in children with cerebral palsy with drug-refractory epilepsy. The combined operation provides better seizure control and a higher quality of life than does iVNS alone.

Keywords: Common Carotid Artery Sympathetic Nerve Network Stripping; Cerebral Palsy; Epilepsy; implanted Vagus Nerve Stimulation (iVNS)

List of abbreviations: CCASNS: Common Carotid Artery Sympathetic Nerve Network Stripping; iVNS: implanted Vagus Nerve Stimulation; AEDs: Antiepileptic Drugs; MAS: Modified Ashworth Scale; PEDSQL™: The Pediatric Quality Of Life

Introduction

Reported prevalence of epilepsy in children with cerebral palsy is about 25% to 45%, and about half of them eventually develop drug-refractory epilepsy, which leads to a poor prognosis [1-3]. Epilepsy is therefore one of the most common and serious complications in children with cerebral palsy [1]. With each seizure, the brain damage is further aggravated, jeopardizing the cognitive, memory and motor functions of the child with cerebral palsy, which then affects the rehabilitation of the child with cerebral palsy, bringing a huge burden to the society and family, especially the mother of the child, and affecting the quality of life [4]. Therefore, an important basis for successful rehabilitation of children with cerebral palsy with drug-refractory epilepsy is early and complete seizure control, which has important implications for the long-term prognosis of the child.

Common carotid artery sympathetic nerve network stripping (CCASNS) has been reported to improve muscle tone, orientation, and motor function in children with cerebral palsy, and also help to improve salivary symptoms, swallowing, and cognitive function [5]. Implanted vagus nerve stimulation (iVNS) is a novel and effective adjunctive treatment for medically refractory epilepsy that can reduce the frequency and severity of seizures, improve cognitive function, and enhance the quality of life [6,7]. However, there are few reports on the combined application of these two procedures in the treatment of children with cerebral palsy with drug-refractory epilepsy that affect seizures. The aim of this study was to investigate the safety and feasibility of CCASNS combined with iVNS for seizure control in children with cerebral palsy with refractory epilepsy.

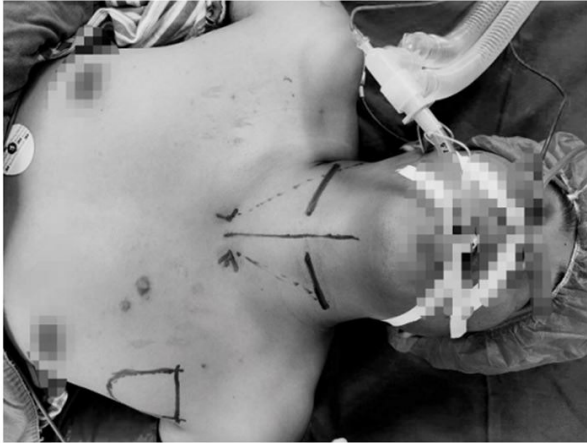Methods

Study population

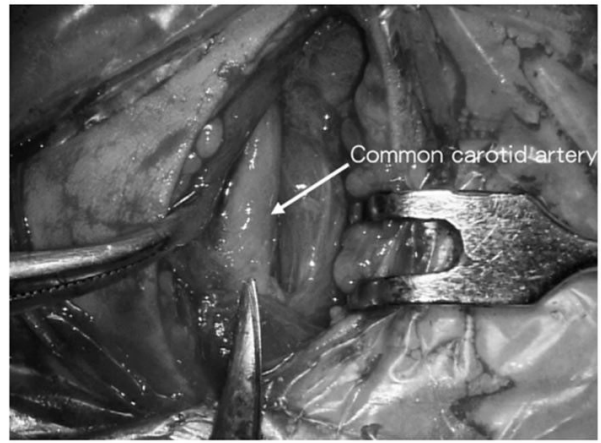
We retrospectively analyzed 142 cerebral palsy patients with drug-refractory epilepsy who were treated at the Fifth Affiliated Hospital of Zhengzhou University from September 2015 to June 2019. The combined group comprised 39 patients who received iVNS plus CCASNS, while the iVNS group comprised 42 patients who refused to undergo CCASNS and so only received iVNS treatment. The following inclusion criteria were applied: (1) disease conforming with previously defined diagnostic criteria [8], (2) aged 6–18 years, (3) presence of drug-resistant epilepsy and the taking of more than two kinds of antiepileptic drugs (AEDs) and standardized treatments for >2 years associated with a failure to effectively control seizures [9], (4) and consent provided by the child and their family prior to surgery. The exclusion criteria were as follows: (1) MRI results showing that the epilepsy was caused by an intracranial occupying lesion, (2) inoperable cervical vagus nerve injury or local skin breakdown, or (3) other systemic diseases or other contraindications to surgery. This study was approved by the hospital medical ethics committee.

Surgical procedure

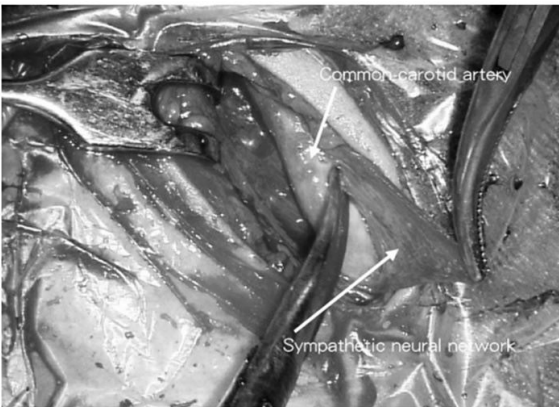
All procedures were primarily performed by the same surgeon. For those who received both CCASNS and iVNS [7], after successful tracheal intubation under general anesthesia, the patient was placed in a supine position with pads under the shoulders and the head tilted back. Both sides of the neck incision were located inside the middle and lower one-third of the sternocleidomastoid muscle. The surgeon incised the skin, the broad cervical muscle, and the anterior cervical fascia on the left side of the neck, separated the sternocleidomastoid muscle medially to the carotid sheath, opened and excised part of the sheath, and then circumscribed the outer membrane of the common carotid artery with the aid of a microscope over a circumference of about 3 cm. The same procedure was performed on the right side. Immediately after separating the vagus nerve between the common carotid artery and the jugular vein, the connective tissue around the vagus nerve trunk and the posterior sheath of the carotid sheath were removed, and the vagus nerve was carefully separated with a 3-cm length being exposed. After achieving complete hemostasis, the surgeon wrapped a spiral electrode around the vagus nerve on the left side of the neck, and then made a 7- to 10-cm-long transverse incision in the left subclavian chest wall to accommodate the pulse generator. A subcutaneous wire was threaded through the subclavian chest wall to connect the electrode lead to the pulse generator for stimulating the vagus nerve. The incision was closed in a layer-



A Surgical position and surgical site for combined surgery




B The common carotid artery was isolated medial to the sternocleidomastoid muscle



C Circumferential resection of the common carotid artery epicardium about 2.5 cm



D Excision of the connective tissue around the vagus trunk and part of the posterior wall of the sheath of the carotid artery



E Separation and exposure of the vagus nerve



F Wrap electrodes around the vagus nerve on the left side of the neck and fix them



G A 7-10 cm transverse incision was made in the left subclavian chest wall to accommodate the pulse generator

Figure 1: Surgical procedure

by-layer manner after the vital signs had returned to normal. During the operation, extreme care was taken to avoid damaging tissues such as the vessel wall, the recurrent laryngeal nerve, or the cervical sympathetic nerve stem, and to reduce the probability of complications such as vessel rupture, choking on drinking water, or Horner's syndrome (Figure 1). The vagus nerve stimulator was turned on at 2 weeks after surgery, with the output current adjusted according to the efficacy and tolerance level in each child.

Rehabilitation exercises

Postoperative rehabilitation was performed using a combination of motor training, occupational therapy, speech and swallowing training, and physical-factor therapy to promote the achievement of normal motor function. Professional doctors and rehabilitators provided one-on-one guidance and assistance to the children.

Preoperative assessment content

The measured parameters included general demographics, liver function (total bilirubin and albumin), and blood coagulation function (platelets and prothrombin time) during the week before surgery, and also the score on the Modified Ashworth Scale (MAS) [10]. Information recorded in the subjects' preoperative epilepsy diaries (e.g., seizure frequency, seizure intensity, seizure form, and AED use) were used as baseline indicators, and PEDSQL™ questionnaire scores (edition 4.0) [11,12] [5,6] were measured in the two study groups.

Surgical and short-term outcomes

The primary clinical data included anesthesia time, bleeding, complications, and mean length of the hospital stay. The short-term outcome was assessed at 3 months postoperatively, which included (1) the MAS score to evaluate limb tone; (2) the modified Engel classification to assess the frequency, seizure form, and seizure intensity of postoperative seizures, with grades I–III considered to indicate that the treatment had been effective, as well as evaluations of efficacy and safety; (3) and the PEDSQL™ score for evaluating the quality of life.

Statistical analyses

Continuous variables are presented as mean±SD values, and categorical variables are expressed as numbers and proportions. Continuous data were compared between groups using t tests or U tests. Differences in categorical data were analyzed using the χ^2 test or Fisher's exact test. All statistical analyses were performed at a two-sided level of significance of 0.05, and $P < 0.05$ was considered indicative of a statistically significant difference. All analyses were carried out using SPSS for Windows (version 26.0).

Results

Preoperative patient characteristics

There were no statistically significant differences between the two study groups in terms of age, sex, liver function, coagulation status, muscle tone, types of AEDs taken, seizure frequency, or PEDSQL™ score (Table 1).

Parameter	Combined group (n=39)	VNS group (n=42)	T or χ^2 Value	p-Value
Age (mean ± SD)	11.64±2.61	12.12±3.37	0.798	0.427
Sex, M/F	16/13	27/15	0.597	0.440
Total bilirubin, umol/L (mean ± SD)	8.18±2.89	8.46±2.89	0.428	0.67
Albumin, g/L, mean ± SD)	40.89±3.42	40.38±3.64	0.66	0.511
Prothrombin time, s (mean ± SD)	10.41±0.69	10.39±0.71	0.141	0.888
Platelets, *10 ⁹ /L (mean ± SD)	186.95±56.97	195.95±52.64	0.764	0.447

Parameter	Combined group (n=39)	VNS group (n=42)	T or χ^2 Value	p-Value
MAS			2.025	0.846
Level 0	0	1		
Level 1	3	4		
Level 1+	5	3		
Level 2	10	13		
Level 3	12	13		
Level 4	9	8		
AEDs, n (mean \pm SD)	3.03 \pm 0.99	2.83 \pm 0.87	0.913	0.364
Seizure Frequency (mean \pm SD)	13.56 \pm 3.102	14.21 \pm 3.496	0.883	0.38
PEDSQL™ Questionnaire Score (mean \pm SD)	47.46 \pm 5.13	45.95 \pm 5.34	1.296	0.199

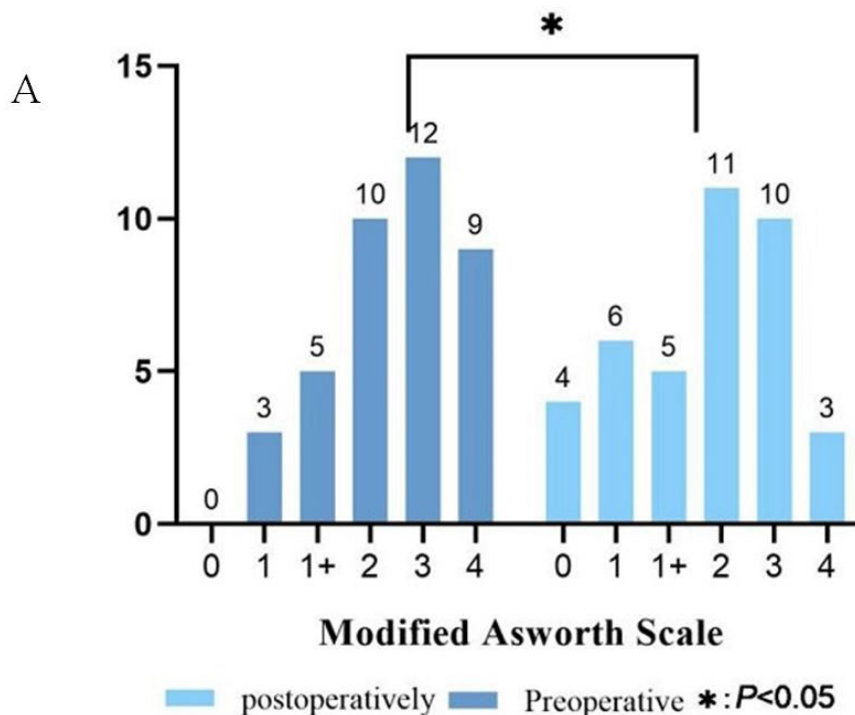
Table 1: Distribution of baseline characteristics within the two group

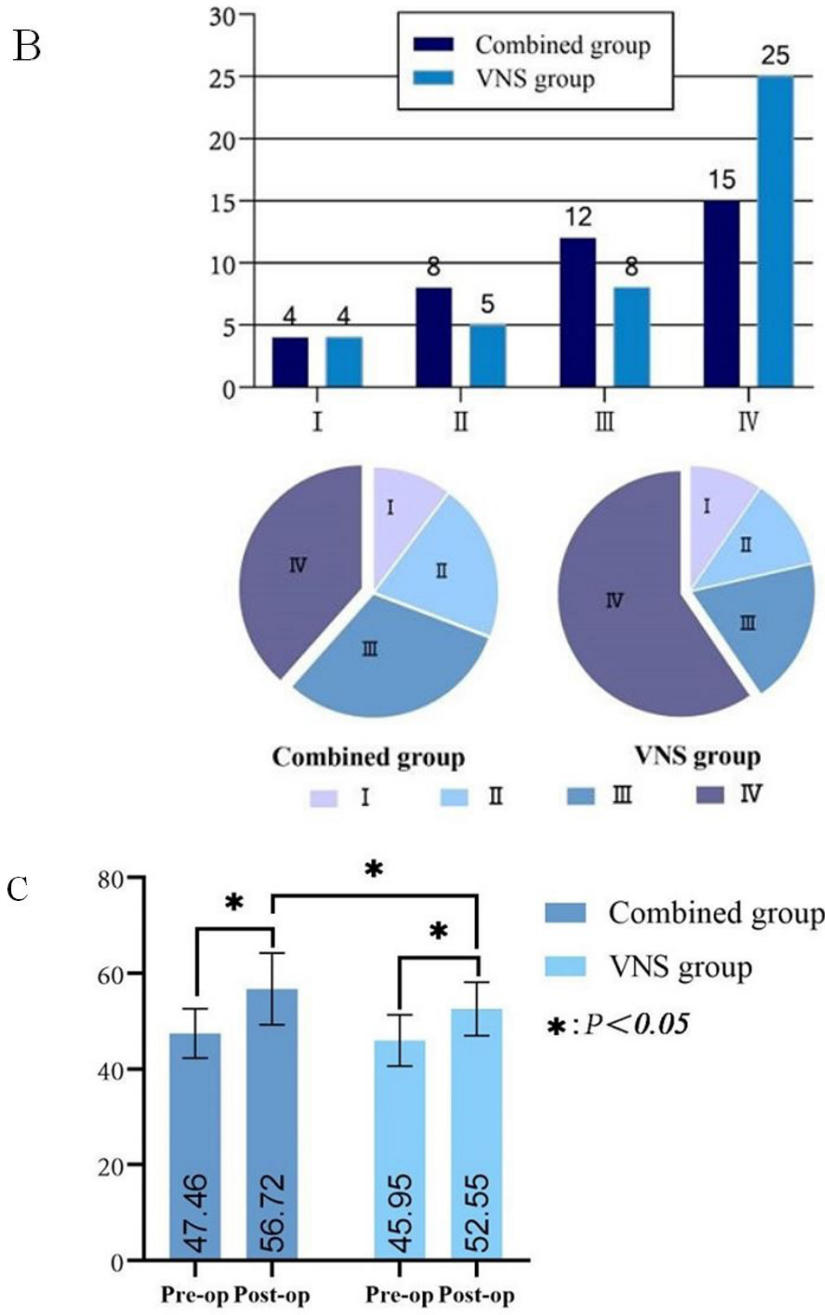
Operative and postoperative outcomes

The mean anesthesia time and hospitalization cost differed significantly between the two groups ($P < 0.05$), whereas the mean length of the hospital stay, intraoperative bleeding status, and complications did not ($P > 0.05$) (Table 2).

Parameter	Combined group (n=39)	VNS group (n=42)	T or χ^2 Value	p-Value
Duration of surgery, min	224.36 \pm 15.29	165.81 \pm 12.58	18.643	0
Postoperative hospital days, n	6.33 \pm 1.85	6.57 \pm 1.82	0.582	0.562
Bleeding volume, ml	45.26 \pm 13.81	39.76 \pm 12.25	1.898	0.061
Hospitalization costs	15.35 \pm 0.63	13.1 \pm 1.40	9.524	0
Postoperative complications, n	3 (7.7%)	4 (9.5%)	0.086	0.769

Table 2: Clinical data of two groups





(A) The MAS of Combined group; (B) Seizure conditions; (C) PEDSQL™ questionnaire scores
Figure 2: Outcomes of MAS, seizure control, and quality of life after surgery

Muscle tone

Limb spasticity had improved significantly in the combined group at 3 months postoperatively compared with preoperatively (P=0.016) (Figure 2A). No significant change in limb spasticity was observed in patients in the iVNS group between the postoperative and preoperative periods.

Epileptic seizures

The types of AEDs in the two groups after surgery did not change significantly compared with the preoperative period. At 3 months postoperatively there was an improvement in epilepsy according to the modified Engel classification (Figure 2B) in 61.5% of patients in the combined group and in 40.5% of those in the iVNS group (P=0.047).

Quality of life

The quality of life improved significantly postoperatively in both groups compared with the preoperative period. The PEDSQL™ score was significantly better in the combined group than in the iVNS group ($P=0.017$, Figure 2C).

Discussion

There have been rapid developments recently in cervical sympathectomy procedures. The ongoing research and associated improvements in understanding are constantly changing its application scope. Early sympathectomy procedures were first used for the treatment of epilepsy, and Australian surgeons Royle and Hunter were the first to apply sympathectomy for the treatment of spastic paralysis [13]. CCASNS has mainly been used for treating Moyamoya disease and cerebral palsy. This procedure has reportedly been carried out in several cerebral palsy treatment centers (e.g., the China-Japan Friendship Hospital in China) for more than 20 years to treat patients with cerebral palsy, and good results have been achieved [14]. Neurostimulation is considered a safe and effective method for treating refractory epilepsy. Current neurostimulation treatments include iVNS, trigeminal nerve stimulation, repetitive transcranial magnetic stimulation, and deep brain stimulation [15,16]. The US FDA approved the use of iVNS for the treatment of refractory epilepsy in 1997, and clinical studies have shown that it is a safe and effective adjunctive treatment for refractory epilepsy [17]. There have only been a few reports on CCASNS combined with iVNS being applied to children with cerebral palsy with drug-refractory epilepsy, and so we investigated the safety and efficacy of the combined procedure in this population.

In terms of surgical safety, this study found showed that the surgical time was significantly longer in the combined group than in the iVNS group. This is mainly due to the increased number of surgical steps required in the combined group, and the close proximity of structures such as the common carotid artery, vagus nerve, jugular vein, and recurrent laryngeal nerve, and the narrow operating space, which requires extreme caution when stripping the sympathetic nerve network around the common carotid artery to prevent serious complications from injury to the carotid artery and its surrounding nerves. However, the number of postoperative hospital days, bleeding status, and postoperative complications did not differ significantly between the two groups in this study. Moreover, CCASNS plus iVNS can be completed during a single perioperative period, with the combined procedure requiring as little as one additional surgical incision in the right neck compared with iVNS alone. Two cases of hoarseness and one case of sensory abnormality occurred in the combined group after surgery, while one case of hoarseness, two cases of sensory abnormality, and one case of pharyngeal discomfort occurred in the iVNS group. There was no significant difference in the probability of complications, and all complications were transient, with them gradually disappearing over 3–7 days postoperatively. No serious surgery-related adverse effects such as incisional infection, bleeding in the operative area, or carotid artery rupture were observed in either group during the perioperative or postoperative observation periods. Both CCASNS and iVNS are minimally invasive treatments and are associated with less surgical trauma, less bleeding, and a very low probability of postoperative complications. Compared with iVNS, the combined procedure was not associated with any significant difference in bleeding, postoperative complications, or mean length of the postoperative hospital stay, which indicates that CCASNS plus iVNS is a safe and feasible treatment modality.

We found that the MAS score was significantly better in the combined group than in the iVNS group at the postoperative assessment, and better than that at the preoperative assessment. This indicates that the patients in the combined group exhibited a significant improvement in body muscle tone after surgery compared with the preoperative period, with the improvement being more pronounced than that in the iVNS group. In contrast, patients in the iVNS group showed no significant change in the MAS score and no significant improvement in muscle tone compared with the preoperative period. These findings suggest that stripping of the sympathetic network around the common carotid artery helps to improve muscle function and motor deficits in children with cerebral palsy with drug-refractory epilepsy. This is consistent with Shao et al. [14] and Xu et al. [18] finding that pericervical sympathetic nerve network stripping helps to improve muscle tone in children with cerebral palsy.

Before surgery, there was no significant difference between the two groups in either the types of oral AEDs taken or the intensity and frequency of seizures. Our analysis of the effect on epilepsy control based on the modified Engel classification revealed that the combined group was superior to the iVNS group at 3 months postoperatively. A possible reason for this is that the children in the combined group underwent CCASNS. There has been little research into the effects of CCASNS on seizures. Lee et al. suggested that surgical excision of the sympathetic nerve network around the cerebral vessels—aimed at inhibiting sympathetic activity—helps to improve cerebral ischemia and increase blood circulation to the brain, thereby allowing some nerve cells in a critical state to recover function to varying degrees [19,20], and also improving the response of the brain to vagal stimulation. That mechanism might at least partially explain why patients treated with the combination of the two procedures experience a greater benefit.

The present investigation of the effects of CCASNS and iVNS on the quality of life of children with cerebral palsy with drug-refractory epilepsy revealed that the PEDSQL™ scores of patients in both groups were significantly higher than before the surgery, and clearly higher in the combined group than in the iVNS group. This suggests that CCASNS combined with iVNS will induce in a greater improvement in the quality of life of affected patients. This is consistent with previous findings, such as those of Solman et al. [21] and Shao et al. [14]. Although the combined procedure costs more, it provides better postoperative seizure control, greater improvement in limb tone, higher quality of life, and more benefit to the children and their families.

This retrospective study suggests that CCASNS combined with iVNS is effective, safe, and feasible in children with cerebral palsy with drug-refractory epilepsy, and is more effective than iVNS alone in controlling their seizures.

Our study had several limitations. First, it had a retrospective and observational design, and the data collected on seizures, limb tone, and quality of life of the children relied on recall by the patients or their caregivers, and hence might have been influenced by information and selection biases. Second, the study was performed at a single center, resulting in a small and potentially unrepresentative sample, also with a short follow-up period. Third, some of the measures used were subjective, and so more objective measures need to be used in future studies.

Acknowledgments

This study was funded by the Medical Science and Technology (Joint Construction) Project of Henan Province (No. LHGJ20190418).

References

1. Karatoprak E, Sözen G, Saltık S (2019) Risk factors associated with epilepsy development in children with cerebral palsy. *Child's Nerv Syst* 35.
2. Cooper MS, Mackay MT, Fahey M, Reddihough D, Reid SM, et al. (2017) Seizures in Children With Cerebral Palsy and White Matter Injury. *Pediatrics* 139: e20162975.
3. Hanci F, Türay S, Dilek M, Kabakuş N (2020) Epilepsy and drug-resistant epilepsy in children with cerebral palsy: A retrospective observational study. *Epilepsy Behav* 112: 107357.
4. Graham HK, Rosenbaum P, Paneth N, Dan B, Lin J-P, et al. (2016) Cerebral palsy. *Nature Reviews Disease Primers* 2: 15082.
5. Li AM, Yu YB, Zhang L, Xu XL, Xu J (2013) Bilateral cervical sympathectomy and trapping of cervical vagus nerves for refractory mixed cerebral palsy. *Chin J Clin Neurosurg* 18: 1-4.
6. Wheless JW, Gienapp AJ, Ryvlin P (2018) Vagus nerve stimulation (VNS) therapy update. *Epilepsy Behav* 88: 2-10.
7. Toffa DH, Touma L, El Meskine T, Bouthillier A, Nguyen DK (2020) Learnings from 30 years of reported efficacy and safety of vagus nerve stimulation (VNS) for epilepsy treatment: A critical review. *Seizure* 83: 104-23.
8. Li XJ, Tang JL, Ma BX, Qin J, Zou LP, et al. (2014) Definition, diagnostic criteria and clinic classification of cerebral palsy. *Chin J Appl Clin Pediatr* 29: 10.3760/j.issn.2095-428X.2014.19.024.
9. Asadi-Pooya AA, Stewart GR, Abrams DJ, Sharan A (2017) Prevalence and Incidence of Drug-Resistant Mesial Temporal Lobe Epilepsy in the United States. *World Neurosurg* 99: 662-6.
10. Halakoo S, Ehsani F, Masoudian N, Zoghi M, Jaberzadeh S (2020) Does anodal trans-cranial direct current stimulation of the damaged primary motor cortex affects wrist flexor muscle spasticity and also activity of the wrist flexor and extensor muscles in patients with stroke?: a Randomized Clinical Trial. *Neurol Sci* 10.1007/s10072-020-04858-9.
11. Desai VR, Gadgil N, Saad S, Raskin JS, Lam SK (2019) Measures of Health-Related Quality of Life Outcomes in Pediatric Neurosurgery: Literature Review. *World Neurosurg* 122: 252-65.
12. Knorr C, Greuter L, Constantini S, Fried I, Kremer U, et al. (2021) Subgroup analysis of seizure and cognitive outcome after vagal nerve stimulator implantation in children. *Childs Nerv Syst* 37: 243-52.
13. Collins SL (1991) The cervical sympathetic nerves in surgery of the neck. *Otolaryngol Head Neck Surg* 105: 544-55.
14. Shso X, Yu YB, Zhang (2020) Research progress of cerebral palsy. *J Clin Neurosurg* 17: 236-40.
15. Davis P, Gaitanis J (2020) Neuromodulation for the Treatment of Epilepsy: A Review of Current Approaches and Future Directions. *Clin Ther* 42: 1140-54.
16. Fisher R, Salanova V, Witt T, Worth R, Henry T, et al. (2010) Electrical stimulation of the anterior nucleus of thalamus for treatment of refractory epilepsy. *Epilepsia* 51: 899-908.

17. González HFJ, Yengo-Kahn A, Englot DJ (2019) Vagus Nerve Stimulation for the Treatment of Epilepsy. *Neurosurg Clin N Am* 30: 219-30.
18. Xu SG, Xu L, Cao X, Jiao Y (2010) Cervical perivascular sympathectomy for the treatment of athetoid cerebral palsy. *Chin J Orthopa Trauma* 23: 291-3.
19. Lee RH, Couto E Silva A, Lerner FM, Wilkins CS, Valido SE, et al. (2017) Interruption of perivascular sympathetic nerves of cerebral arteries offers neuroprotection against ischemia. *Am J Physiol Heart Circ Physiol* 312. H182-H188.
20. Edith H (2006) Perivascular nerves and the regulation of cerebrovascular tone. *J Appl Physiol* 100: 1059-64.
21. Soleman J, Stein M, Knorr C, Datta AN, Constantini S, et al. (2018) Improved quality of life and cognition after early vagal nerve stimulator implantation in children. *Epilepsy Behav* 88: 139-45.

Submit your next manuscript to Annex Publishers and benefit from:

- ▶ Easy online submission process
- ▶ Rapid peer review process
- ▶ Online article availability soon after acceptance for Publication
- ▶ Open access: articles available free online
- ▶ More accessibility of the articles to the readers/researchers within the field
- ▶ Better discount on subsequent article submission

Submit your manuscript at
<http://www.annexpublishers.com/paper-submission.php>