

# Numerous Extra-Articular Rheumatoid Synovitis Cyst Formations in Ipsilateral Forearm and Hand - A Case Report

Feng Yao<sup>1</sup>, Qiao Xu Bai<sup>2</sup>, Jiang Jun<sup>1</sup> and Jike Lu<sup>1\*</sup>

<sup>1</sup>Departments of Orthopaedics Surgery, Beijing United Family Hospital, No 2 Jiangtai Road, Chaoyang District, Beijing, 10016, China

<sup>2</sup>Departments of Pathology, Beijing United Family Hospital, No 2 Jiangtai Road, Chaoyang District, Beijing, 10016, China

\***Corresponding Author:** Dr Jike Lu, Department of Orthopedic Surgery, Beijing United Family Hospital, Beijing China, Tel.: 13911095602, E-mail: jike.lu@ufh.com.cn

**Citation:** Feng Yao, Qiao Xu Bai, Jiang Jun, Jike Lu et al. (2024) Numerous Extra-Articular Rheumatoid Synovitis Cyst Formations in Ipsilateral Forearm and Hand - A Case Report, J Surg Oper Care 9(1): 103

**Received Date:** October 27, 2024 **Accepted Date:** November 27, 2024 **Published Date:** November 30, 2024

## Abstract

Synovial cysts are well known in rheumatoid arthritis (RA), and most common around joints. Multiple extra-articular synovial cysts in the patients who has no rheumatoid joint arthritis involvement are rare. Early diagnosis is crucial for managements of the patients.

A case of a 59-year-old lady without any special clinical histories of RA noticed a tennis ball size lump at the right distal volar side forearm and center of the palmar hand respectively a year ago which was fluctuated on palpation and gradually increasing size even after aspiration and cortisone steroid injection. There was no pain, no redness, no joint pain or tender and no restriction of the range of movements of the wrist and hand joints but distention feelings, and sometimes tingling in hand and fingers on medial nerve dermatome distribution. MRI study showed multiple cystic lesions around flexor tendons in distal forearm through carpal tunnel to center of the palmar hand with significantly synovitis around flexor tendons. However there was no wrist and hand finger joints synovitis or pannus formation. Initial diagnosis was multiple extra-articular synovial cysts formation in right forearm and hand. The patient had done aspiration plus injection of betamethasone. The lumps were returned to the original size 2 week's post injection, then surgical excision of cysts and synovectomies were performed under general anesthesia. In this case, it is difficult for the diagnosis of rheumatoid synovitis because of no relevant histories of the joints RA. MRI examinations showed the characteristics of wide-spread synovitis around flexor tendons and multi-lobulated cysts formations which might be helpful for the diagnosis and differentiate diagnosis.

**Keywords:** Forearm; Hand; Magnetic Resonance Imaging; Multiple Extra-Articular Synovial Cysts; Rheumatoid Arthritis; Excision

## Introduction

Synovial cysts can originate from not only joints but also bursa and tendon sheaths [1], so synovial cysts can be multiple and intra- or extra-articularly. However, multiple extra-articular synovial cysts [2, 3] are rarely reported in a patient who has no history of rheumatoid arthritis (RA), and simultaneously involved ipsilateral forearm and hand. Sometimes, they may be confused to differential diagnosis between synovial cysts and soft tissue masses if without imaging modality studies. Some imaging techniques such as X-ray, computed tomography (CT), and magnetic resonance imaging (MRI) have great potentials to detect joint diseases including RA. MRI study is not only differentiate cysts from soft tissue masses but also detect fluid collection and proliferated synovial tissues as high signal on T2-weighted image. At the same time, MRI can detect bone erosion and bone edema. We report a case of an adult with no RA presentation clinically and radiologically but synovium cysts formation over distal forearm and ipsilateral hand.

## Case Presentation

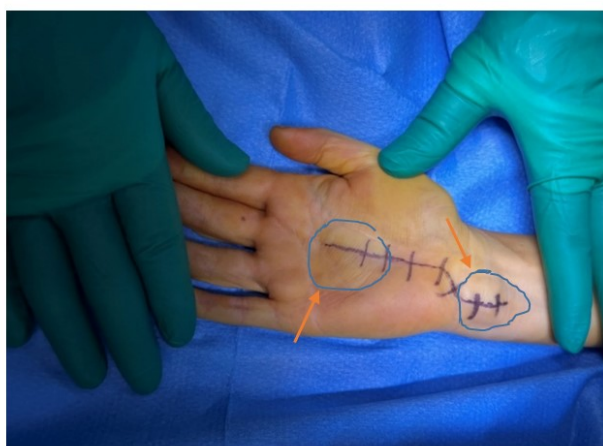A 59-year-old lady without any clinical and family histories of RA and found a tennis size lump in distal forearm and ipsilateral hand a year ago. No pain, no mobility was affected but some tingling numbness in hand and fingers. The lesions were gradually increasing, without redness and swelling, but with slightly pain mainly distension feelings. At the same time, a tennis ball size lump was found both at ipsilateral ulnar side distal forearm and palmar hand.

Physical examination showed tennis ball size lumps over palmar hand and ulnar side of distal forearm (Figure 1). There are no swelling deformities in hands, fingers' joints and maintaining full ROM all joints.

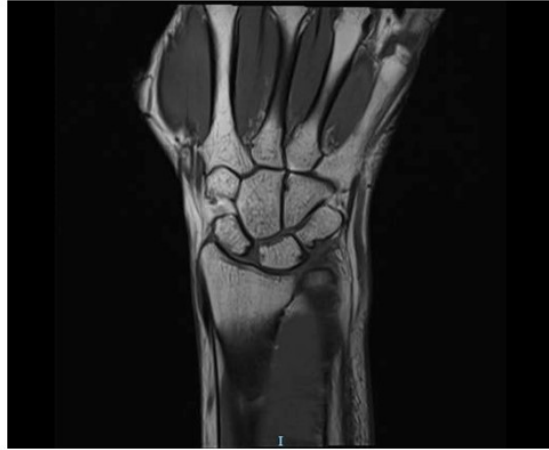Laboratory study showed negative for all sero-negative (normal Uric acid level) and sero-positive inflammatory markers (RF, HLA-B27, ASO etc) and infection markers (WBC, CRP ESR and PCT etc).

MRI study did not reveal any inflammatory arthritis signs on hand and wrist joints (Figure 2) but showed multi lobulated cystic lesions with significant synovitis around flexor tendons and volar ulnar side of the distal forearm cysts which were communicated with palmar hand cysts (Figure 3).

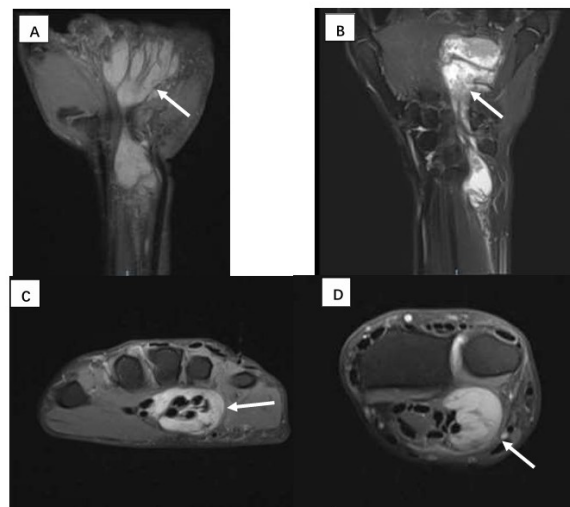
Multi lobulated cystic lesions in palmar hand and ulnar side distal forearm around flexor tendons with significant synovitis (Figure 4).



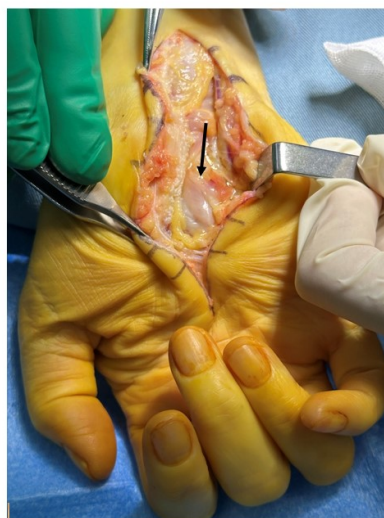**Figure 1:** Surgical incision from ulnar side volar distal forearm crossing carpal tunnel to mid palmar hand, tennis ball size lumps over distal forearm and palmar hand respectively (arrows)



**Figure 2:** There are no synovitis and cartilage erosion of wrist, inter-carpal and carpometacarpal joints (no signs of the RA)



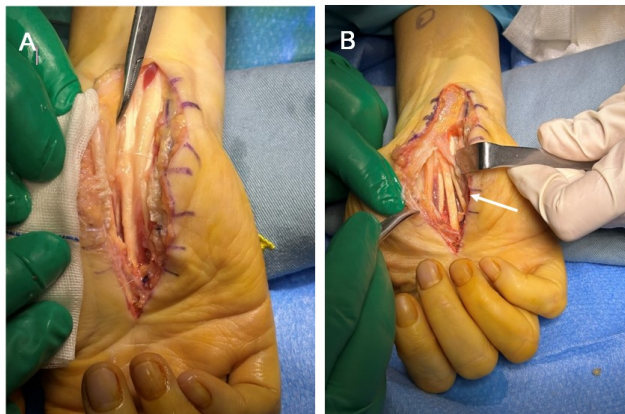
**Figure 3:** MRI showed Multi-lobulated cysts around flexor tendons hand and ulnar side forearm communicated with carpal tunnel (A, C, D). Coronal view of the MRI showed fine villi projections of the synovium tissues (an arrow) indicating RA pannus formation.



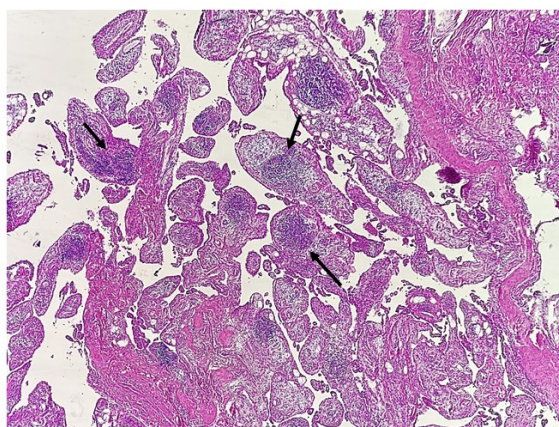
**Figure 4:** Cystic lesions in palmar hand carpal tunnel (an arrow) and ulnar side distal forearm were seen, Guyon's canal was decompressed at the same time.

Surgical incisions cystic lesions and synovectomy were performed under GA. All lesions were excised and synovectomies were performed (Figure 5 A&B) meticulously around flexor tendons and samples send for pathology studies.

Pathology revealed Synovium tissue with papillary architecture, and a prominent lymphocyte infiltration. The lymphocytes are aggregated into nodules and germinal center formation with presence of fibrinoid necrosis. (Figure 6).



**Figure 5:** Median nerve visible after excision of the cysts (A, a tip of a hemostatic forceps indicated) and synovectomies were performed inter-flexor tendons, all lesions were excised completely (an arrow in B), and flexor tendons freed in palmar hand (B).



**Figure 6:** Histology section showed typical RA pathology features, Synovium tissue with papillary architecture, and a prominent lymphoplasmacytic infiltration (arrows). The lymphocytes are aggregated into nodules and germinal center formation with presence of fibrinoid necrosis.

## Discussion

RA is a sero-positive chronic systemic inflammatory disease of the joints, characterized by persistent nonspecific synovitis, and positive autoantibodies particularly rheumatoid factor [4] with progressive process and erosive, with many small joints involved and causing pain and stiffness. RA usually first involves the synovium, resulting in synovial effusion, and synovial proliferation due to chronic inflammation [5]. With increasing of intra-articular pressure, the synovial fluid distends to the articular capsule or weaker areas, and finally forms the synovial cysts [6, 7]. The cysts are usually associated with adjacent capsule, bursa. In our case, the cysts were not associated with any joints in wrist and hand small joints. It is most likely synovitis around the flexor tendons and related to the excessive synovial fluid distending to tendon sheaths.

Rheumatoid arthritis cysts in the hands are one of the common symptoms of the condition. Others include pain, stiffness, swelling, discolored fingers, numbness, tingling, and joint deformity. However in our case, palmar hand cysts formation has no

RA joint symptoms and clinical manifestations, and cysts are multi lobulated from flexor tendon sheaths and communicated with ulnar side distal forearm cysts which are from flexor tendon sheaths as well.

Cystic lesions of RA arising from the distal forearm and palmar hand may present peripheral neuropathy (such as median, and ulnar nerves) due to nerve compression<sup>8</sup>. Our case presented with ulnar nerve irritation prior to surgery. If cystic lesions ruptured, they could present pain and swelling associated with disappearance of sheath effusion, and simulate vascular lesions (such as deep vein thrombosis, aneurysm, fistula, or varix), abscess, or invade other soft tissues [9, 10]. However, absence of typical symptoms of RA such as joint tenderness and morning stiffness, as in our case, is not common. Usually, typical symptoms of RA may be related with the pathological features such as bone erosions. However some cases may have no bone changes such as bone destruction or edema.

It is very difficult to make the accurate diagnosis without relevant RA clinical history and symptoms or deformities. Although some laboratory studies such as ESR and CRP are very important for the evaluation of inflammatory, imaging examination can assess the alterations in synovium, cartilage, and bone as a result of the disease activities. MR will be more sensitive and specific in demonstrating inflammation of joints, bursa, synovium, tendon sheath, and bone marrow. In general, the synovitis is defined as a thickness area with intermediate to low signal on T1-weighted images, but high signal on T2-weighted images. After intravenous administration of contrast agent, the synovitis with abnormal enhancement can be more helpful for the diagnosis from effusion. The contrast enhanced MRI study helps distinguishing fluid from solid masses.

For our case, the diagnosis of RA would be difficult because the patient had no relevant histories, laboratory study did not support RA as well (negative RF) and multi-lobulated cystic lesions involving both forearm and hand are very rare. Autoimmune diseases are those in which the body's immune system attacks its own cells and tissues, and can mimic rheumatoid arthritis. However in our case anti-cyclic peptide, antinuclear antibodies tests are all in normal range. Therefore, there is no evidence autoimmune disease for our case. However, MRI examinations can provide more detailed information for the features of the cystic lesions, such as synovial inflammation, multiple cystic lesions around the flexor tendon sheaths, etc., which is helpful to make a definite diagnosis of RA combining with the confirmations of pathological findings.

In summary, preoperative accurate diagnosis approaches such as clinical presentation, physical examination findings, unique MRI images, and histopathology studies are described in a case of multiple extra-articular synovial cysts in a patient with cystic lesions in the forearm and palmar hand, without the typical signs of rheumatoid arthritis.

## References

1. Lee, Young Keun (2022) Formation of multiple ganglion cysts along the flexor tendon after open A1 pulley release for trigger finger: A case report. *Medicine*, 101: e29663.
2. Zhang JF, Wang JL, Mao XW, et al (2018) Multiple extra-articular synovial cysts accompanied by rheumatoid arthritis in the bilateral elbow joints, A case report. *Medicine*, 97: p e9879.
3. Chen SY, S N, Kashiwazaki S (1998) Multiple extra-articular synovial cyst formation: case report and review of the literature. *Ann Rheum Dis*, 57:169–71.
4. Scott DL, Wolfe F, Huizinga TW (2010) Rheumatoid arthritis. *Lancet*, 376:1094–108.
5. Samata A, Boyd O, Roy S (1988) Unusual presentation of Baker's cyst in a patient with rheumatoid arthritis. *Rheumatology*, 27: 500.

6. Rosewarne DM (1978) Synovial rupture of the knee joint: Confusion with deep vein thrombosis. *Clinical Radiology*, 29:417-420
7. Martin LF, Bensen WG (1987) An unusual synovial cyst in rheumatoid arthritis. *J Rheumatol*, 14:139–41.
8. Muramatsu K, Kojima T, and Yoshida K, et al (2006) Peripheral neuropathies associated with rheumatoid synovial cysts of the elbow joint: three case reports. *J Clin Rheumatol*, 12: 287–90.
9. Dudkiewicz I, Chechik A, Blankstein A, et al (2000) Synovial cyst of the pes anserinus in a patient with rheumatoid arthritis presenting as intermittent claudication. *Isr Med Assoc J*, 2:778–9.
10. Schro H, Opstal CV, Leersnijder JD et al. (1988) Baker's cyst connected to popliteal artery cyst. *Springer-Verlag* 2: 385-9.



Submit your next manuscript to Annex Publishers and benefit from:

- ▶ Easy online submission process
- ▶ Rapid peer review process
- ▶ Online article availability soon after acceptance for Publication
- ▶ Open access: articles available free online
- ▶ More accessibility of the articles to the readers/researchers within the field
- ▶ Better discount on subsequent article submission

Submit your manuscript at

<http://www.annexpublishers.com/paper-submission.php>