

## Epiphyseal Closure of Femur, Tibia and Fibula of the Paca (*Cuniculus Paca*, Linnaeus, 1766)

Lippi ICC, Oliveira RGS, Smargiassi NF, Machado MRF, Sasahara THC, Rocha TASS and Oliveira FS\*

Department of Animal Morphology and Physiology, São Paulo State University (UNESP), Jaboticabal, SP, Brazil

\*Corresponding author: Oliveira FS, Department of Animal Morphology and Physiology, São Paulo State University (UNESP), Via de Acesso Paulo Donato Castelane – 14884-900 - Jaboticabal, SP, Brazil, E-mail: singaretti@fcav.unesp.br

**Citation:** Lippi ICC, Oliveira RGS, Smargiassi NF, Machado MRF, Sasahara THC, et al. (2017) Epiphyseal Closure of Femur, Tibia and Fibula of the Paca (*Cuniculus Paca*, Linnaeus, 1766). *J Vet Sci Ani Husb* 5(4): 403. doi: 10.15744/2348-9790.5.403

**Received Date:** October 29, 2017 **Accepted Date:** December 27, 2017 **Published Date:** December 29, 2017

### Abstract

After capybara, paca (*Cuniculus paca*) is the largest rodent in the neotropical region and the body weight varies from 5 to 10 kg, and may reach up to 14 kg. They are animals that reach sexual maturity at around 10 months of age. The aim of this research is to examine, through radiography, the femur, tibia and fibula of the paca. The animals were anaesthetized for radiographic exams. At 6 months of age, the growth line of the femoral proximal epiphysis ceases to perform its functions. At 12 months of age, there is the closure of the line growth of distal femoral epiphysis. At the paca's tibia, at 12 months old, there was the closure of the growth of the proximal epiphysis. In the distal epiphysis, the closure of the line growth also occurred at 12 months old. At the paca's fibula, the bone activity of proximal epiphysis ceases with only 23 months old. The distal fibular epiphysis ends its development with 15 months. There are similarities and differences relative to the closure of the pacas' epiphysis femur, tibia and fibula comparing with dogs and cats.

**Keywords:** Bones; Rodent; Wild animal; Morphology; Anatomy

### Introduction

After capybara, paca (*Cuniculus paca*) is the largest rodent in the neotropical region [1-3]; the adult males measure from 60 to 80 centimeters, from nose to tip of tail, and the females from 55 to 70 centimeters [1,4]. The body weight varies from 5 to 10 kg, and may reach up to 14 kg [2], but it does not exceed 10 kg [5]. They are animals that reach sexual maturity at around 10 months of age [6].

The moment of the epiphyseal cartilage closing varies according to the bone, some closing already in the uterine life and others remain present for several years [7]. Still, the whole axial correction deviations processes of limbs also depend on the age at which the closing of the growth plate closing occurs. Not only the non-surgical techniques but also the surgical ones for correction of conformations depend on the physiological activity of the growth plate of long bones [8].

Regarding paca, anatomic-radiographic details have already been described. Paca's femur has long axis, round head, and apparent neck; the greater trochanter is well developed, unlike the lesser trochanter and the third trochanter. The tibia and fibula are equal in length and are partially melted by a fibrocartilage at their edges. The tibia cranial border extends to the middle third of the diaphysis and is almost parallel to the largest bone shaft [9].

There are several recent researches on pacas and they involve teeth radiographic anatomy [10] and the axial [9] and appendicular [11] skeletons, heart topographic anatomy [12], dental eruption for age determination [13] and lumbo-sacral epidural anesthesia [14]. Other studies on this species are about the description of the structure, ultrastructure and morphometry of the superior vena cava [15] and morphology and topography of the male genital organs [16]. Still, recent study on miology demonstrates similarities between pacas and dogs [17]. The objective of this work is to determine the age of the epiphyseal closure of femur, tibia and fibula in pacas, an animal that has shown great scientific recent interest.

## Materials and Methods

For this research, were used, 10 male or female pacas, kept in captivity in the Sector of wild animals of the Department of Animal Science of the Faculty of Agrarian and Veterinary Sciences, São Paulo State University, Jaboticabal Campus, after approval of the University Ethical Committee (process 011553/13).

The animals were kept in stalls of approximately 15m<sup>2</sup> of masonry, one burrow per stall, subdivided into three connecting internal sub-sections, remaining in each stall, one male and two or three females with individual marking of microchips, applied dorsally in the cervical region.

In feeding, rodents ration was used (1.0% of body weight per day) and seasonal fruits (10% of body weight per day), offered daily in the afternoon.

The animals were X-rayed (Siemens Tridoros™ 812- E; 50 kVp and 10 mAs) in the sector of Radiology Veterinary at the Governador Laudo Natel Hospital, from UNESP Jaboticabal, monthly from birth up to 24 months old. Radiographic projections of cranio-caudal and lateral side of the femur were performed.

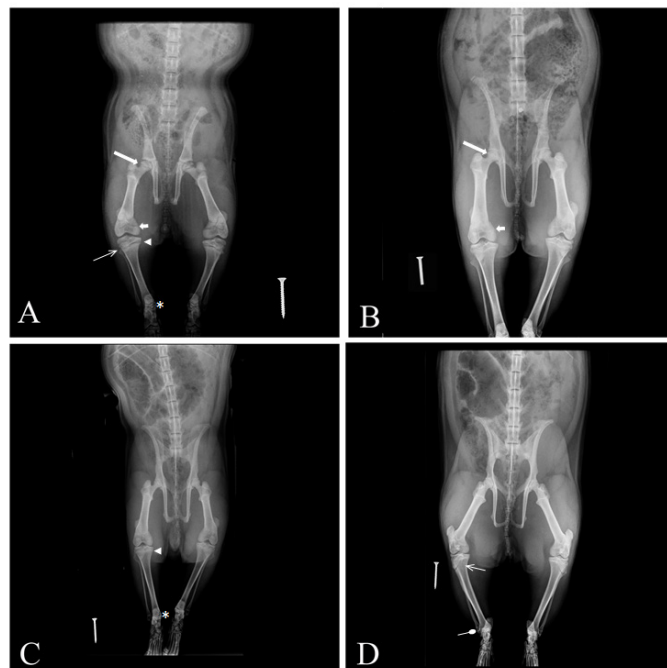
Tranquilization was used with meperidine (2.5mg/kg) and diazepam (0.5 mg/kg) via intra-muscular, in the same syringe. For the anesthesia, 10 minutes after sedation, ketamine hydrochlorides (20 mg/kg) and xylazine (1.5 mg/kg), similarly to the technique already described in the literature for chemical restraint in this species (OLIVEIRA et al., 2003).

## Results and Discussion

The anesthesia used proved to be efficient for transport and the animals radiographic positioning until the Radiology Sector of the Governador Laudo Natel Veterinary Hospital of UNESP - Jaboticabal and there was not any kind of inconvenience caused by the use of the selected drugs, similarly to that described in the literature for these animals through the use of xylazine, meperidine and ketamine [14].

It was observed that radiographically, at 6 months old, the line of femoral proximal epiphysis growth ceases its functions, unlike described for this boneous region in dogs, which perform their functions until 9 months [18,19] or 18 months [20-22]. Unlike also for cats [23], who reported that the proximal femoral epiphysis ends its development between 7 and 10 months.

At 12 months old, the growth line closure of distal femoral epiphysis takes place, unlike described in dogs [20-22], who describe that this region exhibits osseous activity until 18 months, and similarly to that described for this species, which reported line growth closure of distal epiphysis until 12 months [18,19]. Unlike, however for cats, which report that the proximal femoral epiphysis finalizes its development up to 10 months, while the distal, up to 19 months old [23].



**Figure 1:** A. Cranio-caudal image of the pelvic region and proximal femur (arrow), distal femur (short arrow), proximal tibia (arrow head), distal tibia (\*), proximal fibula (line arrow) and distal fibula (rounded tip arrow) of *Cuniculus paca*. (A) one-month animal, with pelvic limb long bones' epiphyses in activity; (B) six-month animal, with no more bone activity in the proximal femur, but some in distal femur, tibia and fibula; (C) twelve-month paca and closure of epiphyses in tibia; (D) Twenty three-month paca and closure of epiphyses in fibula

At the paca's tibia, at 12 months old, there was the growth line closure of the proximal epiphysis, which is different than the one depicted in dogs [20,21], animal whose physical closure occurs around 18 months, and as reported for cats, in which the closure happens between 12 and 18 months [23]. However, our results are similar to 12 months old [22] and from 6 to 15 months old described for dogs [18,19] and from 12 to 18 months described for cats [23].

In the distal tibial epiphysis, the line growth closure also occurred at 12 months old, unlike from 14 to 15 months old [20,21] and from 5 to 11 months described for dogs [18,19]. Our results were similar to those from 12 to 13 months old reported for dogs [22] and from 10 to 13 months old for cats [23] regarding the distal tibial epiphysis.

In the paca's fibula, the proximal epiphysis osseous activity ends with only 23 months old, which is different from 15 to 16 months [20,21] and from 6 to 12 months described for dogs [18] or from 13 to 18 months reported for cats [23]. The fibular distal epiphysis ends its development at 15 months, similarly to what has been described by some authors [20] for dogs, being different from 5 to 13 months described by other authors also in dogs [18,19] and from 5 to 13 months reported in cats [24] (Figure 1). There was no distinction between male and female epiphysial close time.

## Conclusion

There are similarities and differences relative to the closure of the pacas' epiphysis femur, tibia and fibula comparing with dogs and cats.

## Acknowledgment

The authors are grateful for the financial support of Fundação de Amparo à Pesquisa do Estado de São Paulo (FAPESP; 2013/25937-5).

## References

- Mondolfi E (1972) La laca o paca. *Defensa de la Naturaleza* 2: 4-16.
- Matamoros Y (1982) Notas sobre la biología del tepezcuinte, *Cuniculus paca*, brisson, (Rodentia: Dasyproctidae) en cautiverio. *Brenesia* 19: 71-82.
- Silva F (1984) Ordem Rodentia. In *Mamíferos Silvestres do Rio Grande do Sul*. Fundação Zoobotânica do Rio Grande do Sul 171-209.
- Bentti SB, Lapas L (1981) Roedores da América tropical. *Natura* 70: 40-4.
- Deutsch LA, Puglia LRR (1988) Paca In: Os animais silvestres: proteção, doenças e manejo. Globo.
- Fao Food and agriculture organization of the United Nations (1985) La domesticación y cria de la paca (Agouti paca). *Guía FAO Conservación*.
- Stashak TS (2002) Claudicação em eqüinos segundo Adams. *Roca*.
- Luiz RC (2005) Anatomia radiológica da placa de crescimento dos ossos longos em potros crioulos. Master's dissertation (Veterinary Medicine). Federal University of Santa Maria, Brazil.
- Oliveria FS, Canola JC, Machado MRF, Camargo MHB (2007) Descrição anátomo-radiográfica do esqueleto axial da paca (Agouti paca, Linnaeus, 1766). *Acta Scientiae Veterinariae* 34: 331-4.
- Oliveira FS, Canola JC, Oliveira PT, Pécora JD, Capelli A (2006) Anatomoradiographic Description of the Teeth of Pacas Bred in Captivity (Agouti paca, Linnaeus, 1766). *Anatomia Histologia Embryologia* 35: 316-8.
- Oliveira FS, Canola JC, Machado MRF, Camargo MHB (2007) Descrição anátomo-radiográfica do esqueleto apendicular da paca (Agouti paca). *Acta Scientiae Veterinariae* 35: 83-7.
- Ávila BHP, Machado MRF, Oliveira FS (2010) Descrição anátomo-topográfica do coração da paca (Agouti paca). *Acta Scientiae Veterinariae* 38: 191-5.
- Oliveira FS, Canola JC (2007) Erupção dental em pacas (Agouti paca) criadas em cativeiro. *Arquivo Brasileiro de Medicina Veterinária e Zootecnia* 59: 390-4.
- Oliveira FS, Martins LL, Duque JC, Pauloni AP, Valadão CAA (2006) Anestesia epidural em cutias (*Dasyprocta azarae*). *Acta Scientiae Veterinariae* 34: 89-91.
- Garcia SPF, Martins LL, Reis ACG, Pacheco MR, Machado MRF (2013) Estrutura, ultraestrutura e morfometria da veia cava de paca (*Cuniculus paca* Linnaeus 1766) criada em cativeiro. *Pesquisa Veterinária Brasileira* 33: 683-7.
- Borges EM, Branco E, Lima AR, Leal LM, Martins LL, et al. (2013) Morfologia e topografia dos órgãos genitais externos da paca (*Cuniculus Paca* Linnaeus, 1766). *Biotemas* 26: 209-20.
- Leal LM, Sá RM, Oliveira, FS, Sasahara THC, Minto BW, et al. (2015) Miologia do membro pélvico da paca (*Cuniculus paca* Linnaeus, 1766). *Pesquisa Veterinária Brasileira* 35: 21-6.
- Hare WC (1960) The age at which epiphyseal union takes place in the limb bones of the dog. *Wiener Tierärztliche Monatsschrift, Festschrift Schreiber*.
- Sumner-Smith G (1966) Observations on epiphyseal fusion in the canine appendicular skeleton. *Journal of Small Animal Practice* 7: 303-11.
- Bruni AC, Zimmerl U (1951) *Anatomia degli animali domestici*. Casa Editrice Dottor Francesco Valardi.
- Lesbre MF (1897) Contribution a l'etude de l'ossification du squelette des mammiferes domestiques principalement and points de vue de sa marche et de sa chronologie. *Annales de la Société Agricola Scientifique de la Industrie de Lyon* (7th series).
- Ghetie V (1971) *Anatomia animalelor domestice*. Editura Academiei Republici Socialiste Romania.
- Dyce KM, Sack WO, Wensing CJG (2010) *Tratado de anatomia veterinária*, Elsevier, USA.
- Newton CD (1985) Canine epiphyseal plate closures in days. In *Textbook of small animal orthopaedics*. JB Lippincott.

Submit your next manuscript to Annex Publishers and benefit from:

- ▶ Easy online submission process
- ▶ Rapid peer review process
- ▶ Online article availability soon after acceptance for Publication
- ▶ Open access: articles available free online
- ▶ More accessibility of the articles to the readers/researchers within the field
- ▶ Better discount on subsequent article submission

Submit your manuscript at

<http://www.annexpublishers.com/paper-submission.php>